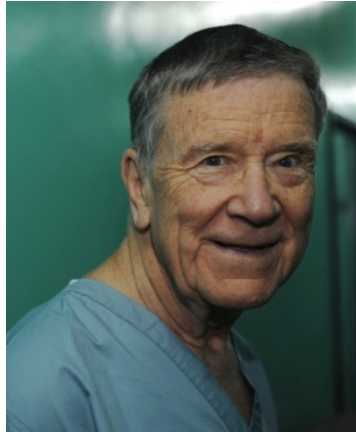


Manual of Obstetric Fistula Surgery

DEDICATION



John Kelly

This manual is dedicated to the memory of John Kelly who was a legend in the fistula world. He started fistula services in many countries in Africa and Asia. He was a most patient teacher and his care for patients was a great example to all of us. Much of the information in this manual, I learnt from him.

Manual of Obstetric Fistula Surgery

Michael Breen
FRCOG Fistula Surgeon
(Freedom From Fistula Foundation)



The publication of this book has been supported by an educational grant from
The Fistula Foundation



Published by
The Global Library of Women's Medicine

Published by:

The Foundation for the Global Library of Women's Medicine

Albyfield

Wetheral

Carlisle

CA4 8ET

UK

ISBN: 978-0-9927545-7-0

Copyright © Michael Breen 2019

All rights reserved. No part of this publications may be reproduced, stored in or introduced into a retrieval system, or transmitted, in any form, or by any means (electronic, mechanical, photocopying or otherwise), except for the purposes of research, private study or review, without the permission of the copyright holder.

Printed and bound by: CPI Anthony Rowe, Chippenham, SN14 6LH, UK

This publication is supported by an educational grant from the Fistula Foundation.

CONTENTS

	Page
Reviewers	viii
Acknowledgements	viii
Illustrations	viii
Preface	ix
CHAPTER 1A. Diagnosing the cause of urinary incontinence	1
CHAPTER 1B. Uro-genital fistulas: causes, classification, early management and factors influencing outcome of repair.	5
1B.1 Causes and classification of genito-urinary fistulas	5
1B.2 Early management of fresh vesico-vaginal fistulas	7
1B.3 Factors influencing the outcome of fistula repair and case selection	8
CHAPTER 1C. Vesico-vaginal fistula: Standard vaginal repair approach	10
CHAPTER 2. Juxta-urethral and large fistulas involving the urethra	35
2.1 Non-circumferential	35
2.2 Circumferential without significant gap	39
2.3 Circumferential with significant gap	40
2.4 Overcoming size discrepancy in large fistulas	44
CHAPTER 3. Special and difficult fistulas	48
3.1 Pinhole VVF	48
3.2 High VVF: vesico-uterine	49
3.3 High VVF: vault	53
3.4 VVF with ureter outside the bladder	55
3.5 Fistulas with bladder stones	57
3.6 Double VVF	58
3.7 Pinhole VVF following previous repair	59
3.8 Around the corner VVF	61
3.9 Fistulas after radiotherapy	63

CHAPTER 4. Urethral re-construction and repair		65
4.1	New urethra made from the anterior vagina during VVF repair	65
4.2	New urethra made from anterior bladder	68
4.3	New urethra from anterior vagina without or following VVF repair	70
4.4	Fistulas anterior/ distal to the urethral orifice	73
4.5	Managing the torn urethra and urethral strictures (non-obstetric trauma)	74
CHAPTER 5. Abdominal repair of uro-genital fistulas		75
5.1	Intra-peritoneal repair of bladder fistula	75
5.2	Reinforcing the repair with an interpositional flap	80
5.3	Extra-peritoneal repair of bladder fistula	82
5.4	Combined vaginal and abdominal approach	84
CHAPTER 6. Post-repair incontinence		85
6.1	Causes and evaluation of post-repair incontinence	85
6.2	Conservative treatment of post-repair incontinence	88
6.3	Surgery: general	89
6.4	Surgery: repair of the pubo-cervical fascia	91
6.5	Surgery: fascial sling and other options	93
6.6	Urethral stricture	97
CHAPTER 7. Recto-vaginal fistulas and sphincter tears		100
7.1A	RVF: trans-vaginal repair	103
7.1B	RVF: trans-perineal repair	108
7.2	RVF: trans-vaginal repair: circumferential defects	109
7.3	RVF: trans-abdominal repair	110
7.4	RVF: trans-abdominal repair: circumferential defects	111
7.5	Anal sphincter tear repair	115
7.6	RVF with anal sphincter tear repair	121

CHAPTER 8. Problems with vaginal closure and flaps in fistula surgery	122
8.1 Flaps to close the vagina during fistula repair	122
8.2 Vaginal stenosis	127
8.3 Martius flap	129
8.4 Gracilis flap	130
CHAPTER 9. Ureteric fistula	134
9.1 Re-implantation of ureter	134
9.2 Double and ectopic ureters and vaginal re-implantation	139
CHAPTER 10. Urinary diversion and bladder augmentation	141
10.1 Mainz 2 pouch	142
10.2 Bladder augmentation	148
CHAPTER 11. Post-operative care and complications	151
11.1 Routine post-operative care	151
11.2 Complications and mortality in fistula surgery	158
APPENDICES	
APPENDIX 1 Equipment	161
APPENDIX 2 Surgical skills for fistula repair	163
APPENDIX 3 Routine protocol for VVF repairs	164
APPENDIX 4 Post-operative charts	166
APPENDIX 5 Nephrostomy and Nephrectomy	169
APPENDIX 6 Advice sheet post bladder augmentation and ileal conduit	172
APPENDIX 7 Operation report sheet	173
APPENDIX 8 Urethral Plugs	174

REVIEWERS

Completing a task such as this is only possible with the help of those who shared their knowledge by reading and making many excellent suggestions:

- *General/ Colo-rectal*: Ian Asimwe, Mhairi Collie, Brian Hancock, Geert Morren and Mike Thompson.
- *Gynecology*: Andrew Browning, Paul Hilton, Rachel Pope and Jeff Wilkinson.
- *Plastics*: Rodger Brown.
- *Urology*: Steven Arrowsmith, Mike Ingber and John Lemberger.
- Former trainees and residents who took time to read and correct the manual at various stages: Paul Ballard, Pauline Borsboom, Chisomo Chalamanda, Mike Ehlert, Tagie G-Mansaray, Rowan Gundry, Ruth Hadebe, Kari Hacker, Debbie Karp, Paolo Parimbelli, Esther Scheers and Julie Solomon.

ACKNOWLEDGEMENTS

To those who I had the privilege of spending time with and who took the time to pass on their knowledge of fistula surgery:

- To Kees Waaldijk who has done much to improve our understanding and knowledge of obstetric trauma and is a great inspiration to the fistula world. One of his mottos is: “Write it down otherwise your knowledge will die with you”.
- To Dr Ambye and Tom Raassen who have shared their skills with many fistula surgeons.
- To the team in Addis Ababa Fistula hospital where many of us did our first fistula cases. Started by Drs Hamlin and now continued by Dr Fekede.
- To the team in Kitovu hospital, Uganda which has been a great centre for sharing knowledge about obstetric fistulas. Started by Dr Maura Lynch and now continued by Dr Florence Nalubega and Dr Nabukalu.

ILLUSTRATIONS

In addition to those acknowledged individually in the manual:

- Most of the original illustrations and cover design were drawn by Luan Serfontein.
- Several illustrations were adapted from “Les Fistules Obstetricales” by Maurice Camey with permission through Charles Rochat.
- Brian Hancock was most generous in allowing me to use several of his photographs.

PREFACE

The aim of this manual is to help those who wish to deal with the many problems associated with obstetric fistulas. It is mainly based on the notes I kept as I learnt fistula surgery. However, as fistula surgery is a practical subject, there is no substitute for hands-on training and experience; this applies particularly for the difficult fistulas. I am grateful to the Fistula Foundation for sponsoring the publication of this manual and to GLOWM for printing it. As the manual will be available on-line (http://www.glowm.com/recommended_textbooks), I would be grateful for any feedback and suggestions to allow the manual to be updated and improved from time to time.

Michael Breen
FRCOG Fistula Surgeon
(Freedom From Fistula Foundation)
E-mail: mpmbreen@gmail.com


CHAPTER 1A


DIAGNOSING THE CAUSE OF URINARY INCONTINENCE


When a patient presents with leakage of urine (especially postpartum), beware of causes other than a fistula. Table 1 summarizes the possible causes of leakage and treatment.

TABLE 1: CAUSES AND TREATMENT OF URINE INCONTINENCE POSTPARTUM		
Type	Diagnosis	Treatment Options
<i>Stress</i>	Urine leaks via urethra with cough or Valsalva and retention of urine is excluded.	<ul style="list-style-type: none"> • Conservative: Pelvic floor exercises • Urethral plugs (if available) in severe cases only • Surgery.
<i>Urgency</i>	History of urinary frequency and nocturia i.e. getting up >2 times per night. Exclude infection and diabetes.	<ul style="list-style-type: none"> • Pelvic floor exercises; reduce caffeine intake • Anti-cholinergics e.g. Oxybutynin 5 to 15 mg/day. • Bladder drills: timed voiding.
<i>Overflow</i>	The bladder is enlarged. The residual urine volume is high. Often wet day and night.	<ul style="list-style-type: none"> • Catheterization: intermittent or continuous drainage • Timed voiding and double voiding. • Alpha blockers to relax bladder neck.
<i>Fistula</i>	If the patient is wet day and night, always consider a fistula, either bladder (vesico-vaginal) or ureteric.	<ul style="list-style-type: none"> • If vesico-vaginal fistula (VVF), catheter treatment only works in small (< 3 cm) and early (< 3 weeks) fistulas. • Surgery for the rest.

TABLE 2: DIAGNOSING THE CAUSE AND SITE OF URINARY INCONTINENCE	
HISTORY: There are four key points which should be evaluated especially when language is a barrier:	
<i>(1) Urine</i>	Ask when she leaks: If she leaks urine day and night, she probably has a fistula. <ul style="list-style-type: none"> • <i>To exclude other causes:</i> If leaking only occurs during the day and she is dry at night, this suggests stress incontinence. • <i>To elicit site of fistula:</i> If she passes urine normally as well as leaking, this suggests a ureteric fistula or a small bladder fistula.
<i>(2) Bowel</i>	<ul style="list-style-type: none"> • Ask about leakage of stool or flatus to exclude a recto-vaginal fistula (RVF). If you do not ask this specifically, the patient may not volunteer the information and it can be easy to miss an RVF or a 4th degree tear on initial examination. • Ask about constipation as frequency and urgency of micturition may be secondary to this, especially in younger patients.
<i>(3) Last menstrual period</i>	<ul style="list-style-type: none"> • Assess the possibility of pregnancy, which is easy to over-look in these patients, as amenorrhea may be present for other reasons. • Operating during pregnancy should be avoided because of increased vascularity and risk of miscarriage.
<i>(4) Surgery+ Past history</i>	If leaking started soon after childbirth or surgery, then it is more likely to be due to a fistula. <ul style="list-style-type: none"> • Ask about any previous operations including attempts at repair. • Ask about the delivery. If the baby is alive, this suggests either: <ul style="list-style-type: none"> ○ an iatrogenic fistula involving the bladder or the ureters if she had a CS ○ stress incontinence if she delivered vaginally.
EXAMINATION	
<ul style="list-style-type: none"> • General: Assess temperature, nutritional status and Haemoglobin. Poor nutritional status means that any surgery should be postponed, in some cases for many months. • Abdominal: Examine especially for an enlarged uterus or bladder. Check for splenomegaly as often associated with a low platelet count and potential bleeding problems during surgery. • Pelvic: The order of pelvic examination is shown in the following flow chart. Examination is performed with the aid of a Sims speculum as in Fig. 1.1 b and c. • Legs: Look for the presence of a foot drop as the patient walks in. If present, encourage to walk with a stick or a walking frame. 	

 **Tip!** If a probe or Foley catheter fails to pass through the urethra, this usually indicates that there is a stricture due to a circumferential juxta-urethral VVF.

 **Tip!** Even if you see urine coming through the urethra, the patient may also have a small fistula.

 **Rule of thumb!** Urine incontinence after vaginal delivery + Baby still alive = stress incontinence.

<p>Inspection Is she wet? Look for any excoriation of the skin.</p> <p>Is urine coming from urethra or vagina? Ask her to cough to look for stress incontinence.</p>	<p>Palpation Feel for an obvious fistula or full bladder on pelvic exam. If bladder full, ask her to empty and then measure residual urine.</p>	<p>Speculum Look for defect and pass probe through it. If no obvious fistula, do a dye test.</p>	<p>Catheterize Check for any stricture. Do a dye test up to 180 ml to look for VVF. If dye test negative, look carefully for any urine in vagina = ? ureteric fistula.</p>	<p>After removing catheter Look for any leakage from urethra and vagina. If not, get her to cough. May do a void test and measure residual volume.</p>
---	--	---	---	---

To diagnose a VVF: First feel on vaginal examination. Then confirm this by seeing it with the aid of a speculum and if necessary by doing a dye test. The lithotomy position is one way to examine the patient although it is easy to miss distal fistulas near the urethral meatus. Sims position with the patient lying on her side is a better way to look for a fistula as it gives a good view of the anterior vaginal wall. Note that the patient's right leg does not have to be held up although an assistant retracting the upper buttock improves the view as in Fig. 1.1 b and c.



Fig.1.1a: Sims position

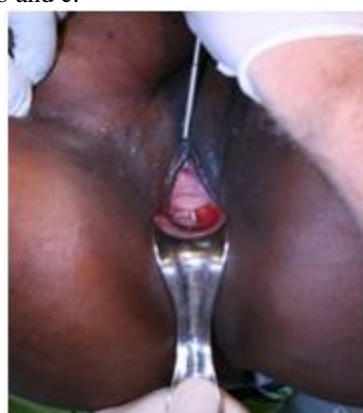

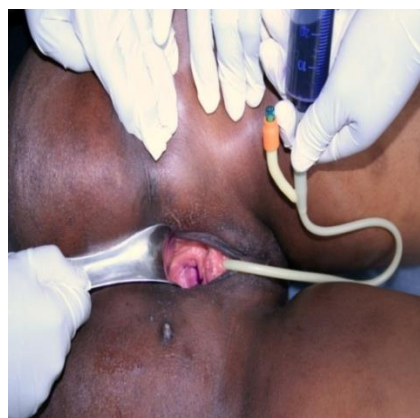
Fig. 1.1b: Shows a metal catheter being passed through the fistula.

You are looking for:

- Any defect, scarring or granulation tissue in the anterior vaginal wall from the cervix to the urethral opening.
- Get the patient to cough and look for a spurt (jet, squirt) of urine coming through a small defect.
- You need to confirm the presence of a defect by passing a small dilator via the urethra and then out through the fistula (Fig. 1.1b). Alternatively, just do a dye test without probing.
- Note the site, size and scarring around any fistula found.

To do a dye test: If a vesico-vaginal fistula (VVF) is not obvious, diluted methylene blue or gentian violet is placed in the bladder via a Foley catheter. With a very small fistula, it may be necessary to insert up to 180 ml. A swab should be held over the urethral opening to prevent any leakage around the catheter. After instilling dye, ask the patient to cough or perform a Valsalva manoeuvre.

Fig. 1.1c: Shows a dye test being performed. The dye is just visible in the vagina. Note that an assistant is retracting the upper buttock.



If positive dye test

- If dye is seen in the vagina, this indicates a VVF.
- If a vesico-uterine fistula is suspected (post-Caesarean section), it helps to pass a dilator into the cervix which allows the dye to come out faster through the cervix.

If negative dye test


There are two main possibilities:

- (a) She may have a very small VVF or a vesico-uterine fistula with the dye taking several minutes to flow into the vagina.
- (b) She may have a ureteric fistula. Look for clear urine in the vagina. In either case, it is worth doing a swab test.

! Top tip! Swab Test: Put 2-3 dry swabs (gauze or cotton wool) in the vagina. After injecting 180 ml of dye into the bladder, remove the catheter and get the patient to walk around for 30 minutes. Then remove the swab:

- If the swabs are wet but not stained with dye, this suggests a ureteric leak either post-surgery or congenital ectopic ureter.
- If the inner swab is stained with dye = VVF but repeat the dye test in theatre.
- If only the outer swab is stained with dye = ? stress

Double Dye Test: This can be used to confirm a ureteric fistula. It can only be performed by administering phenazopyridine taken three hours before examination which turns the urine in the kidneys and ureters orange. With ureteric fistulas, there will be orange fluid in the vagina. A positive phenazopyridine test result with a negative blue test result strongly suggests a ureteric fistula. An alternative dye is to give Indigo carmine IV.

	Pain is an unusual symptom in VVF patients so if present exclude the presence of a bladder stone or tumour. If there is purulent urine, this also indicates the presence of a stone, tumour or a retained swab in the bladder from a previously attempted repair.
---	---

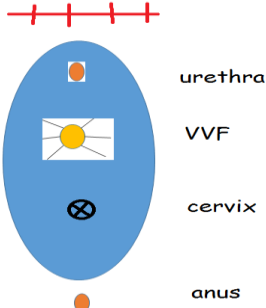
DIAGNOSIS OF URETERIC FISTULA (see also chapter 9)

- Ask your patients to drink 1 liter of water just before you examine them. You can organize your waiting area as a drinking area. This makes the examination much easier so that you can often diagnose a ureteric fistula at the first examination as you should see clear urine in the vagina with a negative dye test.
- It is common that a wrong diagnosis of vaginal discharge is made especially if she is not well hydrated.
- The patient will often give a history of pain in the renal angle before the urine starts leaking. Ask about this.

Rules of thumb: (a) In a patient with clear urine in the vagina + negative dye test = ureteric fistula. (b) Negative dye test + scar on the abdomen = ureteric fistula. (c) If a patient with urinary incontinence is also febrile, exclude a ureteric fistula. Fever is uncommon with bladder fistulas.

If congenital ectopic ureter is suspected: This is usually diagnosed in a child or adolescent although may be an adult. It is worth doing an examination under anaesthesia. In addition to doing a dye test, give fluids and frusemide intravenously. As the amount of urine coming through the ectopic ureter may be small, you have to examine the whole vagina carefully over 30 minutes to see the spurt/ jet of urine. If you see a jet/ spurt of urine, try to pass a ureteric catheter up the track to see if urine flows through the catheter. This will help localize the side especially if the opening is in the midline. If the opening is to one side, then that is the affected side.

- Ideally, an intravenous pyelogram is performed as other abnormalities may be present as well.
- If the child is very young, surgery can be delayed until later as there is not usually any obstruction.
- Diagnosis of ureteric fistula + no previous surgery = think of ectopic ureter irrespective of the age of the patient.


BRIEF HISTORY, EXAMINATION AND INVESTIGATION IN A FISTULA CASE	
	<ul style="list-style-type: none"> • Previous repairs or any surgery? • Urethra: Length/stenosis; Is she wet at night or only during the day? • VVF: Site/ Size/ Scarring / Single or multiple/ Stones excluded/ Vaginal length • Last menstrual period: exclude pregnancy • RVF: does she leak stool or flatus? <p>Ultrasound of the kidneys is useful in all cases but especially to help diagnose a hydroureter and hydronephrosis which will help localize the side of a ureteric fistula.</p>

POSTPARTUM STRESS INCONTINENCE


- This is a relatively common problem due to weakness of the pubo-cervical fascia and the pubo-urethral ligaments so that it can no longer support the posterior urethra. Stretching and attenuation of the fascia may occur during pregnancy or childbirth. There is either a midline defect of the fascia or the whole fascia is overstretched. Separation of the pubic symphysis is a factor in some cases. Up to 30% of women will develop transient incontinence for up to 6 months after delivery and most patients improve with time.
- The normal (mobile) urethra requires a non-mobile fascia and vagina to close against. If the fascia and vagina become too mobile (i.e. it is an early form of cystocele), then the urethra does not function properly. This results in urethral hyper-mobility.
- While there has never been a randomized controlled trial to show that pelvic floor exercises are effective, the woman may feel better subjectively. If, by contracting the pelvic muscles prior to and during a cough, a woman is able to decrease her leakage, then simply learning to use pelvic muscles may be an effective therapy for her.
- Another option is to place a Foley catheter for 4 weeks. Since the endopelvic fascia is defective or overstretched, by keeping the bladder empty this will contribute to better healing of the endopelvic fascia.
 - (a) *If she leaks only on coughing or straining*, it is worth trying conservative steps for 6-9 months. If the problem persists, then surgery may be considered. The options are:
 - Fascial plication: The defect is usually due to overstretching of the endopelvic fascia or a midline defect in it. Usually, a midline plication of the fascia works well and is a low complication

procedure (see section 6.3 for technique). There is not usually any anterior defects so the fascia does not need to be re-attached to the pubic bone but always check that the fixation is intact.

- Synthetic sling: Success rates long term are 90%. Mesh is designed so that the mobile urethra can descend and close against the sling so it should work well in this condition.
 - Autologous fascia sling.
- (b) *If she is leaking all the time*, not just with a cough or strain, then it is unlikely to fully resolve. In these cases, surgery can be performed earlier if the problem persists more than 12 weeks post-partum. This partially depends on how far the patient lives and whether she is likely to come back for review.

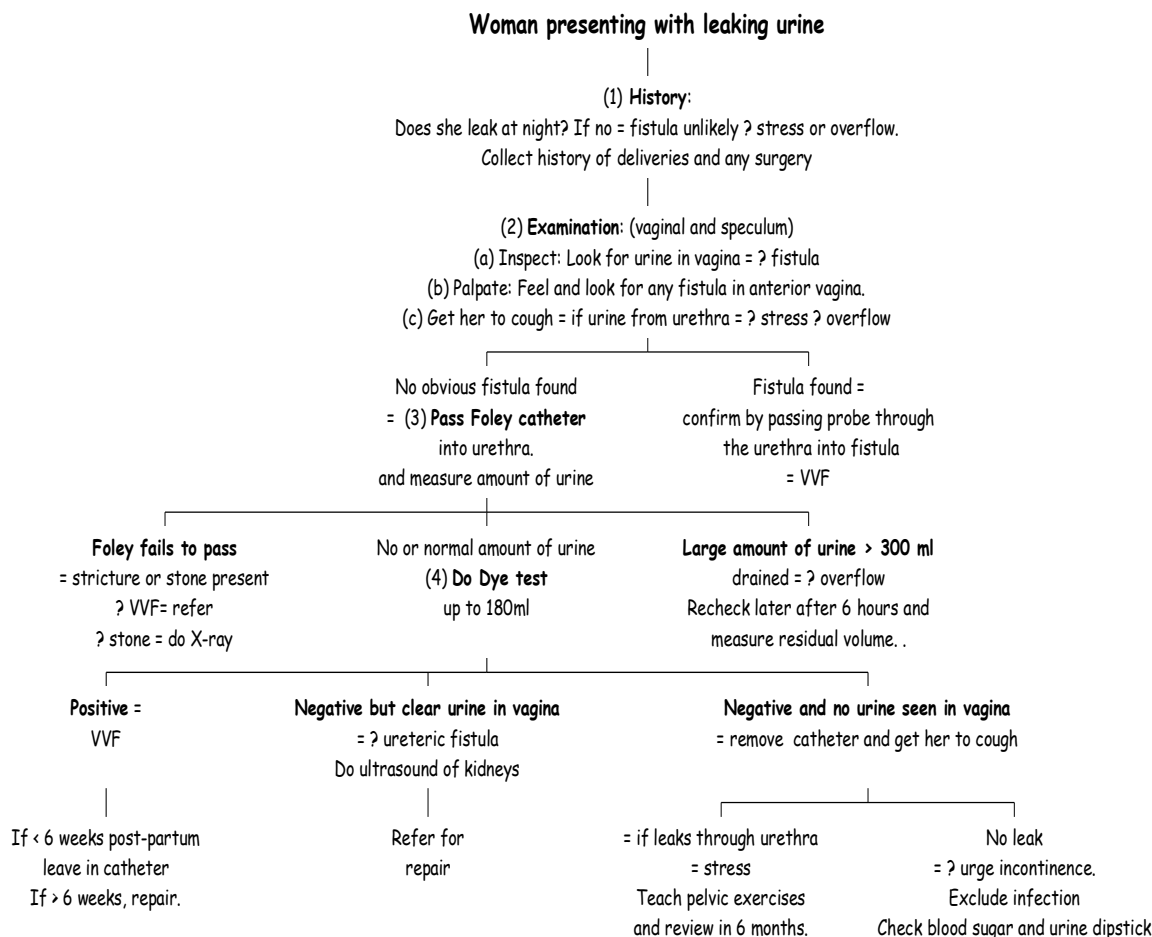
	Having a catheter in even for a short time may compromise sphincter function; stress incontinence is very common immediately on catheter removal, but sometimes resolves a minute or two later, as normal closure function returns.
---	---

OVERFLOW INCONTINENCE (atonic bladder): This occurs after a prolonged labour with overstretching of the bladder muscle. In labour, the fetal head compresses the urethra resulting in a full bladder. The patient often presents with leaking of urine rather than retention or incomplete emptying. Palpate and scan for a full bladder. On ultrasound, the bladder size is > 15 cm and the bladder pressures stay low despite high volume filling so the upper urinary tract stays normal. The initial treatment is to leave a catheter in for 4 weeks. If the problem persists, either continue with an indwelling catheter for another 4 weeks or teach the patient intermittent catheterization. See chapter 11.

	With overflow incontinence, because urine comes through the urethra when the patient coughs, it is often misdiagnosed as stress incontinence although usually the patient is wet in the bed as well as with standing. The diagnosis is made by measuring the residual urine after voiding. Most healthy young women should have a residual urine volume under 100 mls. Alternatively, if the residual volume is more than 50% of the volume of urine passed, it is high.
---	--

Patients with spina bifida often present to fistula camps with urinary incontinence. In spina bifida, the bladder neck can be either: (a) Closed: resulting in high pressure and overflow incontinence. The treatment is intermittent catheterization (b) Open: resulting in stress incontinence. These cases may be suitable for a sling procedure.

Enuresis in young adults: Exclude secondary causes e.g. diabetes, infection, constipation. Advise setting an alarm after 2-3 hours of sleep to empty bladder. Also, reduce fluid and caffeine intake in the evening. Bed wetting alarms are now an option (30\$). Drugs: Imipramine 50 mg nocte; Anti-cholinergic oxybutynin 5 mg nocte.



CHAPTER 1B

URO-GENITAL FISTULAS: CAUSES, CLASSIFICATION, EARLY MANAGEMENT AND FACTORS INFLUENCING OUTCOME OF REPAIR

Section 1B.1: Causes, sites, and classification
 Section 1B.2: Early management of fresh VVF
 Section 1B.3: Factors influencing the outcome of repair and case selection

(1B.1) CAUSES, SITES, AND CLASSIFICATION OF URO-GENITAL FISTULAS

CAUSES OF URO-GENITAL FISTULAS

Obstetric	Surgery	Trauma including foreign body
Malignancy	Radiation	Infection

While the leading cause of fistulas in the developing world is still obstructed labour, surgical trauma is increasing as a cause. In one study 26.5% of cases were related to surgery, mainly Caesarean section. *Reference: Obstetric fistula management and predictors of successful closure among women attending a public tertiary hospital in Rwanda: a retrospective review of records; Egziabher et al: BMC Research Notes 2015 8:774*

- (a) **Obstetric trauma:** The majority of fistulas occur as the result of neglected obstructed labour. The size of the fistula is a reflection of the tissue loss, and scarring may be severe. The first delivery is especially at risk accounting for nearly half of all cases.
- (b) **Surgical trauma (iatrogenic):** This has become the second most common cause. Trauma can occur at different sites. Ureteric and vault fistulas are definitely iatrogenic. Others may have a mixed cause.
 - I. **Ureter to vagina:**
 - After Caesarean section or
 - After hysterectomy or a repair of a ruptured uterus.

These are more common on the left than the right. Occasionally they are bilateral. Most patients present with leaking urine and a small minority present with anuria and/ or abdominal distension.
 - II. **Bladder to uterus: (Vesico-uterine/ cervical)**
 - After Caesarean section or
 - Repair of a ruptured uterus.
 - III. **Bladder to vaginal vault:** after hysterectomy for obstetric or gynecological reasons. If a bladder opening is made during surgery, this greatly increases the risk of fistula formation even if the bladder is repaired immediately.
 - IV. **Urethra to vagina:** these are usually the result of symphysiotomy.
- In fistulas post-surgery, significant tissue loss should be uncommon. These fistulas usually develop between the 1st and 21st (peak day 7-10) post-operative days and often present after removal of the catheter. If they involve the bladder, they should be treated initially by continuous bladder drainage with a Foley catheter provided most of the urine drains through the catheter rather than into the vagina.
- In a series of 805 iatrogenic uro-genital fistulas, 273 (33.9 %) were ureteric, 181 (22.5 %) were vault (bladder to vaginal vault), and 351 (43.6 %) were vesico-uterine/ cervical. *Reference: Iatrogenic genitourinary fistula: an 18-year retrospective review of 805 injuries Thomas J. I. P. Raassen & Carrie J. Ngongo & Marietta M. Mahendeka: Int Urogynecol J. 2014; 25(12): 1699–1706.*
- High obstetric fistulas (defined as a ureteric, vesico-uterine, vesico-cervical, vaginal vault or juxta-cervical fistula) are associated with Caesarean deliveries and shorter duration of labor suggesting that iatrogenic injury rather than pressure necrosis has a causative role. High fistulas are less likely to result in long-term incontinence as compared to low fistulas (defined as a circumferential, mid-vaginal, bladder neck, or urethra-vaginal fistula) probably because high fistulas do not involve the urethral closing mechanism and there is less tissue loss. *Reference: Associations between obstetric fistula location and mode of delivery and post-repair incontinence. Harfouche M, Wilkinson J, Hosseinipour M, Kaliti SM. IJOG vol. 119, s837 2012.*
- (c) **General trauma:** Pelvic fractures; falls from heights.
- (d) **Sexual trauma:** Forced coitus especially before menarche; when an object is forced into the vagina; fistulas caused by female genital mutilation and Gashiri cutting.
- (e) **Pelvic malignancy:** Carcinoma of cervix (Stage 4a), vagina, and rectum are the most common malignancies to present in this way.
- (f) **Radiation:** Fistulas may follow treatment by pelvic or vaginal irradiation. Biopsy should be performed to rule out recurrent malignancy before attempting a repair.
- (g) **Infections:** Schistosomiasis has been reported as a cause of VVF (see below).

SITES OF URINARY FISTULAS

Fig. 1.2 a+b demonstrate the common sites of fistulas, both iatrogenic and those from obstructed labour. Ureteric fistulas are not shown.

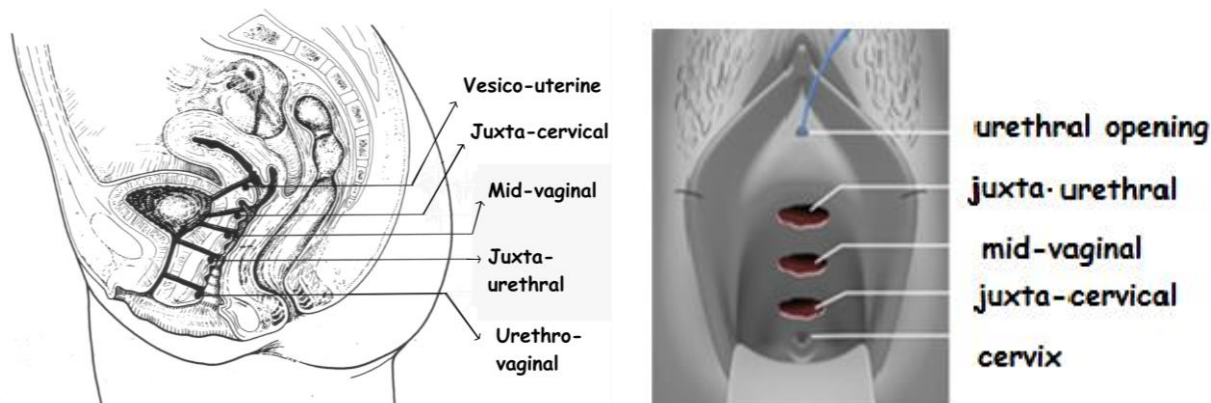


Figure 1.2a+b: Demonstrate the common sites for fistulas. Large fistulas may involve a number of sites. In addition, fistulas (both bladder and ureteric) may occur at the vaginal vault post-hysterectomy.

Fig. 1.2a: adapted from *Surgery for female urinary incontinence*; Editors: Stanton S, Tanagho E; Springer Berlin (1987). Chapter 14: the Management of Vesico-vaginal and Urethral Fistulae; Lawson JB+ Hudson CN.

CLASSIFICATION OF URO-GENITAL FISTULAS

There are two common systems in use. Both of these are based on descriptions of the size and anatomic location of the defect. Both of these were produced for obstetric fistulas, and neither has been shown to be of value in iatrogenic fistulae where the vast majority are type 1. (It is worth noting that if a fistula is type 1, it does not mean it is iatrogenic as obstetric causes may also lead to Type 1 fistulas.). Both classifications try to be objective whereas a simple grading system based on complexity will vary immensely between surgeons.

(1) Waaldijk classification:

Type I:	not involving the urethral closing mechanism
Type II:	involving the closing mechanism A: not involving (sub) total urethra a: without circumferential defect b: with circumferential defect B: involving (sub)total urethra (Urethral length < 1.5 cm) a: without circumferential defect b: with circumferential defect
Type III:	miscellaneous, e.g. ureteric fistula
Subclassification:	Size: small < 2 cm; medium 2-3 cm; large 4-5 cm; extensive > 6 cm

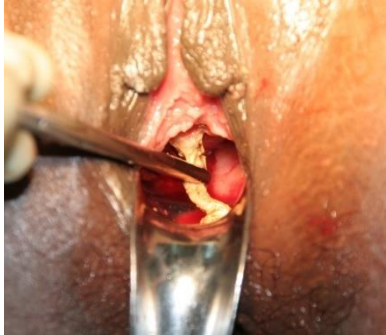(2) Goh Classification: this is really a modified version of the Waaldijk classification. Three main aspects are considered: site, size and scarring.

	<p>Type 1: Distal edge of fistula > 3.5 cm from external urinary meatus.</p> <p>Type 2: Distal edge of fistula > 2.5 -3.5 cm from external urinary meatus.</p> <p>Type 3: Distal edge of fistula 1.5- < 2.5 cm from external urinary meatus.</p> <p>Type 4: Distal edge of fistula < 1.5 cm from external urinary meatus.</p>
<p>size: a: Size < 1.5 cm in the largest diameter b:Size 1.5 – 3 cm in the largest diameter c: Size > 3 cm in the largest diameter</p>	
<p>scarring and other factors</p> <ol style="list-style-type: none"> i. None or only mild fibrosis and / or vaginal length > 6 cm, normal capacity. ii. Moderate or severe fibrosis and/ or reduced vaginal length < 6cm capacity. iii. Special considerations e.g. post-radiation, ureteric involvement, circumferential fistula, previous repair. 	

- It can be argued that as fistulas are so varied, it is difficult to classify them into groups. However, the aim of a classification system is to allow audit of one's results and comparison with those of others.

- It should also predict the risk for unsuccessful closure and likelihood of residual incontinence after successful repair. In this respect, it is clear that they can predict outcome.
- To influence management, and thereby improve outcome is more difficult.
 - They can be used to reduce the risk of stress incontinence as steps can be taken where the fistula involves the urethra as discussed in chapter 1C.
 - To reduce failure rates in high-risk cases: this is discussed below in section 1B:3.

(1B.2) EARLY MANAGEMENT OF FRESH VVF



Do not pull slough off. It is better to cut it off to avoid damaging the surrounding live tissue and increasing the size of the defect.

Assessment: When patients are admitted following obstructed labour with a dead baby:

Examine the patient in the lithotomy position with a good light. The vagina needs to be cleaned with saline douche. Insert a bladder syringe into the vagina and irrigate with 2 litres of saline. Necrotic material is removed with knife or scissors. Do not pull as this causes bleeding indicating you are removing live tissue as well. Antibiotics (broad spectrum) are only useful if the patient is febrile.

Fig. 1.2c: Shows the slough which is about to be cut off using scissors.

CATHETER TREATMENT: If a fistula is detected soon after delivery (i.e. less than 3 weeks and the tissues still look raw) and is small (< 3 cm size), catheterization with a Foley catheter for 2-6 weeks may be all that is required for it to close provided most of the urine drains through the catheter. A period of continuous catheter drainage allows the diversion of urine away from the fistula. This allows spontaneous closure before epithelialization of the fistula tract can occur and this is certainly worth attempting in patients with vesico-vaginal or urethra-vaginal fistulas. It is estimated that 10-15 % of fistulas can be treated this way. Within 1-2 weeks you should know if the catheter treatment is being successful with most of the urine going via the catheter/ urethra. If necessary, the patient can be encouraged to lie prone as much as possible to reduce any leaking. You can then continue catheter drainage for 2-6 weeks after the patient stops leaking, being guided by the dye test.

- In a study from Burundi, only those fistulas < 3 cm and < 3 weeks duration healed with a catheter.
Reference: Tayler-Smith K, Zachariah R, Manzi M, et al. Obstetric fistula in Burundi: a comprehensive approach to managing women with this neglected disease. BMC Pregnancy Childbirth 2013; 13:164.
- With vesico-uterine fistulas after caesarean section, it is also worth trying conservative treatment as the involution of the uterus also encourages the fistula to close.
- Spontaneous closure is more likely to occur where there has been minimal tissue damage and is seen more often with obstetric and surgical fistulae than post-radiation fistulas.



If you decide to insert a catheter, make sure the balloon is inflated in the bladder rather than in the fistula or vagina as often happens. An inflated balloon in the fistula only makes the defect larger. If the balloon prefers to stay in the vagina, remove the catheter. Only inflate the balloon with 5-10 ml of water.

TIMING OF REPAIR:

There are no absolute rules on the timing of repair. The best timing is when there is no inflammation or infection.

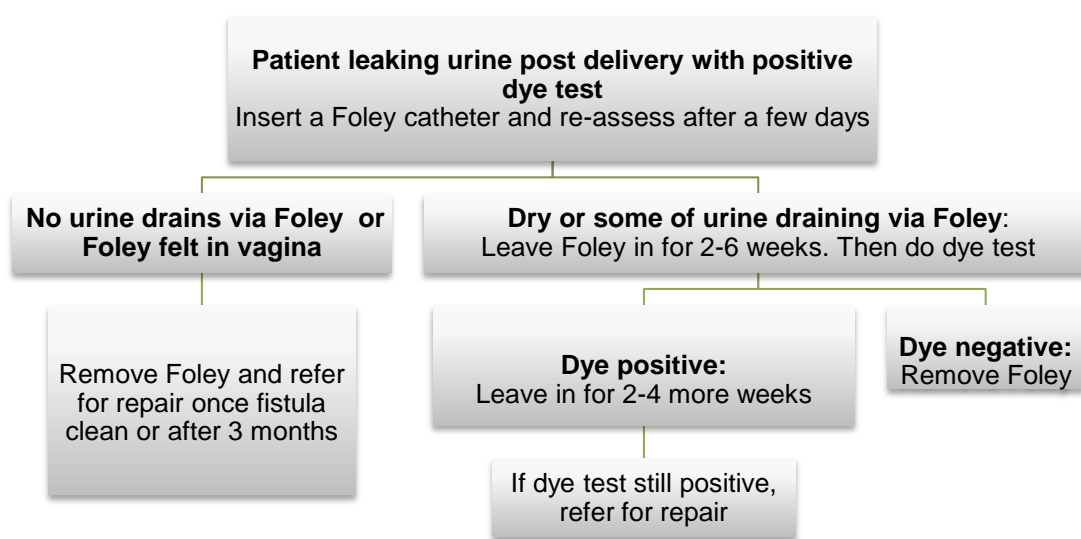
- (A) **Fistulas after prolonged labour:** A general rule would be to wait 8-12 weeks after delivery before attempting repair. This enables the slough to separate and the tissues to become less friable. The earliest a repair can be done is when the tissues look healthy.
- Repairing before 8-12 weeks is only appropriate for experienced surgeons as the tissues may still be friable. There is also an increased risk of bleeding. It can only be done once the fistula is clean which may be as early as 3-4 weeks. Occasionally if there is a small amount of slough, this can be removed at the time of surgery.

- One study recommended that any woman who develops a fistula should have a catheter inserted. Then as soon as the fistula is clean, an early repair should be performed unless the fistula is already healed.
Reference: Waaldijk K The immediate surgical management of fresh obstetric fistulas with catheter and/ or early closure. Int J Gynecol Obstet 1994; 45: 11-16.

(B) Post-surgical fistulas: It is a good idea to wait for the surgical inflammatory reaction to subside.

- If they involve the bladder, waiting at least 6 weeks and preferably 12 weeks will mean the tissues are less friable resulting in an easier operation with a better chance of success. Operating when the tissues are friable means that sutures are more likely to cut through with tearing of the bladder wall.
- The only exception would be if the fistula is diagnosed within 1-2 days after the operation; then immediate repair may be performed either trans-abdominally or trans-vaginally as the inflammation is not yet established. However, for fistulas < 1 cm, it is worth trying conservative management with a catheter first.
- Ureteric fistulas: see chapter 9.

! Tip! Any fistula that is small (< 3 cm), diagnosed early and the leakage stops with a catheter, is likely to heal with conservative treatment. For any fistula, if leakage persists after 4-6 weeks of catheterization, there is no benefit to continuing with catheterization and it only increases the risk of infection.



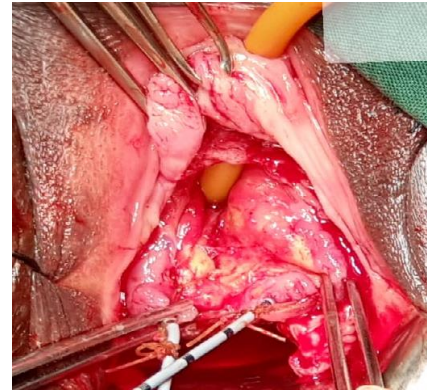
(1B.3) FACTORS INFLUENCING THE OUTCOME OF REPAIR AND CASE SELECTION

FACTORS INFLUENCING THE OUTCOME OF FISTULA REPAIR (12 S's)

These factors determine the accessibility and the quality of the tissues, which are the main prognostic factors for success of the repair. An aid to remember these are the 12 S's:

- **Site:** Fistulas involving the urethra are more likely to break down. In Goh's system, type 4 fistulae are more likely to have failed closure compared to those with type 1 or 2.
- **Size:** If fistula size > 4 cm or multiple fistulas, the prognosis is worse. This is because it affects the residual bladder size and urethra. With large fistulas, the ureters may be outside the bladder.
- **Scarring (fibrosis):** reduces the accessibility and mobility. Also scarred, fibrotic tissue has less blood supply and is less likely to heal.
- **Surgery before:** a simple fistula may become complex after a failed repair. Previous surgery causes more scarring and distorts anatomy. Iatrogenic fistulas usually have a higher success rate after repair as the tissues are usually healthier.
- **Shortness or stenosis of the urethra:** length and patency. Total urethral destruction, circumferential defects (see chapter 2) or involvement of continence mechanism are all poor prognostic factors.
- **Stool:** Combined RVF with the VVF. These are usually more difficult VVFs. See chapter 7.
- **Skill:** of the surgeon and of the fistula team.
- **Sero-status:** In HIV positive patients, failed VVF closure is significantly more common than among their HIV-negative counterparts. *Reference: Shephard, et al (2017), Effect of HIV infection on outcomes after surgical repair of genital fistula. Int J Gynecol Obstet. doi:10.1002/ijgo.12233.*

- **Sugar:** Diabetic patients have an increased risk of breakdown of the repair.
- **Sickness:** Any severe illness post-operatively (e.g. severe sepsis or malaria) often affects the healing of the VVF.
- **Sepsis:** of the operation site often leads to breakdown.
- **Schistosomiasis:** is associated with failed repairs even in cases where the mucosa appears normal. In other cases, the bladder mucosa may have a yellowish colour or a red granular appearance (Fig. 1.2d). In areas endemic for *S.haematobium*, either the urine should be screened for ova or treatment is given empirically. The optimum timing of surgery after treatment is not known. Dead ova may remain in the bladder tissues for months after treatment potentially inciting a persistent inflammatory response.



! Tip! Think of schistosomiasis especially if “an easy repair” breaks down.

Fig. 1.2d: Schistosomiasis during VVF repair (Courtesy I. Vaz).

CASE SELECTION

- One of the most important points to appreciate in fistula surgery is to know which cases to attempt and which not to attempt. Do not be afraid to tell the patient to come back later when an expert is coming.
- Selection is based on the same 12 S’s as above. A midline mid-vaginal fistula which is not scarred and not too big (< 3 cm) and which has not been repaired before would be the ideal one for the novice fistula surgeon to start with. In contrast, a VVF accompanied by an RVF or foot drop would usually indicate a difficult case.
- However, pre-operative case selection is often not accurate especially for what seems like an easy case which may turn out to be difficult because the full extent of the fistula is often only seen once dissection is completed. Therefore all cases should be done under supervision until you have the necessary experience. In the words of Kees Waaldijk: “It looks so easy until the operation has started”.

! Tip! In settings where supervision is hard to get, there is a role for doing an examination under anaesthesia. This allows you to do a proper assessment, document well and make a good plan. You can then decide at that time whether the fistula repair meets your level of competence. If not, the patient is asked to come back later. This step can be helpful to a junior fistula surgeon and allows you to make progress without harming patients in the process.

IMPROVING SUCCESS RATES

- If overall success rates are below 80%, this would indicate a need for more training. Collecting difficult cases and doing them with a more experienced surgeon is a good way of achieving this.
- Even with good training, failures can occur. It is a combination of pre-operative findings and the difficulties encountered during the repair that gives an impression of the likelihood of success.

Pre-operative	Site, Size Scarring, Circumferential defect, Previous repairs
Operative findings	Tissue quality (in addition to any scarring), difficulty achieving a negative dye test, the presence of infected urine.

It is relatively easy to give an objective assessment of difficulty based on the pre-operative findings. However, the operative findings are more subjective. Most experienced surgeons at the end of the operation know which cases are at high risk of breakdown. What can be done in these cases? After closure of the bladder, place an intermediate layer between the bladder and the vagina (see Chapter 1C). Muscle interposition seems to give the best results for the most difficult cases. A good layer of fat (either Martius or omentum) is another option.


FISTULAS IN PREGNANCY

- Fistula repair is usually avoided due to increased bleeding and increased risk of miscarriage. However, some surgeons find that during the first four months of pregnancy there is no increased bleeding and healing may be better. What this means in practice is that simple fistulas may be repaired in early pregnancy by experienced surgeons.
- If there are bladder stones in association with a fistula in pregnancy, these may be removed suprapubically if necessary.

CHAPTER 1C

STANDARD VAGINAL APPROACH FOR VESICO-VAGINAL FISTULA REPAIR

PRE-OPERATIVE PREPARATION AND CHECKLIST FOR VVF REPAIR

A	Antibiotic prophylaxis is important, preferably with aerobic and anaerobic coverage. A stat dose of: <ul style="list-style-type: none"> ➤ A common regime is gentamycin 6 mg/kg or a cephalosporin plus metronidazole 500 mg IV. ➤ Co-amoxiclav (Augmentin) 1.2 gram IV stat is another option. It is better to reserve one antibiotic that is only used for prophylaxis and rarely for treatment.
B	Blood results
	Bowel preparation before VVF repairs to avoid contamination during surgery. The patient should take only clear fluids for the day before surgery. In addition, there are two options: <ul style="list-style-type: none"> • No enemas are given. The patient is asked to try to defecate the morning before surgery. If there is stool coming after anaesthesia, it is easy to deal with because it is solid. Evacuate it manually, pack the rectum and put a purse string around the anus. • Give an enema the day before surgery. Avoid enemas on the day of surgery as they often work during the operation.
C	Consent for procedure and check details of the procedure.
	Catheter: If possible, urinary catheters should not be used for at least a week before repair to help clear the bladder of infection.
D	Drip: It is a good idea to start intravenous fluids at least 1 hour pre-operatively so that the patient is well hydrated which will make it easier to find the ureters during the operation. Good hydration is also useful for spinal anaesthesia which is used in most cases. <p> Top Tip! It is safer to have two intravenous lines running for every fistula repair. This reduces the risk of hypotension. If this is not possible, at least have a second cannula in place to avoid panic if the BP drops.</p>
E	Equipment: Is any special equipment needed for this procedure? Also, check equipment for monitoring.

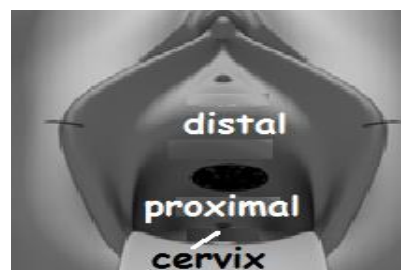
MAIN STEPS OF THE OPERATION


The following steps can be used for the majority of VVFs.

Step 1: Exposure of fistula(s) and ureters, exclude stones, ensure no other fistula is present.
Step 2: Mobilize the bladder and excise scar tissue around the fistula tract i.e. dissect the vagina off the endopelvic fascia and bladder/ urethra.
Step 3: Close the bladder watertight without tension and then do a dye test to confirm closure and then decompress the bladder with a catheter.
Step 4: Consider an intermediate layer.
Step 5: Closure of the vagina and ensure good haemostasis.
Last steps: Pack the vagina and secure the catheters.

The vaginal approach is preferred where possible as it results in lower blood loss, requires simpler anaesthesia, the operative time is shorter and the post-operative recovery is quicker. The indications for an abdominal approach are discussed in chapter 5.

Fig 1.3a: In the following description, the term proximal means the part of the fistula closer to the cervix. The term distal refers to the part of the fistula closer to the urethra.



 **Tip!** Put out the special sutures and catheters that you think you will need before the case so that they are easy to access.

STEP 1: EXPOSURE OF FISTULA AND PROTECTION OF URETERS

In surgery, exposure is everything.


(A) Patient Position: Before scrubbing for surgery, the surgeon must take the time to position the patient properly. It is much easier to do this before, rather than during, the operation. The fistula should be at the

level of the surgeon's eyes (Fig. 1.3b). The exaggerated lithotomy position (Fig. 1.3e) is used and can be achieved by a combination of the following:

- The whole buttocks must be over the edge of the bed with the hips well flexed.
- The patient is placed in a steep Trendelenburg position. This brings the anterior vaginal wall into an oblique rather than a horizontal plane which means it can be seen more comfortably. Shoulder pads are attached to the operating table and placed on the patient's shoulders preventing her from slipping down the table (Fig. 1.3c). These are critical for fistula surgery. However, be careful that there is not too much pressure on the shoulders as this can cause brachial plexus injury. The pads should be just in position to catch the patient if she slips down the table. The head down tilt also has the effect of elevating the end of the bed.

Watch that this position is maintained during the operation or else surgery will become difficult and you may be unaware this is the reason.

 **Tip!** If a fistula is high and difficult, get the buttocks well over the edge and increase the head down.

 **Tip!** If the table has very little head-down tilt or does not elevate sufficiently, try lowering your chair. You may even have to sit on a foot-step so that you are almost on the floor. Alternatively, put 1-2 pillows or a wedge under the patient's buttocks. Another option is to elevate the base of the table with a step or blocks.


 **Tip!** If you have no shoulder pads, you may just elevate the patient's shoulders using a wedge or mattress. This will prevent her from slipping down the bed. Also, get the buttocks well over the end of the bed.

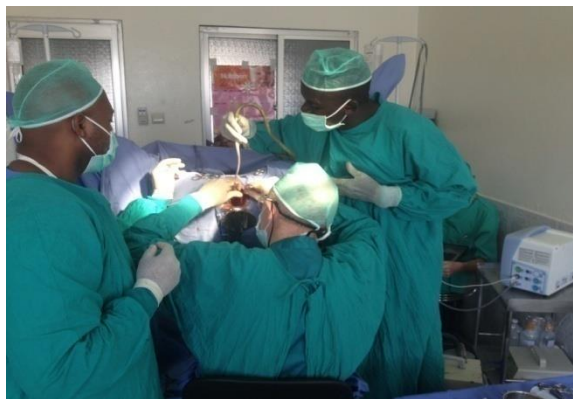

Fig. 1.3b: Shows the fistula at the correct level of the surgeon's eyes.

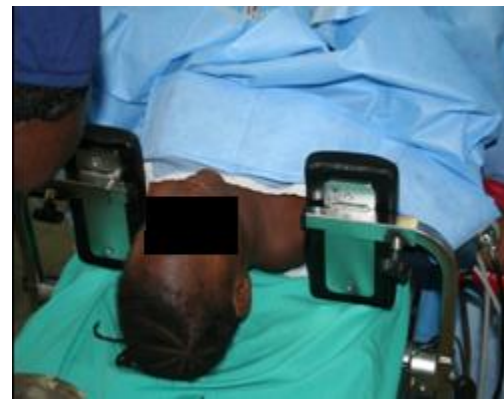


Fig. 1.3c: Shows the shoulder pads in position.

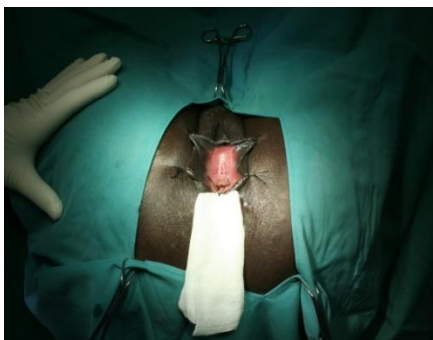

Fig. 1.3d: Shows the labia sutured back and gauze swab in position. A useful trick is to place a continuous suture of 3-4 bites between the vagina and the gauze as this prevents any contamination.

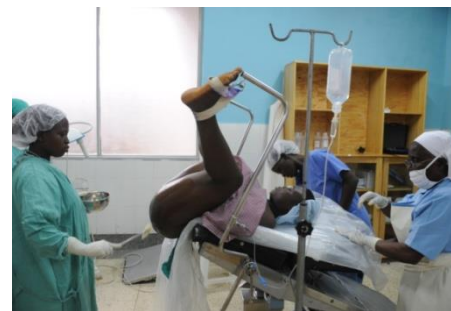

Fig. 1.3e: Shows the exaggerated lithotomy position with the buttocks well over the end of the bed and the hips well flexed and slightly abducted.

 **Tip!** It is a good idea to fix a towel clip over the pubic symphysis in the midline to the skin as seen in Fig. 1.3d. This avoids the drapes slipping down the bed when the patient is put in the Trendelenburg position.

(B) Suturing:

- To improve exposure, stitch the labia minora/ majora back bilaterally (Fig. 1.3d).
- To avoid faecal contamination, put a gauze swab over the anus. If the patient has already soiled or you think she is likely to (stool is seen in rectum), two additional steps are taken before surgery: (i) Pack the rectum with gauze and (ii) Place a purse-string around the anus and place an artery forceps on the

suture end so that you do not forget to remove it at the end of the surgery. The key with this suture is to go deep so that the suture includes the sphincter and not just the skin.

(C) If the vagina is very scarred:

- (a) *Cut scar band:* Often there is a circular ridge of scar on the posterior vagina. This can be cut with a small longitudinal incision on each side at 4-5 o'clock (as shown in Fig. 1.4) and 7-8 o'clock (not shown). If it is incised centrally, the risk of injuring the rectum is high. If necessary, place your finger in the rectum while you make an incision over scar tissue, as the rectum is often closely adherent. After cutting scar tissue, push bluntly with your finger to open up the scarred area.
- (b) *Make an episiotomy:* Most VVFs can be repaired without any episiotomy as episiotomies do not help when the scarring is high up in the vagina. Some surgeons advocate liberal use of episiotomies especially for beginners since good access to the operation field is the first step in any surgery. The episiotomy should be performed at the 5 or 7 o'clock position and not 3 or 9 o'clock position to increase the access.
 - If you have performed a unilateral episiotomy: Any scars in the vagina on the side opposite to the episiotomy can be cut just in the vagina as described.
 - On rare occasions, an episiotomy may have to be performed bilaterally – usually for an RVF repair rather than just a VVF.

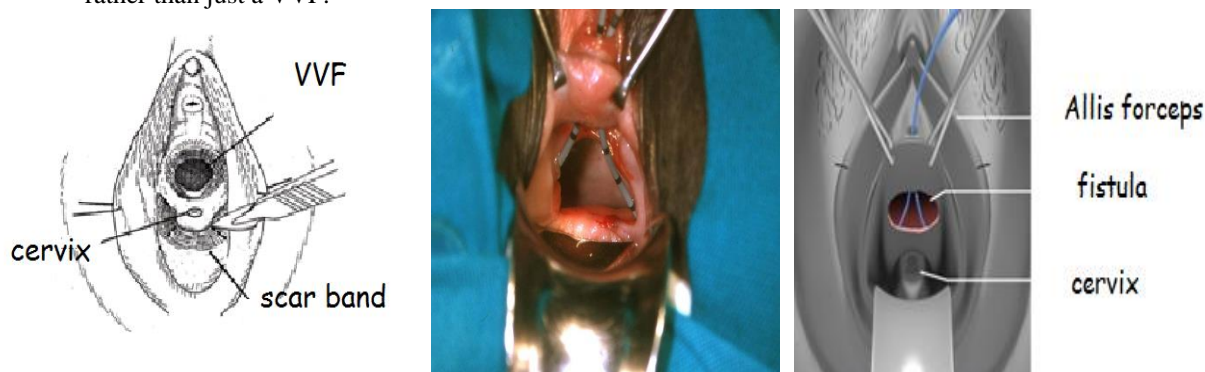

Fig.1.4: Shows the scar band being cut. The scar is represented by the shaded area behind the cervix.

Fig 1.5 a+b: Show the placement of Allis forceps and the speculum to expose the fistula.

! Tip! To expose the scar band, place a retractor on the anterior vaginal wall. Cutting the scar with cautery helps reduce the bleeding. If it still bleeds, it may need suturing later. In absence of diathermy, place a gauze piece soaked in adrenaline 200,000 below the weighted speculum to stop bleeding as you operate.

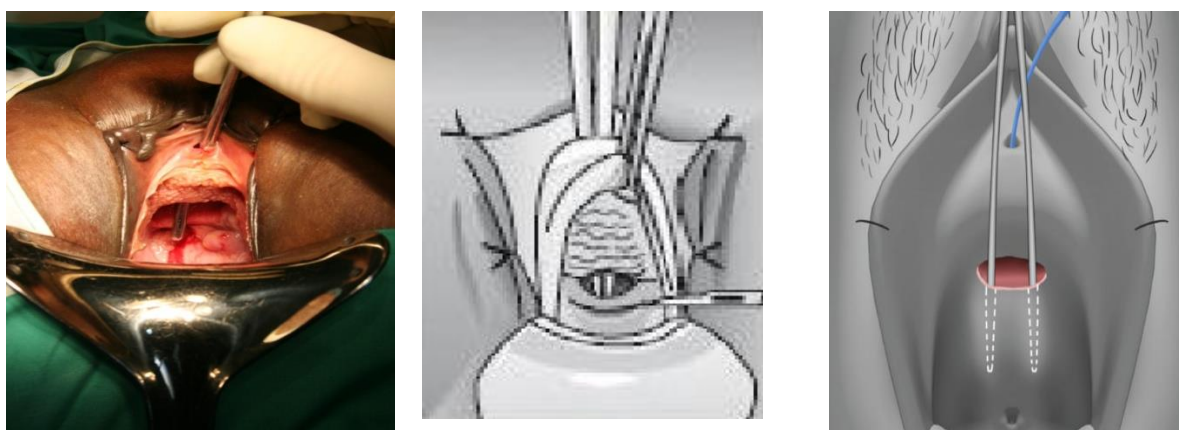


Fig. 1.5c: Shows the metal catheter inserted into the urethra to expose the fistula.

Fig. 1.5d: In this case, an artery forceps (inserted via the urethra) is used to display the edges.

Fig. 1.5e: Shows the vagina being stretched with pickups before making the incision in the vagina.

(D) To expose the fistula:

- (a) Put two Allis forceps distally on the vaginal skin to stretch the opening of the vagina by pulling up and outwards. These are placed on either side just below the urethral opening as in Fig. 1.5a. If the VVF is proximal, the Allis forceps can be placed further into the vagina just distal to the VVF. Alternatively, just put one Allis distal to the fistula to pull it up.
- (b) In most cases, a weighted speculum is used but if the vagina is small or scarred, either use:
 - a small weighted speculum with a short and narrow blade (Aesculap® EL 736R)

- Sims speculum or a small Deaver retractor may be all that can be inserted.



Tip! If a speculum tends to fall out during the operation, either:

- Place a suture across the upper end of the handle of the speculum. Take a bite of the skin on either side of the speculum which will usually be just below the level of the anus.
 - Fix it with part of the drape and a towel clip across the handle.
- (c) Instead of or in addition to using Allis forceps, a metal catheter or even an artery forceps can be used as a retractor in the urethra which helps expose the proximal or distal edges of the fistula (Fig. 1.5 c +d).
- (d) In smaller fistulas, a pickups/ dissecting forceps is a useful way to display the fistula (Fig. 1.5e).

	<p>FIRST CHECKPOINT: BEFORE YOU START OPERATING</p> <p>Insert a metal catheter into the urethra and the bladder to:</p> <ol style="list-style-type: none"> 1. Make sure the urethra is patent and the fistula you see is not just the bladder end of a circumferential defect (see Fig. 2.6). Measure the length of the urethra. If the urethra is blocked, see section 2.3. 2. Feel the inside of the bladder to exclude the presence of any bladder stones (if present, see section 3.5). The presence of pain on pelvic examination or urine that is purulent or has an offensive smell should have alerted you to this pre-operatively. 3. Confirm the site of the fistula and that there is only one fistula. Look for a second fistula proximally (higher up). It is much better to find it before you start operating than waiting for a positive dye test. This will change your whole approach as it is better to start with the proximal fistula. 4. Check for the position of the ureters before making any incisions especially if it is a large fistula. 5. Is the cervix present? If not, remember it may be stuck to the bladder. 6. Measure the length of the bladder from the external urethral meatus to the dome of the bladder. If you subtract the urethral length from this, it will give you the bladder length.
--	--

To measure the length of the urethra:

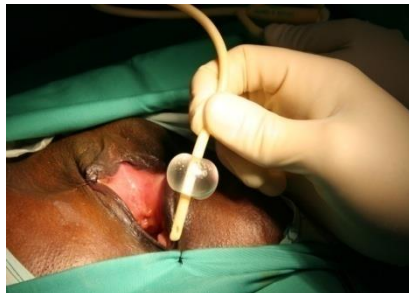
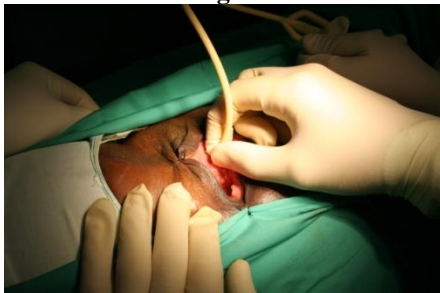
Fig. 1.6 a +b: Measuring urethral length. This is important in assessing the risk of post-repair incontinence (see chapter 6).

- Insert a Foley catheter into the bladder and inflate the balloon with about 3 ml of saline.
- Then pull the catheter back until you feel the resistance of the bladder neck. Then pinch the catheter at the level of the external meatus (Fig. 1.6a).
- Deflate the balloon and withdraw the catheter. Once the catheter is out, re-inflate the balloon with 2-3 ml of fluid and measure the distance from the edge of the balloon to the point pinched off by the operator (Fig. 1.6b). This should be the urethral length.



Tip! If the fistula is very small, pass a probe or uterine sound into the fistula and see if it makes contact with the metal catheter inserted into the bladder via the urethra. This “metal on metal clash or click test” confirms the fistula is into the bladder.


Vaso-constricting agent: This is used routinely to reduce blood loss and improve visibility. Dilution is what makes adrenaline safe to use. Two suggested options for making a solution of adrenaline are to:

- (a) Mix 4 ampoules of 1 ml of adrenaline 1: 1000 in one litre of saline. This gives a concentration of 1: 250,000. You can then use this bag for many cases, drawing up the solution as you need.
- (b) Mix 0.5 ml adrenaline 1: 1000 (measured using a graduated 1ml syringe) to 100 ml saline (measured using the bladder syringe). This gives a concentration of 1: 200,000.

Some add lignocaine to reduce the systemic effects of adrenaline but this is not necessary.

- It takes about 5-7 minutes for adrenaline to start working, 23 minutes to have its maximum effect so you need to inject it early and be patient. It wears off after about 60 minutes.
- If you are doing an episiotomy at 5 or 7 o'clock, infiltrate about 20 ml.

- Infiltrate around the fistula and where you will make the lateral extensions.
- Be sure to aspirate before you inject to avoid injecting into a vessel by mistake. Then only inject as you withdraw the needle.
- It is a good idea to warn the anesthetist and the patient before you inject as she may experience palpitations with tachycardia, headache and elevation of BP. Occasionally the patient gets a compensatory bradycardia in response to the hypertension.
- In the hypertensive patients, it is better to use Normal-Saline without adrenaline for hydro-dissection.

	<p>You have to be very careful with the concentration of adrenaline. A mistake is most likely to happen if someone inexperienced draws it up for you. So always check that it is done correctly.</p>
---	--

LOOKING FOR THE URETERS

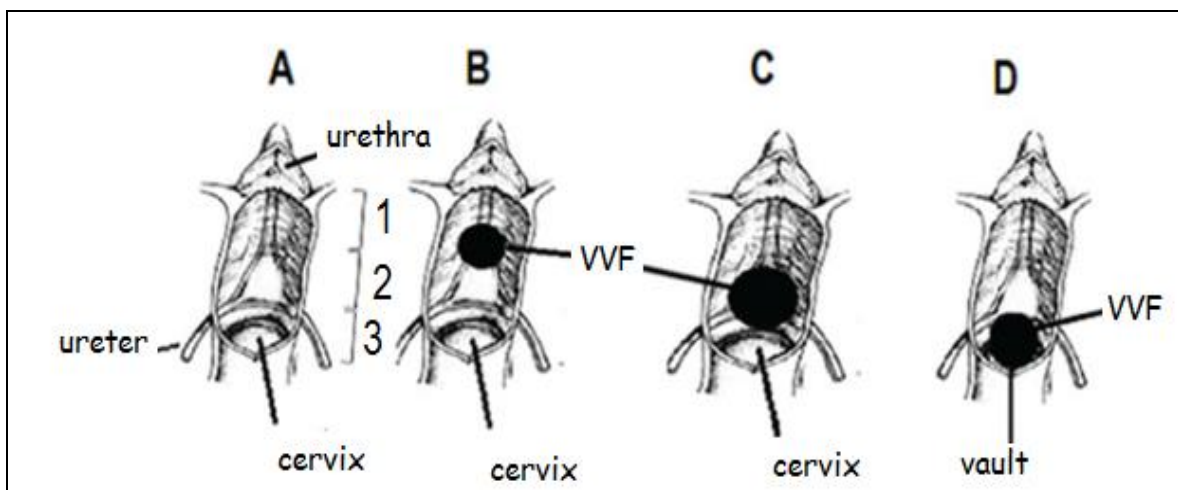


Fig. 1.7a: This shows the anterior wall of the vagina.

(A) This shows the normal anatomy: 1 = distal third of vagina, 2 = middle third, 3 = proximal third.

(B) This shows a mid-vaginal fistula. The ureters are not close to the fistula edges.

(C) This shows a juxta-cervical fistula: The ureters are usually located at 5 and 7 o'clock positions in relation to the fistula opening on the proximal edge as shown here.

(D) In post-hysterectomy and vesico-cervical fistulas, the fistula is located at a higher level above the trigone (i.e. in the upper 1/3rd of the vagina closer to the level of the cervix). In these cases, the ureters open into the distal part of the fistula typically at 10 and 2 o'clock as shown here (see also Fig. 1.7d). As most fistulas are located in the middle or distal third of the vagina (1 and 2 above), the ureters are usually proximal.

Fig. 1.17a adapted from Clinical Urogynaecology 2nd edition 2000. Editors: Stanton S and Monga A; Chapter 23 Genitourinary Fistulae; W Glenn Hurt.

- It is good practice to routinely look for both ureteric orifices. This can be challenging especially if the fistula is small.
- With large fistulas, the intramural part of one or both ureters may have sloughed so the ureteric orifices are found along the edge of the fistula or occasionally they open separately into the vagina.
- With large fistulas, especially those that extend close to the cervix, it is better to catheterize both ureters at the beginning. The closer the fistula is to the cervix, the greater the chance that the ureters will be close to the edge of the fistula. However, do not expect normal anatomy after obstructed labour and you must assume the ureters are in danger for most VVFs.
- In smaller fistulas, visualization of the ureters is not possible (without cystoscopy) until the vagina is mobilized i.e. after step 2 is done.
- If the fistula is juxta-urethral, the ureters are unlikely to be near the edge but always check for them where possible – you will get surprises!

Tips for finding the ureters: there are various ways to see inside the bladder:

- The metal catheter is a useful small retractor. In fact, using the metal catheter and the suction tip at the same time is a useful way to see inside the bladder.

- Another option is to insert a pickups/ dissecting forceps or an Allis forceps into the bladder and spread them open to display the inside of the bladder.
- Insert one or two Allis forceps on the edge of the fistula to stretch the bladder edge (see Fig. 1.8a).
- In larger fistulas, insert a Sims or a small retractor into the bladder to retract the distal edge (Fig. 1.7b).

If you fail to find the ureters after a few minutes, run the intravenous fluids fast and give frusemide 10 mg IV. The increased flow of urine will make it easier to see the ureters by allowing you to see the spurts of urine. In fact, it is a good idea to routinely give frusemide for all VVF cases as you should know where the ureters are.

! Tip! Frusemide only works well and quickly if the patient is well hydrated. It is a good idea to start intravenous fluids at least one hour prior to surgery. This will avoid delays in finding the ureters during surgery.

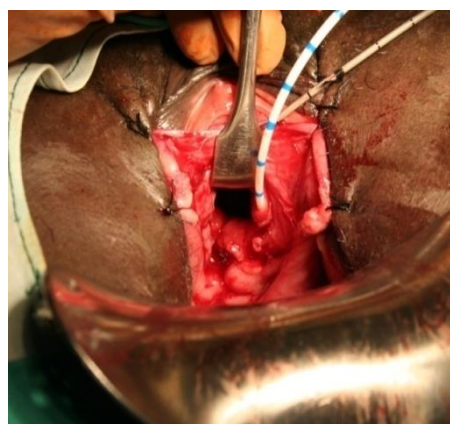
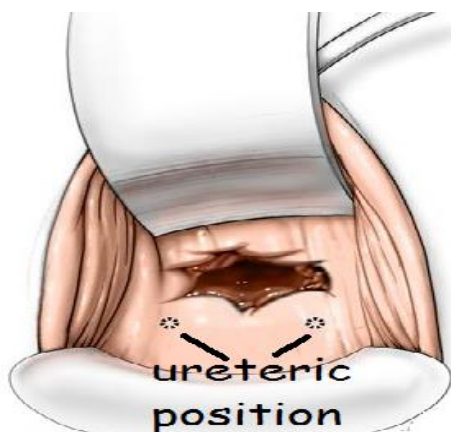

Fig. 1.7b: Diagram on the left (courtesy of Grace Chen) shows where to expect the ureters to be inside the bladder in a mid-vaginal fistula as seen from the vagina. The diagram on the right shows a Langenbeck retractor being used to retract the distal bladder wall so that the ureters can be seen on the proximal wall.

- ◆ If you cannot find a ureter in the bladder, look outside the bladder. If the inside of the bladder seems to be dry despite giving frusemide, look at the area where there is fluid. If you have done some dissection, the “blood” may be diluted by urine so you may not realize that you are mopping up urine with the blood.
- ◆ Do not enlarge the fistula to look for the ureters as you could cut the ureters. However, you may excise scar tissue around the fistula edges which often opens up the fistula and makes it much easier to see the ureters.
- ◆ The position of the cervix can be a guide to the site of the ureters, as each ureter will be on either side of the cervix. This can be very useful in large fistulas that extend out to one side i.e. if the ureter that you have found runs around the left side of the cervix, it is the left ureter.
- ◆ If you fail to find a ureter on one side, a post-operative ultrasound should be done in case there is already a ureteric obstruction/ fistula or in case you have obstructed the ureter during the present surgery. However, it is a good idea to do an ultrasound on all VVF patients pre-operatively to warn you of potential problems.

If the ureter is just inside the bladder (around a corner) but it is difficult to catheterize, the following tips may help:

- Place an Allis forceps above and below on the bladder edges. By stretching these, the ureteric openings may be more visible (see Fig. 1.8a). Dissect the vagina from the bladder before catheterizing. With the bladder more mobile, it will then be easy to catheterize the ureter. Stay close to the vaginal wall to avoid cutting into the ureter.
- Excise any scar tissue in the edges of the bladder as this will make the edges more pliable. It is then easier to see the ureters inside the bladder.

Once you find the ureter: Once the ureteric opening is seen, apply an Allis forceps near the opening (it is usually easiest to apply it just below the orifice as this will pull the bladder mucosa well down). A small metal probe is then used to identify the exact point of the ureteric opening and is passed up the ureter 2-3 cm. The ureteric catheter can be inserted behind the metal probe as the probe is withdrawn.

CAUTION! A metal probe may cause a false tract so never use force if it does not go in without resistance. The direction the ureter runs (as you pass the catheter) tells you which side it belongs to. If it runs to the left, it is the left ureter, if it runs to the right, it is the right.



Avoid applying Allis forceps on the bladder mucosa until you have clearly seen the opening as they can cause tearing and bleeding from the mucosa which will make it more difficult to find the ureteric opening.

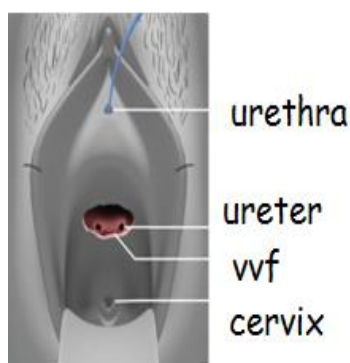


Fig. 1.7c: Shows the ureters in the typical 5 and 7 o'clock position.

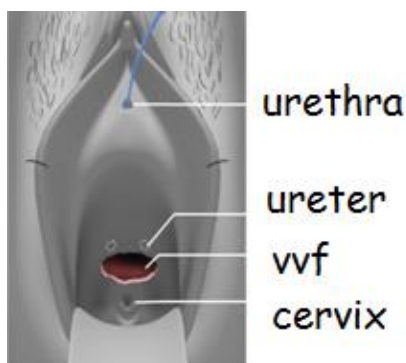


Fig. 1.7d: When the fistula is close to the cervix, the ureters are often at 2 and 10 o'clock.

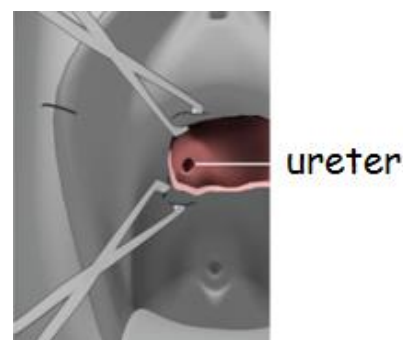


Fig. 1.8a: Shows two Allis forceps stretching the angle of the fistula to demonstrate the ureter.



Tip! Watch out for unilateral or bilateral double ureters. In such cases, you have to deal with 3 or 4 ureters. The incidence of double ureters has been quoted as 1:125. The extra ureter(s) may be found opening into the bladder or vagina. *Reference: Double ureter at repair of obstetric fistula: Kelly J, Moghul F. A, Pisani V. International Journal of Gynecology & Obstetrics. 2008; 102(1):77–78.*

CATHETERIZING THE URETERS

Unless you find the ureters are far away (> 3 cm) from the fistula edge, it is necessary to catheterize them. This is to avoid injuring or ligating the ureters during the repair. A size 5 or 6 ureteric catheter is inserted into each ureter as far up as it will go (usually about 20 cm – the ureteric catheters are usually labelled in centimeters). The other ends of the catheters are then drawn out through the urethra either by:

- (a) Threading the ureteric catheter into the lumen of the metal catheter (which has been passed into the urethra) and then pulling the metal catheter out (see Fig. 1.8b). To do this, it is necessary to take the wire out if present in the catheter. Hold the catheter with the non-toothed dissecting forceps as you push it up the lumen of the metal catheter. This will not damage the catheter.
- (b) Inserting curved mosquito forceps through the urethra, catching the catheter and pulling it out (see Fig. 1.8c).

Sometimes it is better to leave the wire in situ in the catheter. This makes the catheter easier to feel and partially protects the ureter in case the catheter is cut accidentally. This is because if a wire is in the catheter, you can usually only cut one side of the catheter and ureter as you cannot cut through the wire unless you use very sharp and strong scissors. To keep the wire in place, the options are:

1. Do the dissection with the wire in situ before you pull the catheter through the urethra. This is the best option.
2. Remove the wire, pull the catheter through and then the wire can be put back in once the catheter is pulled through the urethra although it is not always easy to do so.
3. Pass the catheter with the wire in situ first into the urethra. You can then pick it up in the bladder with forceps. The catheter is then passed up the ureter. This makes it easier to keep the wire inside.

If the catheter (or the metal probe) will not go up the ureter or if you have trouble getting into the ureter, try the following steps (this assumes that urine is seen coming from the orifice i.e. the ureter is unlikely to be completely blocked from any previous surgery):

1. Apply Allis forceps close to the orifice and pull gently to straighten out the ureter. It is usually best to apply the Allis just proximal (below) to the ureteric orifice and then pull upwards.
2. Pull the wire (if present) in the ureteric catheter back a few centimeters. This may help the catheter go up more easily.
3. Try a smaller size catheter e.g. size 4F.
4. If the catheter will still not pass up, it may be necessary to mobilize the vagina off the bladder (see Step 2 below) first and then try again.
5. Try to pass a small metal probe up carefully. This may straighten the ureter. Then with the probe in place, pass the ureteric catheter up beside this as you withdraw the probe. Alternatively, try a guide wire and pass the catheter over this.
6. If you are only able to get the metal probe in, then do the dissection with the probe in before trying to insert the ureteric catheter. The main reason the probe or catheter does not run up the ureter is the direction you are trying to push it.

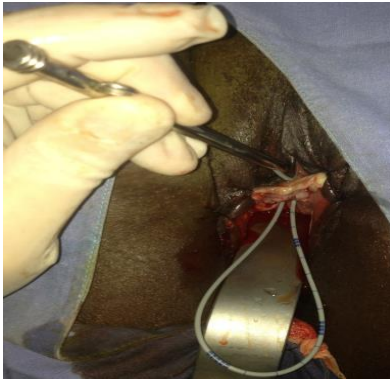

Fig. 1.8b:
Shows the ureteric catheter being pulled through the urethra with a metal catheter.

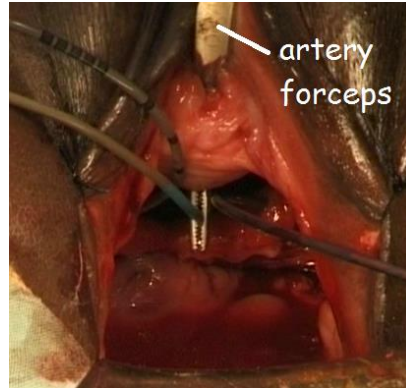
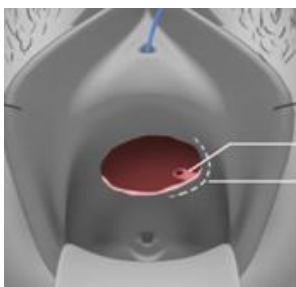


Fig. 1.8c:
Shows the ureteric catheter being pulled through with artery forceps.

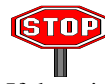

Fix the catheters carefully to the suprapubic skin as it is easy for catheters to get pulled out after surgery. Stitch the left ureter to the left side and the right to the right side for later identification. Fixation can be done more carefully at the end of the operation (page 33).



ureter
dissection

Fig. 1.9:
Dissection of the vagina off the bladder near the ureteric orifice may help mobilize the ureter and allow the ureteric catheter to pass.



If there is resistance as you push up the ureteric catheter, it usually means that you are creating a false passage. If the catheter is in the ureter, it should go in without resistance. Therefore, to push the catheter up, only hold it with your fingers or non-toothed dissecting forceps. Do not use force or else you can create a false passage.

If you are worried that you may have perforated the ureter i.e. no urine comes when the catheter is in place, flush it. Then remove the syringe and needle you have used to flush the catheter with and watch to see if the fluid comes back down the catheter:

- If the fluid comes back, it means perforation is unlikely although it is possible that the catheter is in a tight false passage.
- If it does not, perforation is likely as the fluid is leaking out at the site of perforation.

If the catheter will not pass despite all attempts and urine is seen coming out of the ureter: In this situation, the bladder stitches have to be placed quite superficially to avoid catching the ureter. It is safer to take several superficial bites rather than one deep bite if you think you are near the ureters. Try to bite only the fascia over the bladder rather than the bladder itself.

- As you do this, check that urine is still coming after each stitch. If it is not, take out the last stitch and re-do it.
- You may obtain a post-operative renal ultrasound to check for any obstruction.

If proper ureteric catheters are not available:

- (a) Use size 5-8 infant feeding tubes. Pass it first into the urethra so that you will keep the large connecting part outside. Once passed up the ureter, stitch the feeding tube to the bladder mucosa with absorbable (preferably plain catgut) suture near the ureteric opening to avoid expulsion by peristalsis. However, be careful not to go too close to the ureteric opening in case the suture obstructs it.



Tip! If you must use feeding tubes, pass them into the urethra and bladder using the metal (urethral) catheter which acts like an (external) introducer. This allows you to manipulate the feeding tube to where you want it to go. This is especially useful when passing the second tube as it can be difficult to know which is the first or the second if you do not have it attached to a metal catheter.

- (b) A less satisfactory alternative is to use the metal probe which is kept in the ureter while mobilizing the bladder and inserting the angle stitches (see step 3 below). You sometimes have to do this if the ureteric catheter does not go up the ureter. The probe is only kept in place until the angle stitches have been inserted and nothing is left in the ureters post-operatively.

STEP 2: DISSECTION OF VAGINA OFF THE FASCIA AND BLADDER

INITIAL INCISION

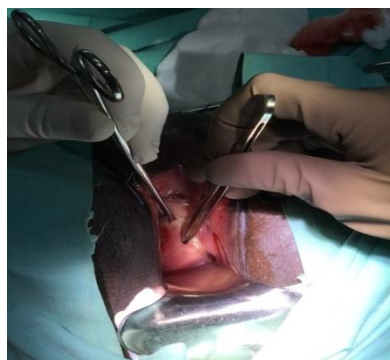
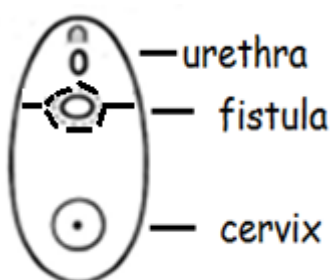


Fig.1.10b: In smaller fistulas, the edges can be stretched by inserting the toothed-dissecting forceps (pickups) into the fistula and opening them to aid making the initial incision.

Fig. 1.10 a: Show the initial incision around the fistula. The lateral extensions vary in length depending on the size of the fistula. When making the lateral extensions, incise at 3 and 9 o'clock i.e. just go horizontally from the lateral angles. This allows for good flaps to close the vagina.

The exact order you make the incisions (as opposed to dissection) is not critical. Usually, I would make the lateral, then the distal followed by the proximal incision.

- Make lateral extensions as shown in Fig. 1.10a to mobilize the vagina. The more mobility you require, the more lateral these incisions should go. In large fistulas, these will extend out from the vagina almost onto the perineal skin. This allows a distal flap (toward the urethral meatus) to be developed as shown in Fig. 1.12 below. In small fistulas, these extensions will remain within the vagina.
- Make a circumferential incision around the fistula edge. Either:
 - try to incise at the junction of the two epithelia (bladder/ vagina) or
 - incise about 0.5 cm from the fistula edge leaving a small rim of vagina on the bladder (see Fig. 1.10 a + b).

Tip! When making the initial incision, only go deep enough to cut the vaginal epithelium, and not the bladder or the pubo-cervical fascia underneath.

DISSECTING THE VAGINA OFF THE FASCIA AND BLADDER

Dissect the vagina off the bladder for about 2 cm all around the fistula. Wide dissection is the key to successful fistula repair in order to allow good mobility of the bladder edges, as these edges must be able to come together without tension. Therefore the larger the defect, the more extensive the mobilization has to be. Tension during closure results in failure. You should have a routine order for dissection of all fistulas as this helps especially with difficult ones (see Fig. 1.10c):

- *Distal:* Do the distal part first for three reasons:
 - It frees up your assistant from retracting.
 - It allows time for frusemide to work.
 - Most importantly as you retract the distal vagina with stay sutures (Fig. 1.12b), it helps expose the proximal part of the fistula.
 Provided you use a vasoconstrictor, bleeding inhibiting your view should not be a problem.
- *Proximal* is usually done next.
- *Lateral:* Lastly dissect the lateral part by opening the para-vesical space if necessary. This is not to be confused with the lateral extensions that are made to reflect the distal vagina.

DISTAL DISSECTION

- This part can be the least accessible. The trick for dissecting is to mobilize the tissue laterally before doing the central part i.e. start laterally and work in towards the centre.
- Hold the vaginal skin with an Allis forceps (point marked X in Fig. 1.11a) in the angle formed by the lateral extension and the distal incision. Then with scissors facing laterally towards the patient's shoulder, cut under the vagina (pulled up by the forceps as in Fig. 1.11b).
- Once this is freed, the part of the vagina over the distal fistula edge centrally is much easier to free (Fig. 1.12a).

- A useful tip, once the dissection is finished, is to stitch the distal vaginal skin flap to the labia majora skin. This keeps the vaginal skin out of the way and helps expose the bladder/ urethra. Put one stitch on each side. Avoid stitching to the labia minora as this will not provide sufficient retraction (Fig. 1.12b).
- The key to getting the distal flap to fold back is to make the lateral extensions lateral enough as shown in Fig. 1.10a.
- Thorek scissors are particularly good for the distal dissection because of their right-angled tips.

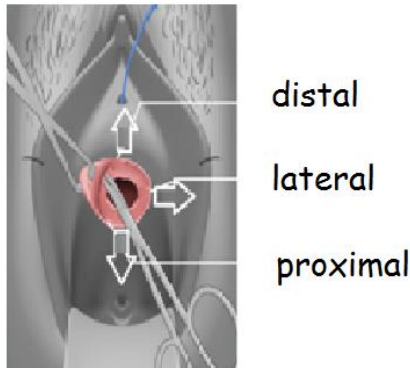


Fig. 1.10c: Shows the areas for dissection: distal, proximal and lateral.

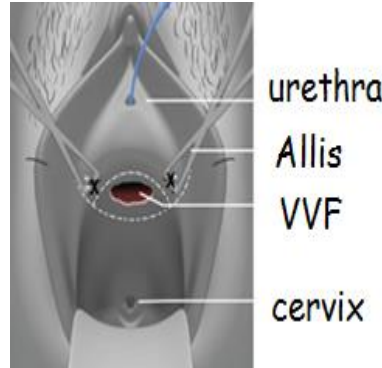


Fig. 1.11a: Shows the area X being held with Allis forceps. The X area is formed by the junction of the distal and lateral incisions.

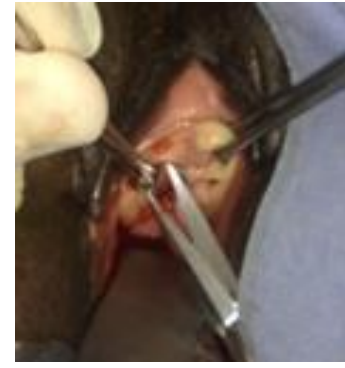

Fig. 1.11b: Shows the scissors aiming towards the right shoulder and about to be inserted under the tissue grasped by the Allis forceps.

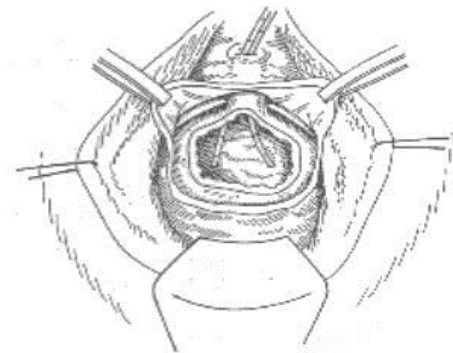


Fig 1:12a: Shows the distal vaginal skin dissected off the bladder/ urethra wall and being held with Allis forceps. (Les Fistules Obstetricales by Camey M.)

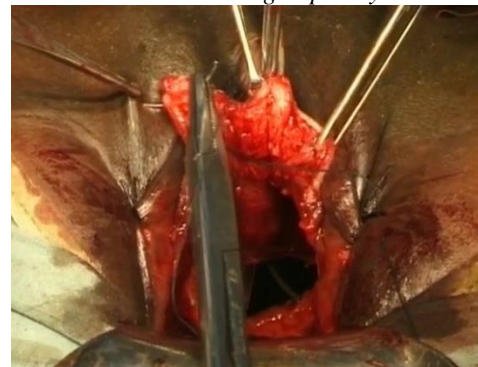


Fig. 1.12b: Shows the distal skin now being stitched back on each side to the perineal skin/ labia majora.

	<p>It is easy to damage the urethra when dissecting distally so not pull hard on the urethra as you dissect as it tears easily. There are several rules to reduce the risk of injury to the urethra:</p>
<ul style="list-style-type: none"> • Put a metal catheter into the urethra to allow you to feel how thick it is by pressing against the metal catheter from outside the urethra with your finger. • Stay close to the vaginal skin rather than the urethra. It may be possible to put your index finger behind the vaginal skin (outer or anterior surface) so that you can cut close to the vagina without making a hole in the urethra. • Between the urethra and the vagina lies the peri-urethral fascia. Often it can be clearly identified as a white sheet under the vaginal skin when entering the correct plane of dissection. Staying superficial to this thin sheet during dissection avoids trauma to the urethra. Bleeding usually indicates you are too deep. 	

PROXIMAL DISSECTION

Nearly all mobilization of the fistula comes from the proximal rather than the distal dissection.

- An assistant holds the proximal bladder edge of the fistula with Allis forceps and the surgeon grasps the vaginal edge with the dissecting forceps (pickups) as you separate the vagina from the bladder using traction and retraction to develop the tissue plane.
- In larger fistulas close to the cervix, as you mobilize proximally with the scissors held vertically, you will reach the harder tissue of the cervix. Instead of dissecting into the cervical tissue, you need to change the

scissors to a more horizontal direction so that you dissect under the bladder to get it off the cervix. A useful tip to do this is to keep the scissors horizontal (parallel to the floor of the operating room) to get into the optimal plane for this. The scissors are inserted between the bladder and the cervix/ uterus.

Note: This is the same step as pushing the bladder up during vaginal hysterectomy.

- Beware of too much blunt dissection during this step as scarring around the fistula can obliterate the normal dissection planes (Fig. 1.13).

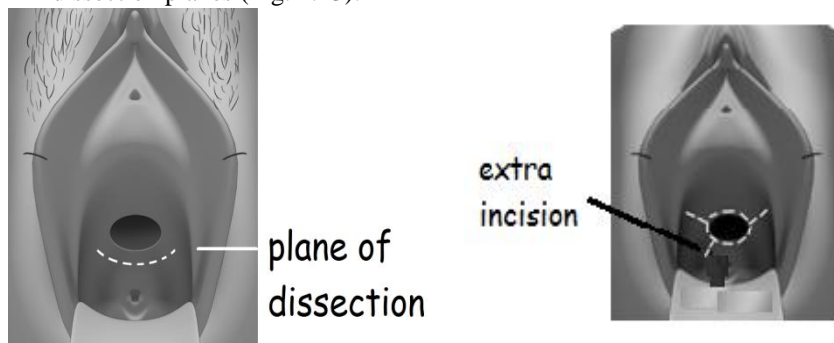



Fig. 1.13: During proximal dissection, finding the correct plane between the bladder and the cervix can be difficult (see text). Remember that the bladder is soft and the cervix is hard.

Fig. 1.14a: Sometimes when dissecting proximally, in difficult cases, a small incision proximally in the vagina will help in mobilizing the vagina and in avoiding the ureter.



Do not start the proximal or lateral dissection until you have identified the position of the ureters. This applies especially in larger fistulas. While waiting to find the ureters may take time, having to re-implant ureters will take longer if you cut them!

! Top Tip! The plane of dissection (and the scissors) changes from perpendicular to horizontal as you come near the cervix. This allows you to go around the corner as you follow under the bladder to mobilize it.

Often the tissues between the bladder and the cervix are fibrosed and the cervix may be damaged. One of the most difficult things to appreciate in fistula surgery is deciding where the bladder ends and the cervix begins especially if they are stuck together. There are a number of useful tips as to where to dissect (see Fig. 1.13):

- The cervix is hard whereas the bladder is soft.
- Estimate the thickness of the bladder wall by looking and feeling through the fistula.
- Estimate how thick the anterior lip of the cervix is likely to be from the distance to the external os. However, the cervix is often split or partially missing anteriorly so be sure to identify the cervical os. It may help to pass a metal catheter or a uterine sound into the cervix and feel how close you are to the cervix.

With this information, make an incision where you think the bladder ends and the cervix begins. If you are in the correct plane, the utero-vesical fold will often open easily. Opening this fold makes the mobilization of the fistula much easier. If the tissue feels hard as you dissect, it is likely that you are too close to the cervix.

LATERAL DISSECTION

The aim of the lateral dissection is to allow the lateral angle of the fistula to come medially so that you can close it without difficulty.

- Dissect about 2-3 cm lateral to the lateral edge of the fistula.
- In large complex fistulas, this means opening the space lateral to the bladder (known as the para-vesical space) on both sides. This is done by:
 - Pulling the bladder medially.
 - Making an incision close to the bone (but not too close to avoid bleeding) of the ischio-pubic rami. This is to avoid making a hole in the bladder. Once made, you then aim to get your finger into the para-vesical (retropubic) space which is recognized by fatty tissue and the muscles laterally (Fig. 1.14b).

If necessary, this dissection can be continued lateral to the urethra by continuing the dissection behind the ischio-pubic ramus to the para-urethral (retropubic) space distally (Fig. 1.14c). This allows the urethra to be mobilized well. This is more likely to be required if the fistula involves the urethra.

! Rule of thumb: The lateral distal dissection is safe, whereas the lateral proximal dissection may injure the ureter or you may encounter bleeding that is difficult to control.

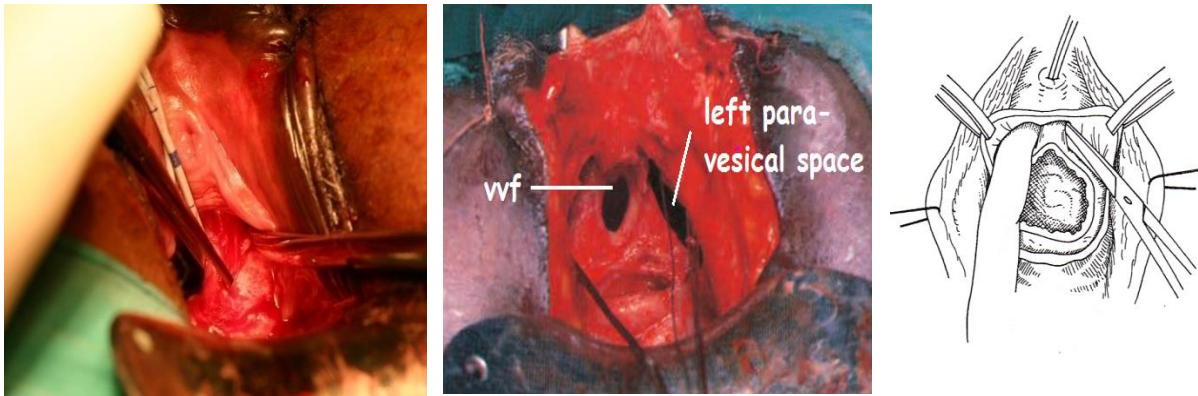


Fig. 1.14b: Shows left the para-vesical space being opened (Courtesy of Brian Hancock).

Fig. 1.14c: Shows the left para-vesical space now open (Courtesy of Kees Waaldijk).

Fig. 1.14d: Shows the dissection being continued distally to the para-urethral space if necessary (from *Les Fistules Obstetricales* by Camey M).

General points on dissection:

- Most of the dissection is performed with curved scissors. The curve of the scissors should be pointing towards the vagina so that it is away from the bladder.
- Once the incision is made, the bladder and vagina are held in opposite directions to create a degree of tension between them i.e. traction and retraction. This reveals adhesions under tension that can be cut to develop the surgical plane.
- Blunt dissection (pushing the bladder up with your finger) can be performed where there is no scarring. Your finger can also locate where scar tissue is so that you know where to cut.
- Blunt dissection by spreading the tips of the scissors is also a very good way of dissecting as this helps to find the correct plane with less bleeding.

! Tip! When dissecting, keep as much tissue on the bladder and urethra as possible i.e. stay close to the vaginal skin.

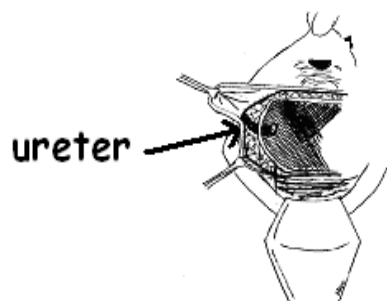


Figure 1.15: Shows the ureter (black) running in the bladder wall. The vagina is being retracted with forceps. The bladder is pulled medially as the vagina is retracted laterally during dissection.

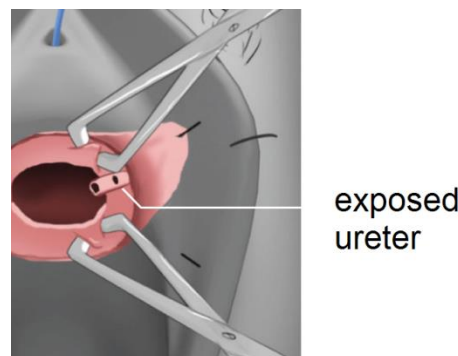



Fig. 1.16: Shows a small hole in the exposed ureter. After repairing the hole in the ureter, it may be possible to get a layer of bladder over the defect to act as a second layer. Hold the bladder on either side (above and below) a bit back from the ureter with Allis forceps as shown. Then suture this part of the bladder over the defect.


PROTECTING THE URETER DURING DISSECTION


Even if you have catheterized them, there is still a risk to the ureters as they run in the bladder wall when dissecting on the lateral and proximal side. To avoid damaging the ureter:

- Palpate for the ureteric catheter as you dissect. Move the ureteric catheter as it enters the ureter to see which path it takes.
- Stay close to the vaginal skin rather than the bladder when dissecting. You need to hold the vaginal edges (especially laterally) with forceps so that you can stay close to the vagina (Fig. 1.15). The forceps on the bladder edges pull the bladder medially (to stretch it) and allow you to see the path the ureteric catheter is taking in the bladder wall.
- In some cases, lateral dissection will be limited because of the ureter's location. You may have to accept this and get mobility elsewhere.

- When dissecting laterally, keep feeling for the ureteric catheter even if the ureter opens more distally into the bladder and seems to be far away.
- Do as much dissection as possible bluntly with scissors by spreading them rather than cutting.
- By leaving the wire in the ureteric catheters, this makes the ureters easier to feel and protects it from being cut completely across (only strong scissors could cut through the wire). This is a very important point.
- Once they leave the bladder wall, the ureters run between the bladder wall and the pubocervical fascia. Therefore you also have to be careful later if you take deep bites of the fascia as this could catch the ureters.
- The course the ureter runs in the bladder wall is usually in a proximal direction but sometimes it is directly lateral as shown in Fig. 1.15. The only sure way of identifying the ureter is to palpate the catheter. Feel the ureteric catheter running in the bladder wall. Then avoid sharp dissection in this area.

 **Tip!** The key to dissection is to stay close to the vagina on all sides. This allows you to stay away from the ureter and for adequate tissue on the bladder to be developed for closure.


 **Top Tip!** If you are about to cut tissue but you are not certain if it contains the ureter, clamp the tissue to be cut and then check if the ureteric catheter is still mobile. If it is mobile, it is not caught in the clamped tissue and this tissue can be safely cut.

	<p>The main blood supply to the bladder is close to the ureters. An important rule in fistula surgery is: It is better to do very little dissection along the ureter to avoid bleeding around the corner of the pelvis, which is very difficult to stop. On one occasion, the only way I was able to stop such (arterial) bleeding was to pack the vagina tightly and suture the pack in with sutures in the labia. The fistula repair had to be completed later.</p>
---	---

IF A URETER IS ACCIDENTALLY OPENED

(a) **If the ureter is partially torn:** i.e. it only tears on one side rather than being completely transected. If a ureter is accidentally opened, or tears during dissection, just re-approximate the torn edges of the ureter with the catheter inside.

- A fine suture of 4/0 or 5/0 should be used to avoid devascularizing the ureter. Use a small (17-22 mm) curved needle or a J-shaped needle as these can get into restricted spaces.
- The main difficulty with closing over the torn part is that the first stitch tends to obscure the view. Therefore, it is better to place 2 to 3 interrupted stitches first before tying them all.
- Once tied, check for any gaps between the stitches. Observe for any urine leaking.
- If possible, cover the repair with bladder – see Fig. 1.16.
- Leave the ureteric catheter in for 14 days if the ureter was repaired.

 **Tip!** When repairing a ureter or when suturing close to it anytime, check after each suture that the ureteric catheter moves very freely. If it does not, it means you are suturing too close to the ureter. Take bites on each side a little further back from the lumen of the ureter. If the catheter moves with difficulty, it is likely that the ureter will obstruct when the catheter is removed.

(b) **If the ureter is completely transected** during dissection: then it is better to re-implant it vaginally (see section 3.4) or abdominally. If performed abdominally, this can be done either:

- Immediately after the VVF is closed: especially if the bladder is of normal size.
- Later when the VVF has healed: especially if the bladder is small. In this case, it is a good idea to catheterize the ureter to avoid it becoming obstructed when the vagina is closed. It is better to use an infant feeding tube which can be transfixed with a suture to the vagina as this is less likely to fall out.

PROBLEMS IN DISSECTION & SPECIAL CIRCUMSTANCES

If the vagina tears: If the vagina is not dissecting easily from the bladder and tears, it usually means you are too close to the vagina. Go a bit closer to the bladder to get into the correct plane.

If the bladder tears, (see Fig. 1.17) it means you are too close to the bladder. To continue dissecting, move the Allis forceps from the edge of the VVF to the torn edge of the bladder to stretch the bladder. Dissect closer to the vagina.

- Hold the edge of the tear with Allis forceps and complete the dissection.
- Usually, it is best to close this injury with the VVF rather than to try to close it separately. Leave the bridge of bladder between the fistula and tear intact and close both together usually in a transverse direction (See step 3).
- If there is a wide distance between the tear and the fistula, you may decide to close them separately.

If there is a narrow bridge of bladder tissue across the fistula (see fig. 1.18a): This is not uncommon with large fistulas. The important point is that the ureters are often at either end of the bridge. Therefore do not cut

the bridge until you have catheterized both ureters. If you have catheterized one but the bridge makes it difficult to find the other one, then cut the bridge close (on the medial side) to the catheterized ureter.

If the utero-vesical peritoneum is opened while mobilizing the bladder: this is more likely if the uterus has been removed, and indeed in this situation may be worth doing as a planned part of the dissection, to improve mobilization. If bowel or omentum comes down through the pouch, a roll of gauze can be inserted to push it back. The pouch can be closed after the bladder is closed or left open i.e. just included in the vaginal closure.

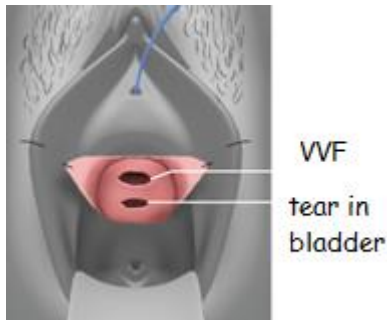


Fig. 1.17: Shows a tear in the bladder proximal to the fistula.

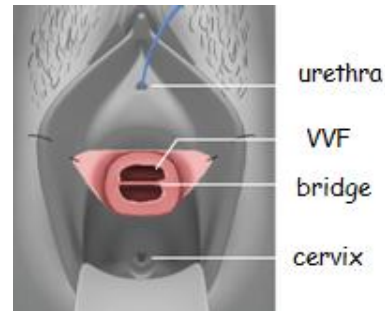


Fig 1.18a: Shows a narrow bridge of tissue in the fistula.

If the fistula is very scarred: Grasp the proximal part of the bladder in the midline and a bit to the sides with Allis forceps. Then look inside the bladder with the metal catheter. If you cannot see the ureters, start the dissection in the midline proximally. Then extend it upwards and laterally through the scar tissue. Stay close to the vaginal skin to avoid the ureters and use as much blunt dissection as possible. If you are outside the fascia of the bladder, the ureter is not likely to be at risk.


TRIMMING THE FISTULA EDGES

This is only performed as little as possible.

- If a small rim of vaginal skin has been left on the fistula edge, trim the edges of the fistula. This can be done with fine scissors. The fistula edges can be held with Allis forceps to stretch the edges. Only a small rim of tissue is removed.
- The bladder edges should be soft. If the edges you are about to close are hard, you may have to excise more scar tissue until you reach bladder tissue. If the edges are already soft, there is no need to excise.

SUMMARY OF DISSECTION

- Distally:* You do not actually get mobility distally but the aim is to expose the urethra/ distal bladder (with the overlying fascia) enough for repair. Mobility is gained by the proximal and lateral dissection. The aim of the distal dissection is only to get enough tissue exposed (the urethra and the distal bladder) so that you can insert the sutures. The urethra and the distal bladder are fairly fixed in this area so you have to get the bladder down to the urethra rather than the urethra to the bladder.
- Proximally:* between bladder and cervix. In larger defects, mobilize the bladder off the cervix. This is the place (besides retropubically for circumferential repairs) that you can gain most mobility.
- Laterally:* open the para-vesical spaces if necessary.

	SECOND CHECKPOINT: BEFORE YOU START CLOSING THE BLADDER
1.	Check that the fistula edges are sufficiently mobile on all sides. The way to do this is to pull the proximal fistula edge with an Allis forceps up to the distal edge to see that they can be approximated easily. If not, then mobilize further.
2.	Can you clearly see the extent of the fistula all around especially the angles of fistula?
3.	Check that the tissue is actually the bladder. Sometimes the tissue near the cervix may be confused with bladder especially if it is stuck to the bladder. Remember the bladder should be soft whereas the cervix is hard. Has scar tissue been excised from the edges?
4.	Are the ureters protected?

STEP 3: CLOSURE OF THE BLADDER

- The bladder should be closed in one layer. Two-layer closure is rarely possible in fistula surgery as it would create too much tension and is usually only possible in simple cases.
- In most cases, the bladder is closed transversely but check which direction will give the least tension (Fig. 1.19a).
- Closure is done with interrupted sutures of 2/0 or 3/0 Vicryl or chromic catgut. A continuous suture line constricts the blood supply more which may result in the breakdown of the repair.
- A suture only adapts tissue but cannot produce healing. Healing occurs in between the sutures.
- You want the mucosa inverted so that it is not visible. This is done by picking up mainly the muscle layer (Fig. 1.18 b+c). Either avoid the mucosa completely or only pick it up at the edge.

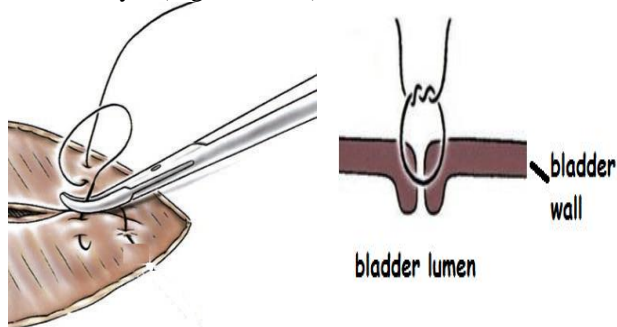


Fig. 1.18b+c: To get the bladder mucosa to invert, bites are taken 1-2 mm back from the edge so that you only pick up the muscle layer. (Courtesy Paul Hilton)

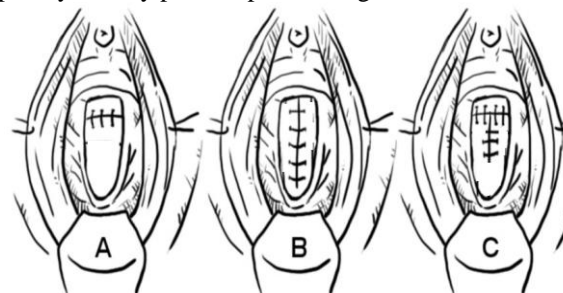


Fig. 1.19a: Closure can be transverse (A), longitudinal (B) or a combination (C). Adapted from *les Fistules Obstetricales* by Camey M.

The following description applies mainly to transverse closure which is the most common method used to close fistulas. **⚠ Top Tip!** If you have a choice, always close transversely as it is more likely to heal well.

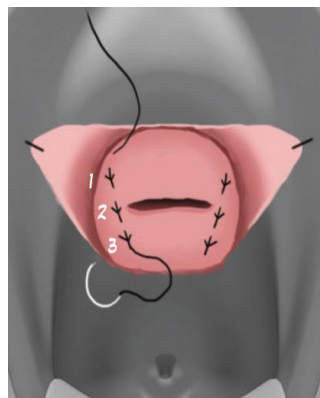


Fig. 1.19b: Showing the closure of the angles in 3 bites numbered 1, 2 and 3.

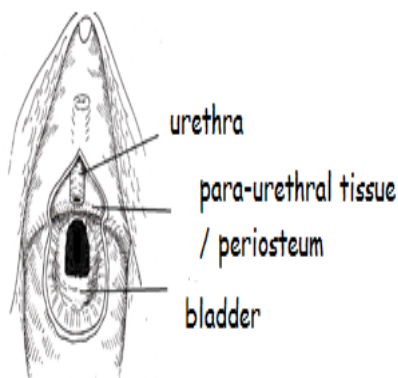
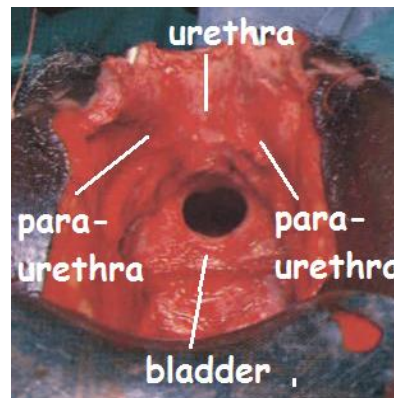


Fig. 1.20 a+b: In many large defects the distal lateral stitches will mainly bite on to the para-urethral tissue and the pubic bone. Only the distal central sutures go through the urethra itself. The proximal ones bite on to the bladder.



ANGLES

- Put in an angle stitch on each side first about 0.5- 1 cm lateral to the fistula edge. To take the angles well, it often helps to do it in three or more bites (Fig. 1.19b). If you only take two bites, when you tie, the area where the central bite should be taken (bite 2 in Fig. 1.19b) will tend to fold in and not close. This is often the cause of the persistent corner fistula.
- When one angle is far out to the side, close that side first as this will be the side that is more likely to leak. It is much easier to put the stitches in carefully initially, rather than trying to get them in later when there is a leak.
- For difficult angles see chapter 2 (Fig. 2.5).
- When closing the left angle, use a backhand grip of the needle with your elbow raised up and laterally. This allows you to place the suture better (see Appendix 2).

- While closing the angles, to avoid catching the ureteric catheters, take one bite above and one bite below the catheter (see Fig. 1.23c). Check the mobility of the catheter after you place the stitch.

! Top Tip! In most cases, before closing the angle, put an Allis forceps on the lateral edge of the proximal bladder and pull medially (see Fig. 1.23a+b). This makes it easier to see the angle. If it is still difficult to see the angle clearly, then you need to do more lateral dissection to allow the angle to come in more medially. Using an Allis forceps in this way is useful for displaying the angles and also the more lateral part of the fistula. Just trying to do this with the pickups/ dissecting forceps is not usually as effective and often leads to gaps in the closure.



- When closing the angles, make sure the ureteric catheters are freely mobile after inserting the first few sutures. It is better to discover this now rather than when the catheter is due for removal.
- If the ureteric catheter has been caught by a suture and it is too late to remove the suture, then the catheter will have to be left in place until the suture dissolves i.e. 3-4 weeks post-repair.

CENTRAL SUTURES

Sutures are placed 3-4 mm apart so that there are no visible gaps between the sutures. Work from the lateral part of the defect towards the centre on each side, alternating right and left.

! Top Tip! As the defect becomes smaller, to help with exposure, stretch the proximal bladder by pushing pickups/ dissecting forceps or a metal catheter into the fistula (see Fig. 1.23d). This makes it easier to insert the needle into the proximal edge of the fistula as it is pushed forward.

- When the bladder closure is complete, if you are not sure if more sutures are required, the suture line can be tested for defects by probing it gently with the closed pickups or metal catheter (between sutures). It is better to find gaps between sutures at this point in the surgery rather than later with the dye test.
- When a fistula is small or juxta-urethral, it may become increasingly difficult to place the sutures as you work towards the centre. In this case, it may help to place all the central (2-3) sutures before tying them.

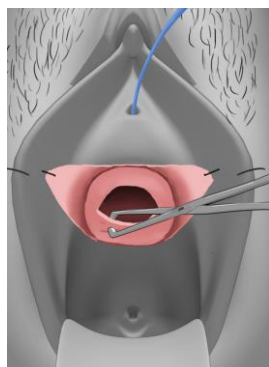


Fig. 1.23a: This shows the bladder edge being pulled medially to show the proximal fistula margin clearly.

Fig. 1.23b: Once the angle and lateral edge are clearly shown, the suture can be inserted more securely.

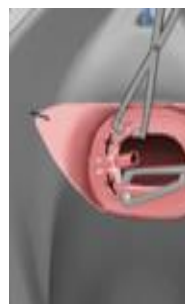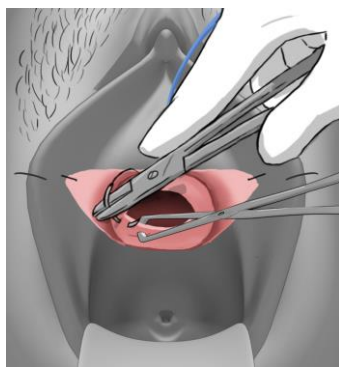


Fig 1.23c: Shows the sutures being inserted to avoid catching the ureteric catheters.

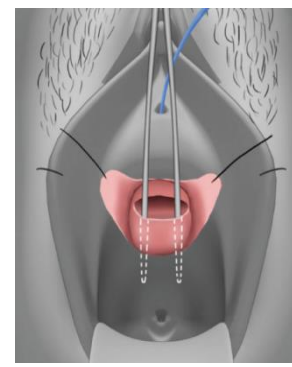


Fig. 1.23d: The pickups are used to stretch the proximal bladder.

! Tip! As you are closing a fistula, it is sometimes difficult to see the remaining part of the defect especially as you get to the central part of the fistula. Use the metal catheter to find it either by (a) inserting it via the urethra and then out through the fistula or (b) directly into the area where you think the fistula should be. Using a thin metal catheter in this way is a great way of deciding where to place your next suture. Alternatively, you can use a fine pickups/ dissecting forceps.

! Top Tip! It is a good idea to insert the Foley catheter before the first layer of the bladder is completed in case you have difficulty inserting the catheter in later. This is especially important for fistulas involving the bladder neck/ urethra. To avoid the risk of catching the Foley catheter with a suture, place the last 3-4 stitches with the metal catheter in place but do not tie the sutures. Then remove the metal catheter and insert the Foley catheter. Only tie the sutures after the Foley catheter is inserted.

- Use 16F if possible but 14F or very occasionally 12F may be used (usually for urethral repairs) if there is any difficulty with 16F.
- Using an 18F is okay when the fistula does not involve the urethra. Large catheters may irritate the urethra but are less likely to get blocked. Clots can only be flushed out with size 16-20F.

Summary of tips for displaying the proximal fistula margin:



The distal part of the fistula is usually easy to see. You must make sure that you can see the proximal part clearly to avoid missing part of the bladder wall. This is critical to getting good success rates with your closures.

- *At the angles and the lateral part of the fistula:* Use an Allis forceps on the proximal edge and pull medially as in Fig. 1.23a + b.
- *Central part of the fistula:* Use pickups or metal catheter inserted into the fistula to push the bladder edge forward as in Fig. 1.23d. When the defect is very small, the metal catheter can be used from inside the bladder to push the proximal bladder forward.
- *All sites:* Once the distal suture bite is placed, get your assistant to retract the suture upwards to show the proximal edge of the fistula. This allows you to place a good proximal bite.

LARGE DEFECTS

An important concept to grasp for dealing with large fistulas is that:

- The distal lateral bites are taken through the para-urethral tissue and periosteum (Fig. 1.20a + b). Only the central 2-3 distal bites can go through the actual urethral wall/ pubo-urethral fascia which is relatively weak and at risk of tearing.
- The proximal bites are taken in the bladder. This means you are closing the lateral part of the bladder to the para-urethral tissue (and bone) rather than the urethra.
- Also, there is often a discrepancy in size between a narrower distal end and a wider proximal end. If the discrepancy is not severe, then the distal bites are taken vertically while the proximal bites are taken horizontally (see Fig. 1.20c). For major discrepancy, see section 2.4.

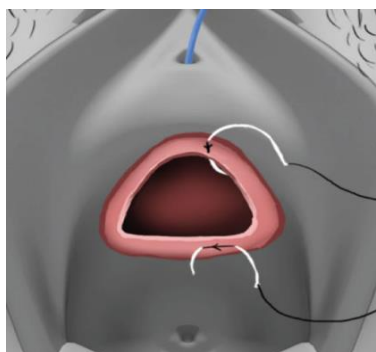


Fig. 1.20c: Shows the distal bites being taken vertically and the proximal bites being taken horizontally.

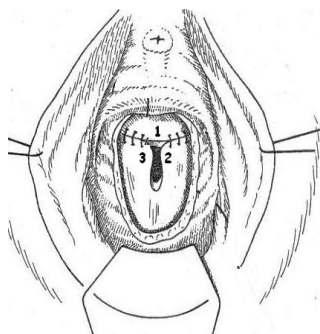


Fig.1.20d: Shows a T-junction being closed with a triangular stitch.

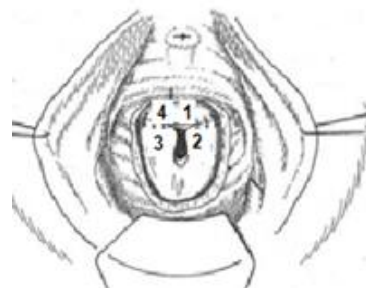


Fig. 1.20e: Shows a T-junction being closed with a mattress stitch.

FORMATION OF A T- JUNCTION

If when you are attempting a transverse closure, you find that there is too much tissue proximally, you can close the central part vertically as shown in Fig. 1.20 d and e. The T-junction (of the transverse and the longitudinal closure) is a potential point of weakness and must be closed with care. To avoid problems:

- Make sure to come up on the vertical closure as distal as possible so the gap between the urethra and the bladder is very short.
- To join the urethra and the bladder, either:
 - Use a triangular stitch taking bites at points 1, 2 and 3 and then tie the suture (Fig. 1.20d). To reinforce this area, a second more superficial triangular stitch can be repeated at points 1, 2 and 3. See also Fig. 2.20c (in chapter 2) for an alternative way of placing this stitch.
 - Or a mattress suture with four bites can be placed as in Fig. 1.20e.

LONGITUDINAL CLOSURE (See Fig.1.21 and 1.22)

When the defect does not come together easily transversely, check if it will come together longitudinally. When stitching longitudinally, it is more difficult to see gaps between sutures. To avoid this:

- Leave the short ends of the suture on an artery forceps so that you can check for any gaps in between sutures.
- Use the metal catheter to probe for gaps along the line as you close the incision.
- Put in the proximal angle stitch first, followed by the distal angle stitch.
- If there is a layer of pubo-cervical tissue laterally on either side, this can be included in the bites while closing the bladder or used as a second layer. Alternatively, some surgeons only close the fascia over the bladder without closing the bladder separately, especially for small fistulas (see also section 3.1).
- When closing longitudinally, it is usually best to take the angles in three bites i.e. the first bite is taken laterally, the second bite is across the fistula angle and then the third bite is taken laterally on the opposite side. To invert the mucosa as you tie the proximal suture, place an Allis or two dissecting forceps on the angle to push in the mucosa as shown in Fig 1.21.

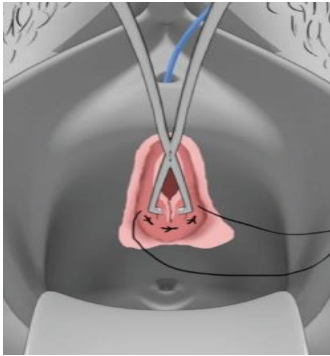
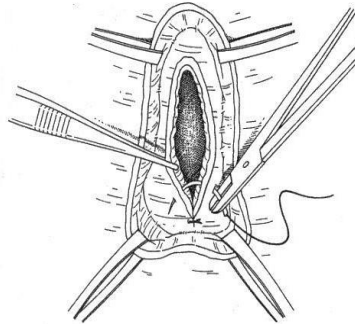


Fig 1.21: Shows the angle suture being inserted.



*Fig. 1.22: Once the angle suture is inserted, continue distally with interrupted sutures. Note the use of the backhand grip when inserting from left to right (from *les Fistules Obstetricales* by *Camey M*).*

FOLEY CATHETER

If there is difficulty inserting the Foley catheter: try the following steps:

- (A) Use a small probe inserted into the tip of the catheter to act as an introducer. Once the catheter is in the bladder, inflate the balloon before you remove the introducer so that the catheter does not come out as you pull out the introducer. The only problem with inflating the balloon before you have finished closing the bladder is that you may puncture the balloon as you insert the final stitches. Therefore advance the catheter well into the bladder and be careful with the stitches.

CAUTION! When the bladder is small, if you have difficulty inserting the catheter, you may perforate through the bladder and cause a new hole if you are not careful. Do not go in too far with the probe.


- (B) Consider removing the last few sutures inserted until the catheter can go in easily.

- (C) If you still have difficulty, it is best to insert a size 14F Foley or place a Nelaton catheter (see Appendix 5).

Tip! Anytime you are repairing a fistula that involves the urethra, if you have trouble inserting sutures without catching the Foley catheter: Place all the central sutures with the metal catheter in place but only tie them after inserting the Foley catheter.

If you catch the Foley catheter with a suture: and you recognise this during the operation but it is too late to undo the suture(s), slide thin sharp scissors along the Foley until you find the suture and cut it. Replace the Foley as it leaks from the hole and sometimes you will have punctured the channel for the balloon.

If this is not possible and removing sutures would increase the risk of failure of the repair, leave in the catheter longer than usual to allow time for the sutures to dissolve.

	<p>Make sure the balloon of the catheter is fully in the bladder before allowing your assistant to inflate it. A common mistake is for the assistant to pull on the catheter as he inflates the balloon. This can result in the balloon being inflated in the urethra which can lead to tearing of the urethra.</p>
---	---

Tip! If you have trouble inserting the Foley catheter, it may help to use the hole in the almost-closed fistula to assist the catheter going in with a non-toothed dissecting forceps.

Tip! Always inflate the balloon of the Foley catheter immediately after inserting it before doing the dye test. Otherwise, the catheter may come out during the dye test. It is sufficient to inflate with 5-10 mls.

DYE TEST

Check that the repair is water-tight at the end of the bladder closure. Make it a routine to empty the bladder before you do the dye test in case the bladder is already full. There are different methods of injecting dye (diluted methylene blue or gentian violet) via the Foley catheter: the push, gravity and pressure methods.

The push method: The common method in the past has been to inject 60 ml of dye and exert gentle pressure suprapubically or get the patient to cough. You may have to block the urethra with digital pressure (see Fig. 1.24e) when doing this especially if a lot of the dye leaks out through the urethra, as otherwise you may miss a leak. The problems with the push method are:

- If the bladder is small, even 60 ml of dye may be too much. With high pressure, the repair will start leaking everywhere even if it is adequate.
- The problem with supra-pubic pressure or getting the patient to cough during the dye test is that these may increase the intra-vesical pressure by 100 cm H₂O or more, and these are more likely to cause stress leakage from the urethra. Because of the problems with the push method, the following methods are preferred.

(a) **If you suspect a small bladder or you are not sure of the size: use the gravity method** (see Fig. 1.24 f + g):

- Using only the barrel of the syringe, attach it to the Foley catheter.
- Then pinch the Foley catheter as you fill the syringe so that you can measure the amount that goes into the syringe.
- Hold the syringe barrel about 20 cm above the urethral level and let the dye flow in by gravity.
- Continue to fill the syringe until dye no longer flows.

The advantages of this method are:

- Up to 180 ml of dye (depending on the bladder capacity) will lead to only a few centimetres H₂O pressure rise.
- It is especially useful if the bladder is small.
- It gives an estimate of the bladder capacity which is useful if the patient has incontinence later.

(b) **If you think the bladder is a reasonable size: use the pressure method:** this is a faster method especially if the bladder is of normal size. The aim is to fill the bladder until the pressure within the bladder is 10 cm H₂O.

- The syringe end of the catheter is held vertically 10 cm above the urethra (see Fig. 1.24h) without the barrel of the syringe attached.
- Only attach the syringe to the catheter when injecting a syringe with dye and then remove the syringe.
- Check the pressure after every 30 ml of dye. When you see the dye rising up and leaking out the Foley, then the pressure has reached 10 cm (see Fig. 1.24h).
- Measure the volume in the bladder at the end by emptying the dye into a container.

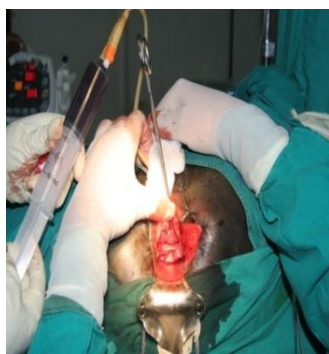

Fig. 1.24e: Shows the push dye test. Note the urethra is being compressed to prevent leakage.

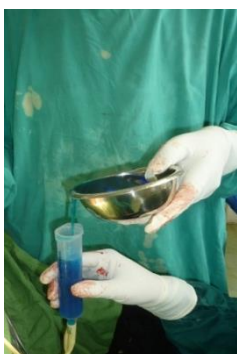

Fig. 1.24 f and Fig. 1.24g: Show how to do a gravity dye test.

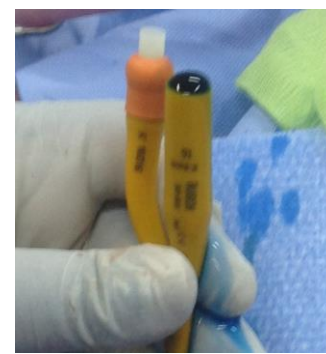
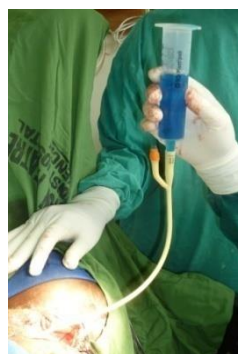
Fig. 1.24h: Shows the pressure dye test with the dye spilling out of the Foley catheter.

If the dye test is positive: there is a natural disappointment and a sense of failure. However, do not make the situation worse by rushing to correct it. Try to insert a small metal catheter into the defect. Then apply Allis forceps to identify the leaking area clearly. See how big the defect is.

- If the defect is small and can be clearly seen, 1-2 more sutures are applied to the leaking area. It often helps to mobilize the intermediate layer/ pubo-cervical fascia (see below) and use this as part of the closure.
- If the defect is larger than a metal catheter, you probably have an unrecognized gap in the bladder closure. It is probably better to undo the repair on the affected side and start again.

If there is only a tiny leak: especially if it occurs when the bladder is full, it is likely that the bladder will heal with free drainage. On one occasion after doing a difficult repair, there was a tiny leak high up. Rather than redoing the repair, we just relied on the free drainage and the fistula healed.

If the dye test remains positive:

- If the dye leaks and it is not possible to put more sutures in the first layer, build up the intermediate layer (see below) and repeat the dye test. This usually means applying a patch of pubo-coccygeus or a Gracilis flap over the area and stitch it in place.
- If the angle is leaking and you have closed it well, it would not be a good idea to undo the repair. In this situation, sew the bladder to the pelvic side-wall over the leak and then maybe even add a muscle patch over it. For example, if there is a leak at 2 o'clock (on the left), stitch the bladder to the pelvic side wall muscles from about 1 o'clock to about 6 o'clock. Try to suture as close to the defect as possible to close the defect as tightly as possible and not to make any tracks under the sutures from the fistula to the outside. Use interrupted stitches to do this. Surprisingly this method sometimes works. (See also section 5.3b if you have failed to close the angle securely.)

STEP 4: INTERMEDIATE LAYER

- The main purpose of an intermediate layer is to reduce the risk of failed repair by acting as:
 - a. A mechanical barrier by separating the bladder/ urethra from the vagina or uterus.
 - b. A source of perfusion of previously poorly vascularized tissue. Therefore the intermediate layer should preferably be vascular and easily mobilized with its blood supply.
- In addition, in any VVF there is anatomic tissue loss of the endopelvic musculo-fascia as well as the bladder/ vagina defect. Therefore one should make an effort to identify the musculo-fascia defects and repair them together with the fistula. This will help restore continence.

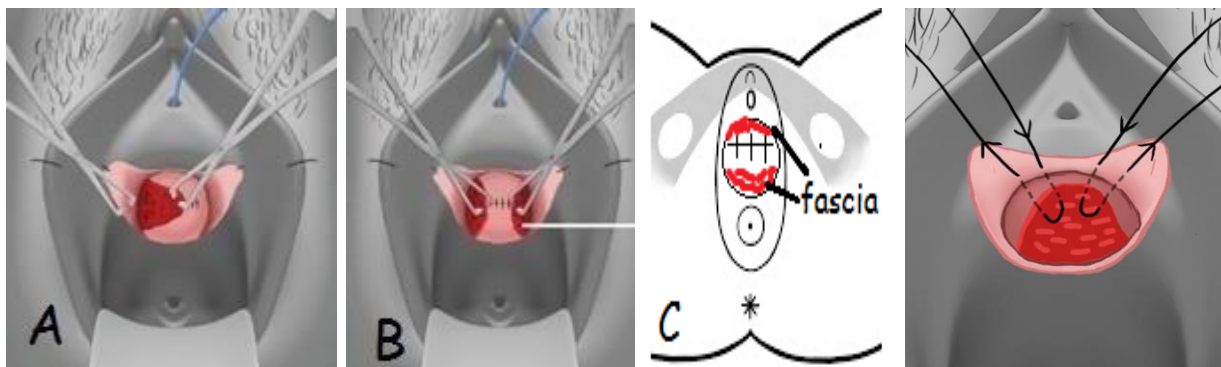


Fig. 1.25: A: An Allis forceps is applied to the pubo-cervical fascia which is pulled medially while a second Allis is applied to the vagina which is pulled laterally.

Fig. 1.25B: Once mobilized, stitch the fascia of each side across the midline to cover over the VVF repair. Several sutures may be required.

Fig. 1.25C: In some cases, the fascia/ smooth muscle (in red) may be approximated transversely by suturing the distal tissue over the urethra and para-urethral tissue to the proximal tissue which is found between the bladder and vagina in front of the cervix. In Fig. 1.25D this layer is re-attached directly to the bone.

For healing of the fistula, an interposition layer is not usually needed if the bladder tissues appear well vascularized. While there is no high-level evidence to confirm the benefit of placing an interposition layer, most fistula surgeons would use tissue interposition in selected cases:

- a. Those that have failed previous repairs especially if scarred or multiple repairs
- b. Fistulas post-radiotherapy
- c. A fistula associated with a difficult or tenuous closure because of poor tissue quality i.e. the bladder is thin or friable or if there is difficulty getting the dye test negative.
- d. Distal fistulas do not heal as well as proximal ones. Therefore for juxta-urethral and fistulas involving the urethra, it is a good idea to place an intermediate layer. In these, it may also reduce the risk of stress incontinence.

There are several options:

- (1) **Pubo-cervical fascia:** This layer lies between the bladder and the vagina. Do not look just for fascia but for smooth muscle since that is the main component of this layer. In smaller fistulas, where there is not too much tissue damage, often this layer can be developed on each side as you dissect laterally (see Fig. 1.25a,b,c).

- (2) **Bulbocavernosus muscle/ Para-urethral tissue:** this is useful for fistulas of the urethra as it is found just lateral to the urethra, superficially under the skin. By mobilizing it on both sides, a sling can be formed across the urethra. The tissue does not resemble muscle but is more like fascia.

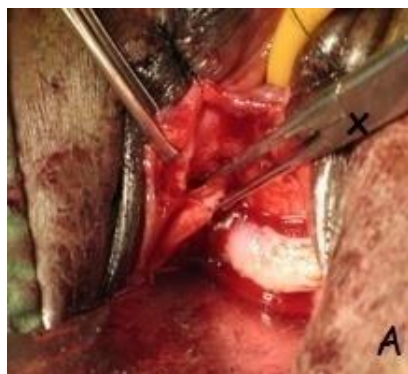


Fig. 1.27a: Shows the pubo-coccygeus muscle being grasped with an Allis forceps marked X.

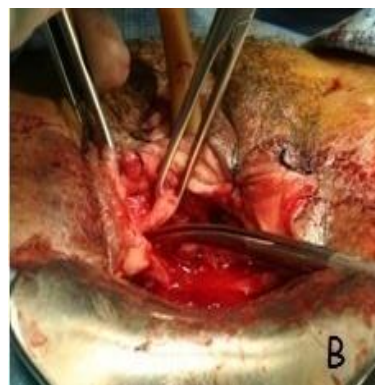


Fig 1.27b: Shows the muscle being freed proximally by cutting sharply with scissors.

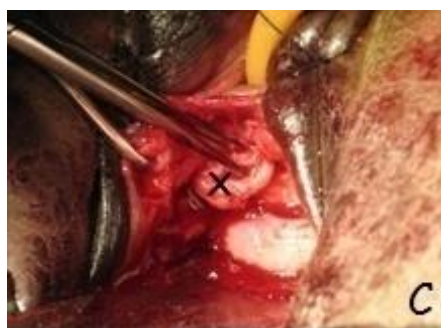

Fig. 1.27c: Shows the freed muscle (marked X).

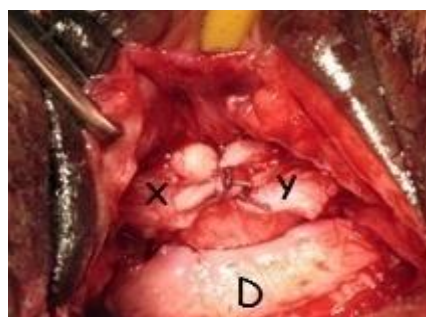


Fig. 1.27d: Shows the muscle (X) sutured to the one (Y) from the opposite side.

- (3) **Pubo-coccygeal muscle:** This is the medial part of the levator ani so it is quite deep (below the bone of the ischio-pubic ramus as you look vaginally) and found in the lateral pelvic wall. It is deeper than the pubo-cervical fascia. It is particularly good for juxta-urethral fistulas. There are two main uses of it:
- If mobilized on both sides, this tissue can be sutured together in the midline across the urethra to form a sling (Fig. 1.26b). The aim is to reduce the risk of stress incontinence although this is not proven. There is only weak evidence from one study where stress incontinence reduced from 33% to 18% after the introduction of the sling. Reference: *Browning A: Prevention of residual urinary incontinence following successful repair of obstetric vesico-vaginal fistula using a fibro-muscular sling: BJOG April 2004, Vol. 111, pp. 357–361.*
 - If mobilized from one or both sides, it can be applied as a patch or intermediate layer over a fistula. It is particularly good for covering repeat corner repairs (see section 3.8). See Fig. 1.27a-d.
- (a) You often need to dissect more of the vaginal skin off the lateral wall posteriorly to expose the muscle i.e. it is the lower flap of the lateral extension that needs to be freed more. The line of muscle is deep to and in the line of the lateral extension.
- (b) Start proximally and apply an Allis forceps to the muscle to pull medially as you dissect out the tissue. Free the upper border of the muscle bluntly by pushing in and opening scissors.
- (c) Then cut with scissors to free the muscle flap proximally. Initially just cut in a transverse direction (Fig. 1.26a) into the muscle.
- (d) Once the proximal part is free, then cut laterally so that you end up with a 1-2 cm wide cylinder of muscle. The trick is to pull on the Allis as you are cutting. You should end up with a flap on each side which has its base distally at about 2 o'clock on the left or 10 o'clock on the right as shown in Fig. 1.26b. Do not go too deep or cut too close to the bone as this increases the risk of bleeding. If cautery is available, this can be helpful both for developing the pedicle and haemostasis. See that the tissue comes to the midline without tension on each side before any stitching. If it does not, mobilize it more.

! Tip! When stitching either the pubo-cervical fascia or the pubo-coccygeus: start the suture from the mid-line and take a bite of the right side. Then starting again from the mid-line, take a bite of the left side. The reason for doing this is that when you tie this suture, it is less likely to pull through the tissues as both sides pull towards the centre (known popularly as the baseball stitch).

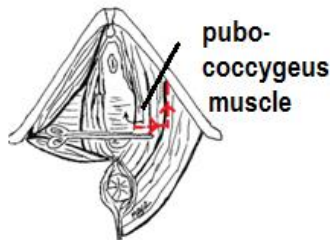


Fig. 1.26a: Shows the anatomy and direction of cutting (red arrows) the pubococcygeus muscle which is about to be cut proximally.

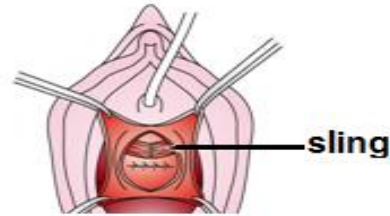


Fig. 1.26b: Once a strip of muscle is freed on each side, it can be tied across the midline.

- (4) **Martius graft/ flap:** Where there is no tissue to form an intermediate layer, a Martius graft can be performed in some cases especially for fistulas involving the urethra (see section 8.4).
- (5) **Gracilis flap:** Because of its size and vascularity, this is an excellent flap which is occasionally used in difficult repairs (see section 8.5) i.e. repairs that have a high risk of failure.
- (6) **Peritoneal flap:** This can be used in a vault or any high fistula. It is brought distally to cover the fistula suture line, and attached to the distal bladder wall or periosteum. Either:
 - If the pouch of Douglas is opened, then a flap of peritoneum can sometimes be brought down. When available, this is a safe option as there is no risk of injuring the bladder.
 - The peritoneum may be dissected without opening the pouch. One of the dangers of this is that you may dissect into the bladder wall.
- (7) **Omentum:** This can be used occasionally if it presents itself when either the anterior or posterior pouch is opened.



THIRD CHECK POINT: BEFORE STARTING TO CLOSE THE VAGINA

i.e. before you cut the stay sutures that retract the distal vagina, ask yourself if there is anything you are forgetting? Have you done the dye test? Is the Foley balloon inflated? Did you need to place an intermediate layer? Does the cervix need repairing?

STEP 5: CLOSURE OF THE VAGINA

- While stitching the vagina, it often helps to replace the weighted speculum with a smaller Sims speculum.
- The proximal vaginal edges may be difficult to see and are held with Allis forceps once found.
- A large needle (36 mm) is useful in getting deep, haemostatic bites of tissue.
- If there is difficulty closing the vagina due to skin loss, see section 8.1.

If the vagina is friable and cannot hold the stitches: Remember to use a large needle. Chromic catgut is less likely than Vicryl to cut through the tissues.

- Distally: insert the stitch as distal as possible, if necessary starting almost outside the vagina to get a good bite of skin.
- Proximally: go deep also and if necessary go close to the cervix.
- To close the dead space, it helps to take bites of the fascia underneath the vagina as you stitch the vagina.

When the VVF was large and there were large lateral extensions made in the vagina, you need to use a slightly different technique to close it (Fig. 1.28 b + c). Do not start at the most lateral point of the vaginal opening. Instead, place the first stitch at about 10-11 o'clock on the left and 1-2 o'clock on the right. These bites should close the angles of the original (vaginal part of the) fistula rather than the lateral extensions. If you placed the very lateral sutures first, they would obscure your view of the more medial vagina. Most of the bleeding tends to be from the more medial aspect so it is important to secure this first. An optional extra when closing the vagina in cases of juxta-urethral fistulas, on each side, having taken the distal bite (1 in Fig. 1.28d) through the vagina, take a bite (2 in Fig. 1.28d) of the periosteum at 11 or 1 o'clock. Then take the proximal vaginal bite (3 in Fig.

1.28d) and tie. The purpose of this stitch is to prevent the vagina pulling the urethral orifice open. Only one of these sutures is placed on each side.

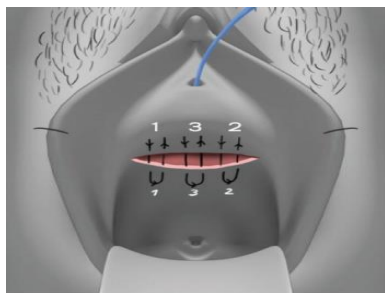


Fig. 1.28a: Shows closure of the vagina with interrupted mattress sutures. In most cases, the vagina can be closed transversely by a series of interrupted (vertical) mattress sutures.

- Close each angle (1 and 2 as shown) first, and then the more central sutures (3).
- Start distally and go proximally with deep bites. Therefore start 2 cm back from the edges. Taking deep bites helps to close any dead space.
- Then come back up closer to the edges and tie as shown.

If the vaginal opening is large:

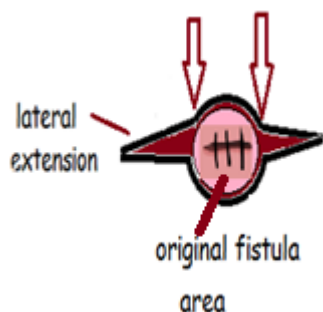


Fig. 1.28b: This is a diagrammatic representation of the open vagina. The arrows represent where you place the initial sutures.

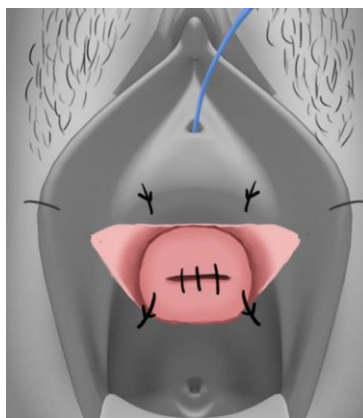


Fig. 1.28c: Shows the placement of sutures where vaginal closure should begin.

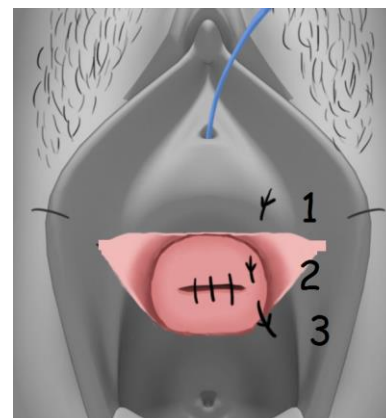


Fig. 1.28d: Shows the vagina being closed with a suture that incorporates the periosteum at 1 o'clock.

WHAT CAN YOU DO DURING THE OPERATION TO REDUCE THE RISK OF STRESS INCONTINENCE?

- Intermediate layer:** In all cases of Goh 3 + 4 or Waaldijk Type 2 fistulas, look for defects within the pubo-cervical fascia/ smooth muscle and its attachment to the pubic bones. Then repair them carefully.
- Fascial sling:** This can only be placed at the time of repair if no tension is applied to the sling, otherwise it is likely to interfere with healing of the fistula.
- Vagina:** When closing the vagina in fistulas that involve the urethra: If there is a deficiency of skin, it is important that there is no pull on the urethral opening.
 - If the vagina can be approximated without tension, insert the suture as shown in Fig. 1.28d.
 - Consider using a skin flap to close the anterior vagina (section 8.1) if the two sides of the vagina are widely separated. It is better not to forcibly approximate them, as otherwise the scarred tissue will pull open the posterior urethral wall. This tethering effect may keep the urethra constantly open even at rest. In trying to decide whether to do a flap or not, during vaginal closure it helps to assess: (a) Is the urethra being pulled open? (b) Is the cervix being pulled anterior? (c) Is there tension when closing? If the answer is yes to any of these, then a flap should be considered.
 - To further reduce the risk of stress incontinence with a Singapore flap, a suture can be placed through the fascia of the flap to the rectus sheath – see Singapore sling chapter 8.

STEP 6: LAST STEPS + SUMMARY

(1) VAGINAL PACK: Good packing is important to reduce the risk of bleeding and hematoma formation. If proper packs are not available:

- Stitch several gauze swabs together with one bite of a suture and tie this. The number of swabs will depend on the size of the vagina. Avoid any unattached swabs which can easily be left in the vagina.
- Use an abdominal swab which can be cut if necessary.

Always leave a piece of swab protruding out of the vagina to avoid patient discomfort when removing the swab.

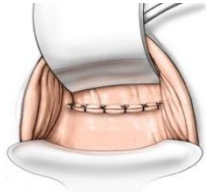



Fig. 1.29: Shows a retractor in place.

- A speculum should be inserted anteriorly to protect the suture line as you insert the pack (Fig. 1.29).
- If there are some areas of the vagina where it was not possible to get complete closure, then use Vaseline gauze tied to the start of the pack for the initial packing to avoid the pack sticking to the raw areas.
- In cases where you are concerned about post-operative bleeding, the pack may be sutured in place to increase its effectiveness. Place 2-3 deep transverse sutures into the labia majora on each side. This will keep pressure on the pack in the vagina.

	<p>The most common reason for bringing a patient back to the operating room is bleeding from the vaginal edges. Before you pack, swab the vagina to check that all bleeding has stopped. If there is still any oozing, insert more sutures until the vagina is dry. Do not rely on a pack to stop bleeding.</p>
---	---

(2) FOLEY CATHETER: Most surgeons prefer to tape it to the supra-pubic region to avoid any tension on it so there is no pull on the balloon and the repair. It helps to place a layer of adhesive strapping on the skin under the catheter, then lay the catheter down and put a second layer over the catheter.

!Tip! It is a good idea to leave a gap or “mesentery” of tape between the skin of the abdominal wall and the catheter (Fig. 1.30a). This helps avoid kinking of the catheter. It also secures the catheter better as the tape goes around the whole circumference of the catheter. Some surgeons tape the Foley to the leg but this will lead to pulling on the catheter as she walks.

!Tip! In addition to strapping, if a fistula involves the urethra, it is a good idea to fix the Foley catheter with a suture to the skin suprapubically.

(3) URETERIC CATHETERS: During the operation, make sure these are fixed securely with sutures to the suprapubic skin. It can be disastrous if these come out prematurely. In addition, at the end of the operation, secure them to the Foley catheter with three ties around the ureteric and Foley as in Fig. 1.30b.

Most ureteric catheters come with a connection piece that allows:

- An infusion set to be connected using the cannula end (of the infusion set). The other end of the infusion set can be put into a bucket (after the drip chamber has been cut off and the roller clamp removed) or an empty bottle/ infusion bag.
- The barrel of a 2-5 ml syringe to be connected. The end of a urine bag can then be inserted into this.
- Use the same tubing which connects to the Foley catheter but cut the tip off it. By dilating the tubing slightly, it will usually connect to the connection piece.
- Special connecting tubings for ureteric catheters are available (Angiotech Ref: 404017030).

Do not pass the ureteric catheters into the Foley by making a small opening just above where it is joined to the collecting tubing. This inevitably leads to leaking.

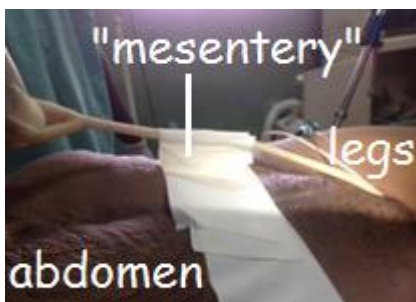

Fig. 1.30a: Shows the catheter taped suprapubically. Note the “mesentery” with a gap between the catheter and the skin.

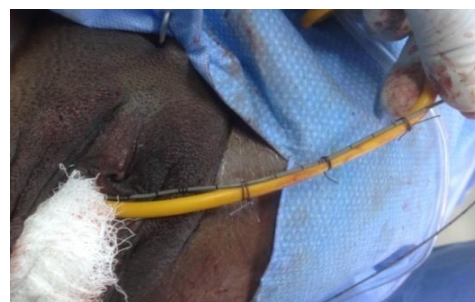

Fig. 1.30b: Ureteric catheters tied to the Foley catheter at three points..

FINAL CHECKS

The good work of the operation can be undone if you do not check the following before the patient leaves the operating table.


- Is the Foley catheter properly secured and was the balloon inflated?
- Are the ureteric catheters secured? This will avoid a lot of problems later so take time to do it properly.
- Always check that urine is draining from all catheters immediately after surgery before you leave the patient. If no urine is draining: (a) Inject 10 ml saline into Foley catheter: if this does not come back freely

when you inject, suspect that the catheter is not in the correct place i.e. not in the bladder. Recheck. (b) If the flush test is okay, increase the intravenous fluids until flow is seen. Do not hesitate to give Frusemide IV.

BLEEDING DURING FISTULA SURGERY

With large fistulas, excessive bleeding during surgery is a common problem (especially if they are soft and not scarred), and it can be easy to ignore it as you are focused on closing the fistula. As blood supplies are limited in most settings, you have to take steps to reduce or stop the bleeding.

Venous bleeding is the most common type. If you cannot easily suture the bleeding area, try the following: Pack the lateral para-vesical spaces or any bleeding areas with part of a vaginal pack or small gauze swabs but take note of how many you have inserted as it would be easy to leave them behind. You can usually continue operating while these are in place. Soak the pack with diluted adrenaline (same concentration as for infiltration). You may have to accept blood loss that will only stop when you close the vagina. It is better to operate a bit faster than waste time trying to clamp bleeders that are difficult to catch.

	If bleeding increases during the operation, always look carefully for an arterial bleeder which may be hidden behind a flap of vagina. Do not assume that the bleeding is venous and that it will stop when you close the vagina.
---	---

Arterial bleeding: If it occurs apply artery forceps or, if the bleeder is a long way in, use long artery forceps. Then suture the bleeder. Alternative options to deal with the bleeder are:

- Cauterize the artery or just leave an artery forceps on for 10 minutes. This is sufficient for small arteries. If it is a large artery, suture it at once. If you fail to stop the bleeding, leave the clamp on for 30 minutes before you try again to stitch it. It may be possible to continue with the repair in the meantime.
- Deep figure of eight sutures are useful laterally (near the ureters) if you cannot clamp the bleeder. If you apply a figure of 8 suture for bleeding, leave the ends a bit long in case there is recurrent bleeding.
- Pack with Surgicel ® or apply Floseal ®. If all else fails, you would have to pack the vagina very tightly and stitch in the pack by stitching the labia together.

SUMMARY OF KEY STEPS	SAFETY CHECKS
(1) Expose and inject vasoconstrictor. Rule out stones and ensure only one fistula.	Check for ureters and catheterize.
(2) Incise and dissect vagina off to expose pubo-cervical fascia and bladder. Do distal, proximal and lateral dissection. Excise all scarred tissue around the fistula.	Protect ureters during dissection.
(3) Close bladder (tension-free) starting at each angle. Then place the lateral and central sutures interrupted every 3-4 mm.	Protect ureters. Pass Foley catheter and do dye test.
(4) Intermediate layer if indicated.	
(5) Close vagina and pack.	Check haemostasis.

SUMMARY OF WHAT THE SURGEON’S HANDS ARE DOING DURING VVF REPAIR		
	<i>Left-hand</i>	<i>Right-hand</i>
(1) Vaginal incision	Steady vagina with dissecting forceps.	Holds knife as you incise.
(2) Dissecting vagina off bladder	Holds vaginal edges with dissecting forceps. Your assistant holds the bladder or vagina up with Allis.	Holds scissors as you dissect.
(3) As you look for the ureters	Holds a metal catheter to stretch bladder wall inside.	Holds a suction tip.
(4) As you trim the bladder edges	Holds the bladder edge with dissecting forceps.	Holds scissors.
(5) Closing bladder	(a) <i>Distal bladder/ urethra:</i> steadies it with dissecting forceps. (b) <i>Proximal bladder:</i> Holds the bladder edge with dissecting forceps or Allis.	Holds the needle holder.

CHAPTER 2

JUXTA-URETHRAL AND LARGE FISTULAS INVOLVING THE URETHRA

Section 2.1: Non-circumferential
Section 2.2: Circumferential 3/4 and 4/4 without significant gap
Section 2.3: Circumferential 4/4 defect with significant gap: circumferential dissection
Section 2.4: Overcoming size discrepancy and different ways of closing large fistulas

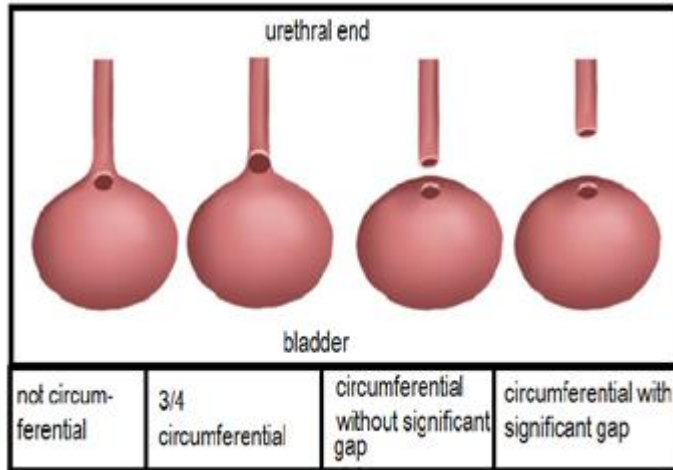


Fig. 2.1: This shows the different types of juxta-urethral fistulas.

In juxta-urethral fistulas, the fistula involves the proximal urethra and the distal bladder (See Fig. 2.1 and 2.2). They can either be:

- (a) *Non-circumferential*: involves posterior ± lateral wall: See example Fig. 2.3a
- (b) *3/4 circumferential*: involves the posterior + lateral ± part of anterior wall.
- (c) *4/4 circumferential*: involves the posterior, lateral and complete anterior wall i.e. the urethra is completely transected. These can be subdivided into those without a significant gap and those with a significant gap (Fig. 2.3b).

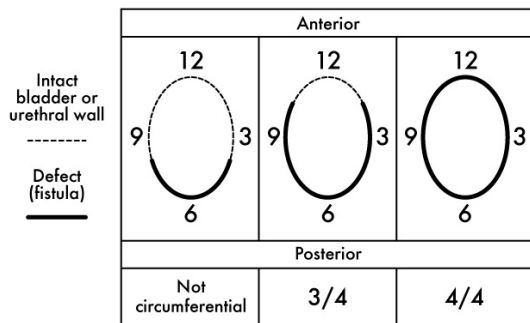


Fig. 2.2: The circle represents the urethra or bladder wall – a cross-section at the level of the fistula. The thin line is the remaining intact bladder or urethral wall. The bold line is the defect (fistula).

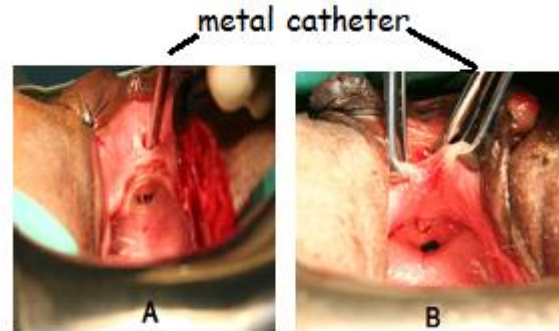


Fig. 2.3a: Shows a non-circumferential juxta-urethral fistula. Fig. 2.3b: Shows a circumferential defect where you can see the urethral end (as shown by the metal catheter) is separate from the bladder opening.

During repair:

- (a) *Not circumferential*: repair starts lateral to medial on the posterior wall.
- (b) *Circumferential 3/4 and 4/4*: repair starts first medial to lateral (12 o'clock to 9 or 3 o'clock) on the anterior wall; then lateral to medial (9 or 3 o'clock to 6 o'clock) on the posterior wall.

(2.1) JUXTA-URETHRAL FISTULAS: NON-CIRCUMFERENTIAL

The distal dissection and closure is more difficult than for most fistulas so the following tips are needed:

(a) Dissection-distal lateral

Make the lateral incisions and the incision around the fistula in the routine manner as described in chapter 1 and shown in Fig. 2.4a.

⚠ Top Tip! It may be difficult to get access to make the distal incision. In this case, (after the lateral incisions are made but before the distal incision), place the Allis forceps on the areas marked X in Fig. 2.4a and pull it up. Using the scissors, cut under the vagina by pushing the sharp tips of the curved scissors beneath the vaginal skin under the Allis forceps so that the area X is mobilized upwards. Once the vagina is freed up here, it

is then much easier to make the central part of the distal incision (distal to the fistula/ urethral opening) see Fig. 2.4 b+c .

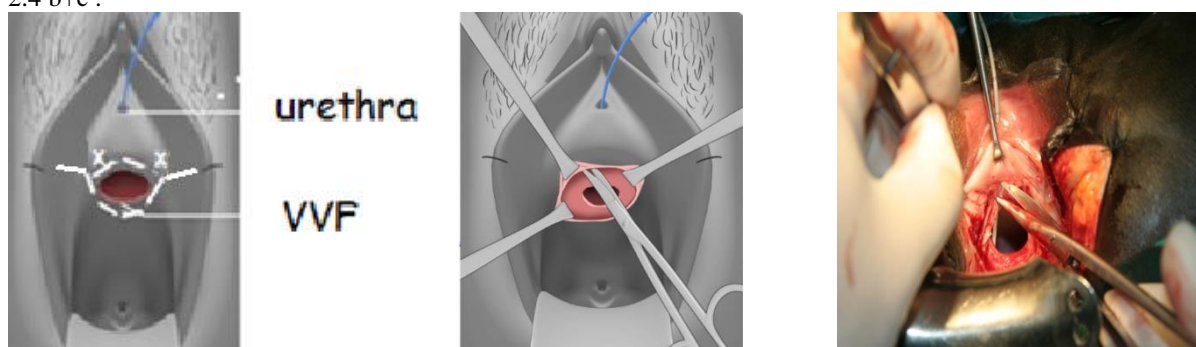


Fig. 2.4a: Shows the area marked X which is formed by the initial incisions.

Figs 2.4 b+c: Show the X area being dissected by pulling up on an Allis forceps. Note the scissors is aiming laterally towards the patient's shoulder. The Allis forceps in the photograph would be better placed just above where you will cut as in diagram b.

(b) Dissection-distal central

After doing the distal lateral dissection, this is the next step. Use sharp dissection with a knife or scissors.

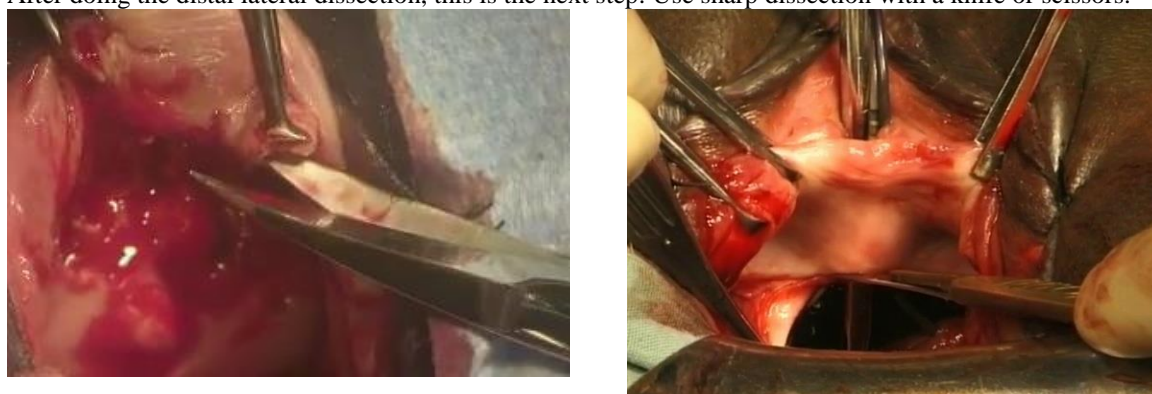

Fig. 2.4d: Shows the distal flap being mobilized by inserting one blade of scissors between the vagina and urethra and then cutting.

Fig. 2.4e: Shows the metal catheter in the urethra. In this case, the incision is made with the scalpel.

! Tip! A neat trick (Fig. 2.4d) when cutting or mobilizing the distal vagina: get one blade of the scissors flat in between the vagina and urethra laterally on one side and then turn the scissors horizontal. Cut to separate the vagina off the urethra. This is not always possible and if the tissues are very scarred it is easier to mobilize the central part with a knife instead. The urethra can be very short here, so be sure to stay superficial in the vaginal wall dissection.

! Tip! If you have difficulty with mobilizing the distal vagina, extend the lateral incisions. When dissecting near the urethra, stay close to the vaginal skin. Otherwise, you will end up with a very thin urethral wall to anastomose to the bladder, and the sutures in the urethra will tear the tissues.

! Tip! Some operators like to place a metal catheter in the urethra to help exposure (Fig. 2.4e). By pushing this forward, it can help display the tissue to be cut. However, it can also reduce the mobility of the tissues, so it may be necessary to remove it at some stages. You can also put the metal catheter into the fistula to push forward the proximal wall or angles to improve the vision of the corners.

! Top Tip! After all the dissection is done, if you still cannot see the lateral angles of the fistula clearly, it means you need to mobilize more laterally. You must see the angle before you close it. If you still fail to see the angle clearly this means you are dealing with a circumferential defect and need to do circumferential dissection.

(c) Closure-angles

I would often take four bites when doing a difficult angle as shown in Fig. 2.5a. This is repeated on the opposite angle.

- **Bite 1:** When closing the fistula, the distal bite of the angle suture first goes into the periosteum (or the tissue over the bone) of the inner surface of the inferior pubic ramus. (If you think of the pelvic outlet as a

circle, these are placed at 11 o'clock on the right and 1 o'clock on the left). This gives a very good hold for the suture. A useful way of checking that your stitch has gone deep enough into the periosteum and to confirm you have a strong hold (purchase) of periosteal or peri-urethral tissue, is to pull on both ends of the stitch after you have gone through the periosteum and see if the patient moves as you pull on it! When taking the bite on the left side, try placing with a back-hand grip as this often gives a better approach.

- **Bite 2 + 3:** There is no problem with going into the urethral or bladder lumen if necessary to get good closure.
- The backhand grip is extremely useful for placing all or most of the sutures at or near the angle on the left side (See Appendix 2). Mount the needle facing your left and raise your elbow up in the air to do this.

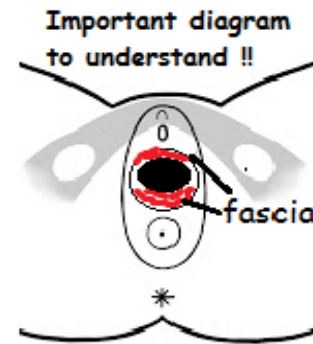
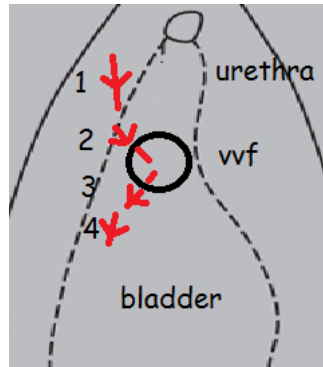
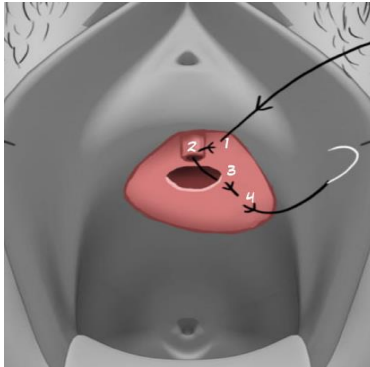


Fig. 2.5a: Shows the closure of a difficult angle.

- The first bite is well above the angle to get a good bite.
- The second bite goes into the urethral lumen (out to in) on the distal part of the angle.
- The third bite passes from in to out on the proximal (bladder) part of the angle.
- The fourth bite is proximal to the angle.

⚠ Top Tip! Using the 4-bite angle closure technique is useful for any difficult angle that involves the urethra.

Fig. 2.5b: When closing any fistula which involves the urethra, try to incorporate any fascia present (shown in red) on both distal and proximal ends of the fistula into the urethral + bladder closure to give extra strength.

- Distally take the fascia or, if the fascia is absent, bite onto the periosteum.
- Proximally take the fascia which usually has a shiny appearance.

⚠ Tip! If the angle of the fistula goes very lateral: (a) Make sure that the lateral dissection is sufficient. (b) Consider if circumferential dissection would help (see below). (c) If the angle is formed by a lateral tear of the bladder, suture directly as in Fig. 2.5c.

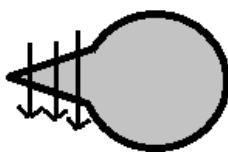
⚠ Top Tip! It is often a good idea to include the pubo-cervical fascia in the closure of the fistula as shown in Fig. 2.5b. Suture from:

- The distal fascia which is tightly connected to the urethra and para-urethral tissue. If the distal fascia is poor, takes good bites of the periosteum instead.
- To the bladder edge proximally (c) then bite the proximal fascia which is found between the bladder and vagina. In fact, some surgeons only pick up the fascia distally and proximally without picking up the urethra/ bladder as these are closely adherent to the fascia so should close as you approximate the fascia.

The advantages of doing this are:

- With the sutures mainly in the fascia, it means there is less risk of causing ischaemia to the urethra. This is particularly important when the urethra is short.
- It should improve the continence mechanism by correcting the defects in the endopelvic fascia which prevent it from functioning effectively.

CAUTION! Remember that the ureters run between the bladder wall and the pubocervical fascia so if your bites are too deep in the fascia proximally, you may catch the ureters.



⚠ Tip! Sometimes the angle/ defect in the bladder goes quite lateral i.e. it is like a lateral tear in the bladder. In this case, just close the angle first with 1-3 simple sutures working from lateral to medial. Once this lateral part is closed, then you may later consider using the suture in Fig. 2.5a.


Fig. 2.5c: Shows a lateral extension of the fistula being closed first.

(d) Closure-central part

- When the fistula is almost closed, it may help to place all the central sutures first with the metal catheter in place and leave them on artery forceps. After they are all placed, they can be tied after replacing the metal catheter with a Foley catheter.
- It may also be very helpful to use the metal catheter (inserted into the urethra and bladder) to stretch the urethral and bladder walls as you place the stitches.

If the urethra is very fragile: If you are about to put a suture through the urethra, feel the thickness of the urethra by pressing against the metal catheter in the urethra. If the urethra feels very thin, then it is better to take bites out more laterally and only put 1-2 sutures in the urethra itself. Also, you may want to consider using a smaller needle here to avoid more damage to an already compromised urethra. If you see after placing a suture that the urethra is likely to tear (i.e. small hole occurs after inserting the needle or as you begin to tie the suture), it is better not to tie the suture. Take the suture out and place a suture more laterally where the urethra is stronger.

⚠️ Top Tip! If the urethra is very fragile and tears as you place or tie a suture, the best way to deal with this is to close the defect with the help of a muscle patch. Usually, the para-urethral (bulbocavernous) muscle is easily accessible. You may even consider placing a Martius flap over the repair.



While in theory, in order to lengthen the urethra and hopefully reduce the risk of stress incontinence, closing a juxta-urethral fistula longitudinally seems a good idea, in practice this usually creates too much tension and risks stenosis. There is a real risk of a stricture developing later which is difficult to deal with. Therefore there is no benefit to the increased length gained in the urethra. For this reason, transverse closure is a better idea in most cases. Note: This applies to juxta-urethral fistulas rather than pure urethral fistulas which usually have to be closed longitudinally(as seen in Fig. 2.8).

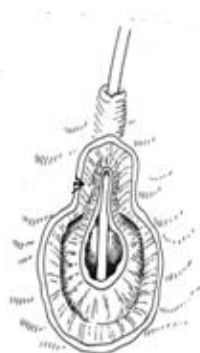


Fig. 2.6a: Shows a torn urethra + VVF.

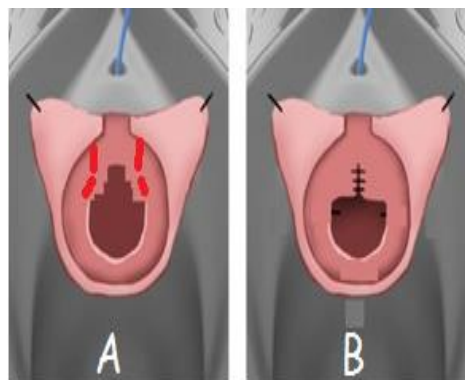


Fig. 2.6b: Shows two incisions (red) made to mobilize the tissues to lengthen the urethra.

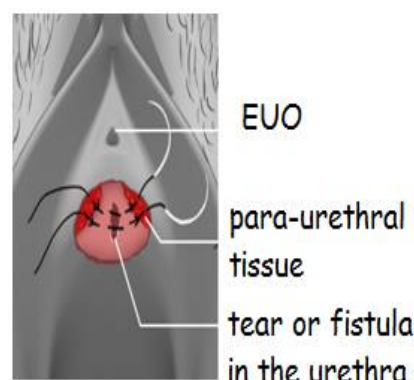


Fig. 2.7: Show the para-urethral tissue being used in closure of urethral tear.

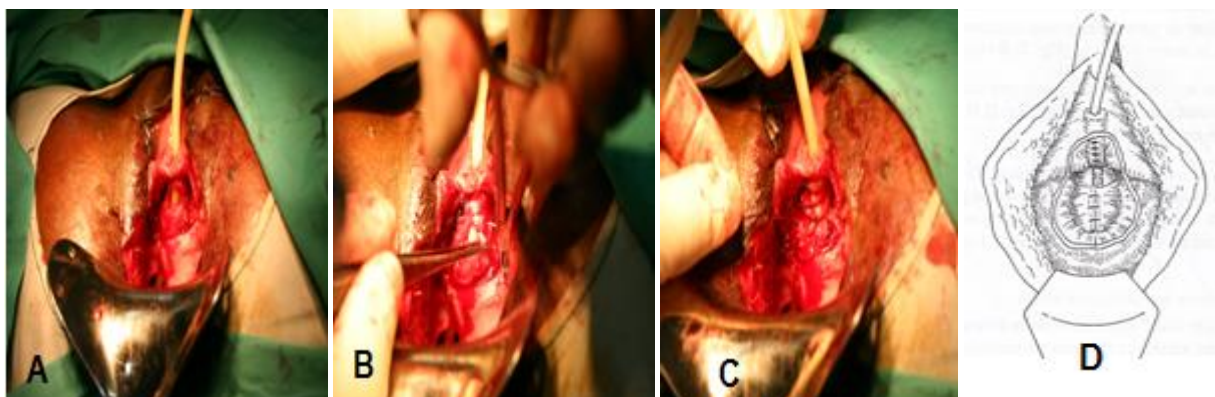


Fig. 2.8: These three photographs and one diagram show longitudinal closure of a urethral fistula. A shows the unrepaired urethral fistula. In B the longitudinal (side-to-side) repair is being started with the edges being grasped with dissecting forceps. In C and D the repair is completed with interrupted sutures.

If the urethra is very short or already torn in the midline: This usually only occurs with a large defect. If the urethra is less than 1-2 cm, it is often possible to lengthen it to allow it to be re-anastomosed to the bladder.

- (a) Make two vertical incisions (Fig. 2.6b) on either side (2.5-3 cm apart) to mobilize the tissues. These allow the urethral tissue to come together. These are similar to the incisions made for a neourethra in section 4.1. The incisions are made deep and just medial to the ischiopubic ramus bone.
- (b) If the tissues are very fragile: If you just try to stitch the urethra, the stitches will pull through. It is better to pick up the pillars of para-urethral tissue on either side (bulbocavernosus) with Allis forceps and mobilize (see Fig. 2.7). The tissue is found just beneath the skin on either side lateral to the urethra. Stitch from para-urethral tissue to the urethra and then the para-urethral tissue on the other side (Fig. 2.7). Using the para-urethral tissue prevents the stitches cutting through.

If there is a small fistula confined to the urethra which usually occurs after a previous repair, then you usually need to use the para-urethral tissue on either side to help in the closure of the fistula as in Fig. 2.7.

(2.2) JUXTA-URETHRAL: INCOMPLETE (3/4) AND COMPLETE (4/4) CIRCUMFERENTIAL DEFECT WITHOUT SIGNIFICANT GAP

- (a) **3/4 Defects:** The defect extends more laterally than that in section 2.1 i.e. involves the posterior, lateral and part of the anterior walls. These are more common than complete (4/4) defects and usually there is a bridge of tissue on the anterior bladder joining the urethra and the bladder.
- (b) **4/4 Defects without significant gap:** Even though they are circumferential, if there is no difficulty bringing the tissues together, there is no need to do a full circumferential dissection provided there is not much scarring or stenosis at the junction of the urethra and bladder.

With both of these defects, the difference from non-circumferential defects is that the anterior part of the fistula has to be closed first.

! Tip! To avoid confusion, remember that the anterior urethra (12 o'clock in diagrams) and the anterior bladder (12 o'clock) are adjacent to the pubic bone.

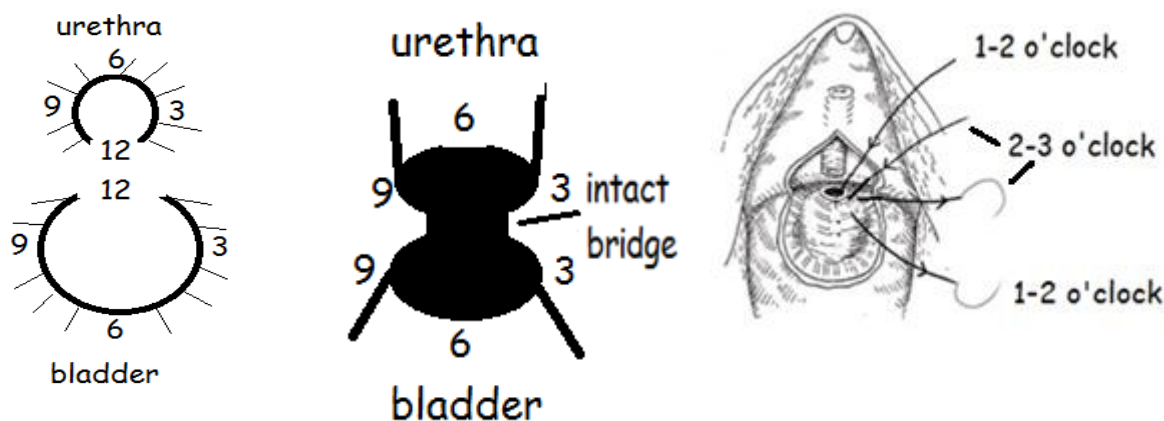


Fig. 2.9a: Imagine the edges of the defect in the bladder and urethra (dark line - almost a circle) to be a clock face with the intact anterior bridge between 11 and 1 o'clock. Start suturing on the anterior aspect (1-2 o'clock on left or 10-11 o'clock on right) coming round the defect to close it and working each side in turn until you reach 6 o'clock on the defect.

Fig. 2.9b: Shows the first (1-2 o'clock) and second (2-3 o'clock) stitch being inserted antero-laterally for 3/4 defects.

Closure: To close the anterior part of the defect, start medially to lateral on the anterior wall i.e. start where the tissue bridge ends. The distal part of the stitch bites into periosteum and para-urethral tissue. The proximal part of the stitch bites the bladder more anteriorly than laterally.

- (1) The first stitch is inserted at 1-2 o'clock on left and at 11-10 o'clock on right (see Fig. 2.9b). You may sometimes use the four-bite angle stitch when doing these as in Fig. 2.5a if this gives a secure closure.
- (2) A second stitch is inserted a little more laterally at 2-3 o'clock on left or 10-9 o'clock on right (see Fig. 2.9b). Usually, it only takes 1-2 stitches to close the anterior defect.
- (3) Once the anterior part is closed, start laterally at 3 and 9 o'clock to close the lateral and posterior defect as usual. Often the 4-bite angle stitch as in Fig. 2.5a is useful.

! Tip! When closing the bladder, remember to hold the lateral proximal bladder with Allis forceps close to the angle and pull it medially to see the angles clearly (see Fig. 1.23a+b). Otherwise, you will leave gaps.

! Tip! If you are struggling to close the angles in these defects and you have mobilized well laterally, then it is often easier to do a full circumferential dissection as in section 2.3. This will allow a better closure of the angles.

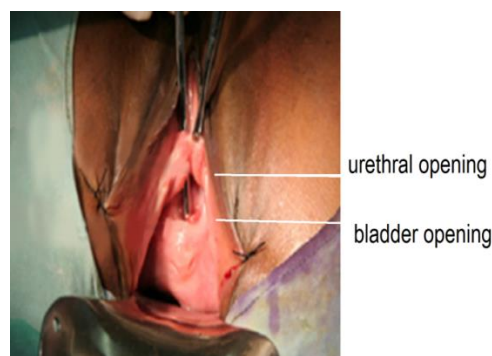
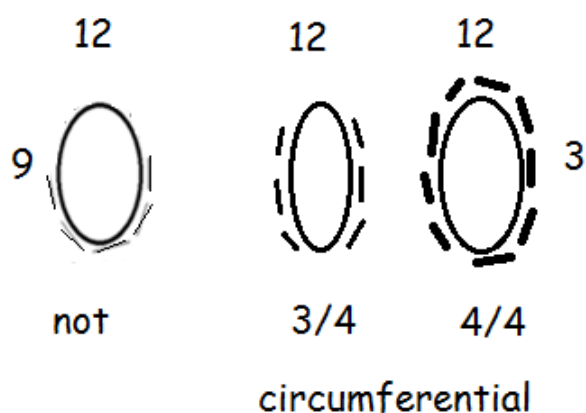


Fig. 2.10: Shows where the sutures are inserted in the different defects.

Fig 2.11: Shows a complete circumferential defect with a wide (3-4 cm) gap.

Dissection: In each of the above defects, you follow the previous dissection steps (see section 2.1).

(2.3) JUXTA-URETHRAL COMPLETE (4/4) CIRCUMFERENTIAL DEFECT WITH SIGNIFICANT GAP: CIRCUMFERENTIAL DISSECTION

Almost all circumferential fistulas involve the urethra and they occur against the posterior pubic symphysis. There is no connection between the urethra and the bladder i.e. there is separation of the urethra from the bladder with a defect posteriorly, laterally and anteriorly, from ischaemic tissue loss. In this case, as there is a significant gap, an end-to-end anastomosis must be performed between the bladder and the urethra.

- The proximal end (bladder opening) is usually obvious on vaginal examination.
- The distal end (urethral opening) is more difficult to see as it retracts behind the pubic symphysis. It is often stenotic and it may have to be opened and/or dilated.

It is important to recognize circumferential defects because if you only see the obvious defect (which is the bladder opening), you will not close the defect properly. You may end up closing the bladder and causing obstruction. The indications for circumferential dissection are:

- If there is a large gap > 1 cm between the proximal end of the urethra and the bladder. The aim is to bring the bladder down to the urethra without tension.
- If it will make it easier to close the angles of the fistula more securely.
- If there is a lot of scar tissue or if there is a stricture of the urethral end: the circumferential dissection often helps to remove it.

The main advantages of circumferential dissection are:

- It greatly increases the mobility of the bladder and a difficult repair becomes easier. If there is any difficulty in bringing the bladder and urethra together, then it is usually worth doing.
- It may reduce the incidence of stress incontinence.

If the urethra is stenosed: The urethral end of the fistula is commonly blocked and can be unblocked by:

- (a) Using an artery forceps: Place it into the urethral meatus with the curve and tip facing upwards (towards the clitoris). Then as you steady the forceps with your left hand, give a sharp smack on the artery forceps with the palm of your right hand. Surprisingly this does not usually cause false passages.
- (b) Pushing the metal catheter (with the curve facing upwards) through. Place a finger at the proximal end of the blocked urethra to make sure the catheter only goes through the urethra.
- (c) If there is still difficulty: use urethral or Hegar dilators.
- (d) You can make a small incision with a scalpel in the urethral end of the fistula at 12 o'clock position as you stretch the urethra with the metal catheter.

! Tip! When dilating the urethra, stay close to the bone to avoid perforating through the (posterior) urethral wall.

! Top Tip! After circumferential dissection (see below), it is a good idea to cut out any stenotic area of the urethra or bladder on the assumption that if you tear and dilate scarred tissue it will just re-stenose. Cutting back to healthy tissue should give a better result. (The Foley catheter should pass in with ease.) Otherwise, these patients will be at high risk of urethral stenosis later (see section 6.3).

- Usually, just cut off the stenosed tip of the proximal end of the urethra. If that is not sufficient, make a small incision at 12 o'clock in the urethral end ("spatulation") until the catheter passes without resistance. Usually, you only need an incision of a few millimetres.
- Occasionally the bladder end of the fistula is also stenosed and any scar tissue should be excised.

CIRCUMFERENTIAL DISSECTION AND REPAIR: This needs the exaggerated lithotomy position and very steep head down tilt.

Incision: Either:(a) Do all the usual incisions and dissection as for any fistula and then do the extra incision or(b) Do the distal dissection and then make the extra incision for circumferential dissection. The proximal and lateral dissection may be done after the extra incision. (Reflect the distal vagina off the urethra first and suture it out of the way, which helps to bring the fistula into view.) By doing the extra incision early, this brings the bladder down which makes it easier to do the proximal and lateral dissection.

Extra incision: Make a transverse incision (Fig. 2.12a) between the bladder and the urethra. You can then mobilize the anterior bladder off the back of the pubic symphysis allowing it to be sutured to the urethra with much less tension.

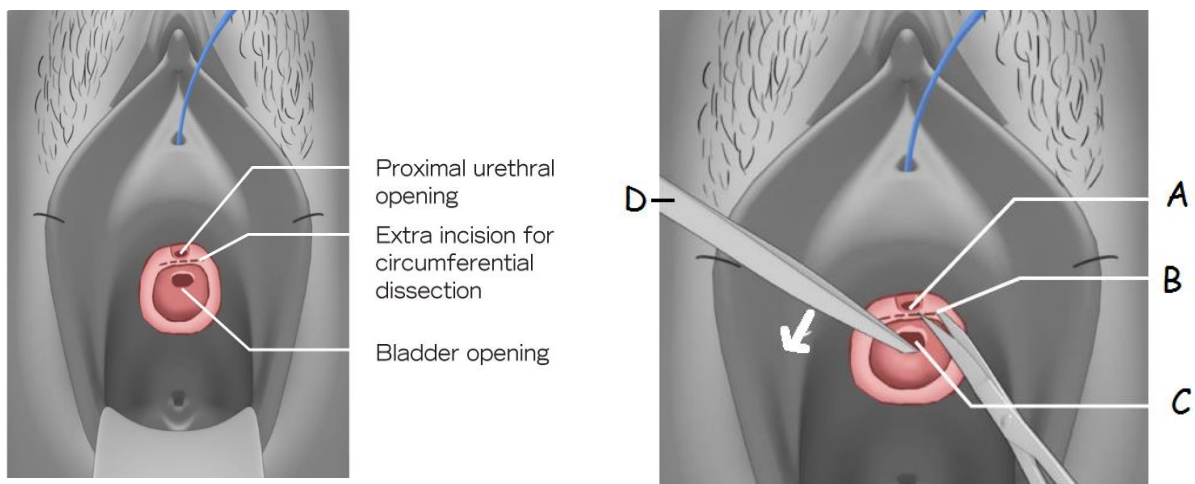


Fig. 2.12a: Shows where the extra incision is made anteriorly between the bladder and the urethra.

Fig. 2.12b: The dissecting forceps/pickups (D) are used to stretch the bladder proximally as you make the extra incision(B) and dissect the bladder off the pubic bone. A = proximal urethra C = bladder opening.

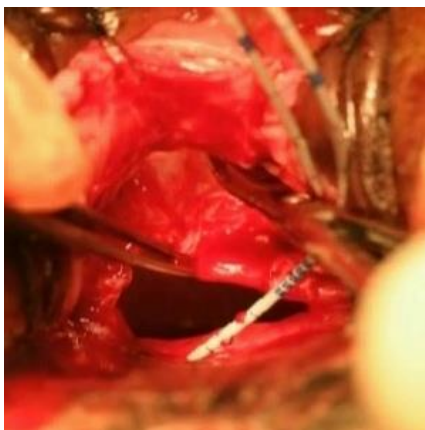


Fig. 2.13: Shows dissection of the anterior bladder off the pubic bone.

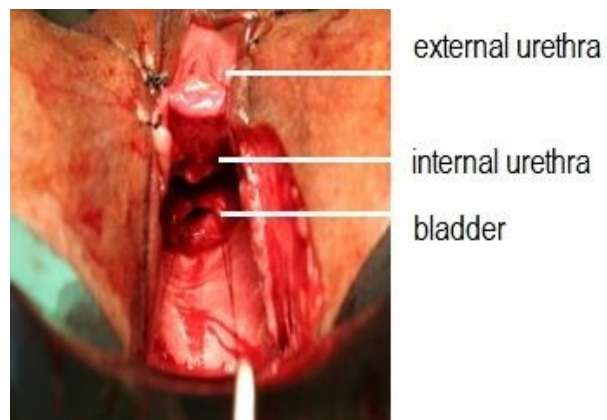



Fig. 2.14: Shows the bladder after circumferential dissection ready for end-to-end anastomosis to the urethra.

- Put the toothed dissecting forceps on the proximal edge of the bladder to stretch it proximally as shown in Fig. 2.12b. Another option is to grasp the edge of the bladder as high as possible with Allis or dissecting forceps and pull down on these (see Fig. 2.13). Now make the extra transverse incision with a knife or scissors. When making the extra (transverse) incision, stay close to the symphysis to avoid injuring the bladder. It is often easier to use scissors in dissection rather than the knife. Your left-hand stretches the bladder; your right-hand does sharp dissection with scissors/knife (Fig. 2.13).
- Mobilize the bladder well by sharp and blunt dissection to get into the retropubic space. There is usually a lot of scar tissue to be released. Sharp scissors are used for this.
- Once through the scar tissue, there will be a very clear palpable and visual release of the anterior bladder from the posterior pubis. You will see para-vesical fatty tissue and small vessels. It is critical to keep the dissection close to the pubis to avoid tearing or cutting of the thin anterior bladder.
- Redundant scar tissue at either the bladder or the urethra side of the fistula should be excised before anastomosing the bladder to the urethra. You should now see the fistula opening of the bladder and the proximal urethra as shown in Fig. 2.14.

! Tip! The ureters often have to be catheterized during circumferential dissection. However, the catheters cannot be pulled through the urethra until the anterior layer of the fistula is closed. Because the catheters are not fixed, they will often come out during dissection and may be difficult to re-insert. One way to fix them temporarily is to pass the catheters under a small fold of the drapes using a towel clip to keep them in place. Alternatively, they may be placed under the sutures used to retract the labia minora.

Closure - Anterior row (11, 12 + 1 o'clock): The anterior wall of the bladder is stitched/ re-attached to the anterior wall of the urethra i.e. 12 o'clock on the urethra is sutured to 12 o'clock on the bladder. This is best done by placing three interrupted sutures at 12, 11 and 1 o'clock before tying any of them (Fig. 2.15a). The distal bite of each stitch goes mainly into the periosteum beside the urethra rather than through the urethra because the urethra is fixed to the symphysis. However, part of the bite may go through the urethra. A 2/0 Vicryl J602H 5/8 needle is ideal as it is strong enough to go through the periosteum (see Fig. 2.17b).

	The distal bites go mainly into the periosteum beside the urethra rather than into the urethra itself. If you only go into the urethra, you will tear it. By going into the periosteum beside the urethra it brings the bladder and the urethra together. Check with the metal catheter that you do not occlude the urethra after you have placed the stitches.
---	---

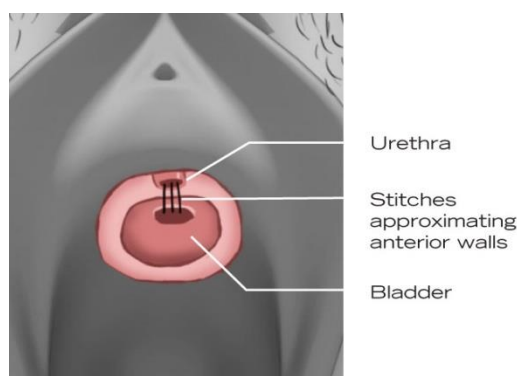


Fig. 2.15a: Shows the anterior layer of sutures in place.

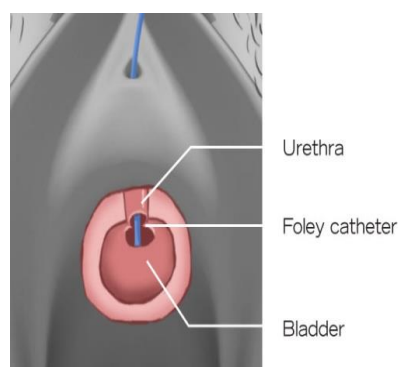


Fig. 2.15b: Shows the bladder and urethra approximated after the sutures have been tied.

- The proximal bite of each stitch is through the bladder. Take a good size bite but avoid the mucosa if possible.
- The first suture is placed at 12 o'clock picking up the anterior urethra and the pubic symphysis and then the anterior bladder wall (Fig. 2.16, 2.17a).
- The other sutures are placed at 11 and 1 o'clock.
- Check with the metal catheter after each of these bites that the urethra/ proximal bladder is not blocked.

! Tip! It is often easiest to place the distal bite of the 12 o'clock stitch in a more transverse direction rather than vertical. To do this, direct the suture from the patient's right to left through the periosteum at 12 o'clock with a forehead throw of the needle.

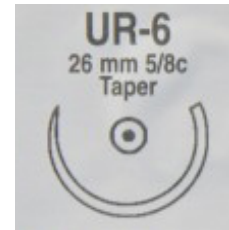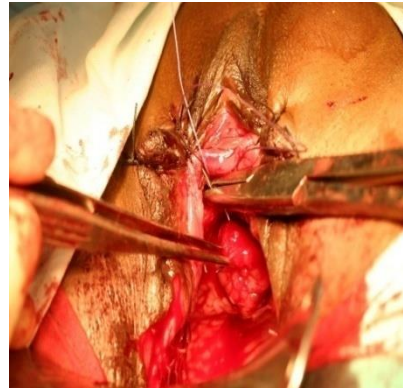
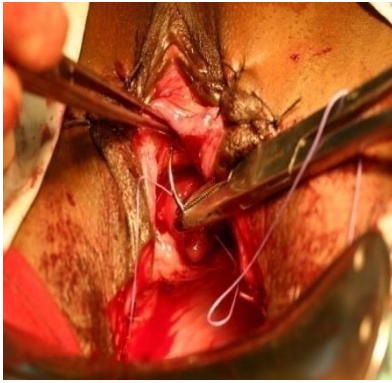


Fig 2.17b: Shows the UR 6 needle which is particularly useful for all the anterior and lateral sutures.

Fig.2.16: Shows the 12 o'clock stitch being inserted into the periosteum.


Fig. 2.17a: Shows the 12 o'clock suture now being inserted into the anterior bladder.

Closure –antero-laterally (10 + 2 o'clock; 9 + 3 o'clock): Once the anterior row is placed, then close laterally on each side.

- A suture is placed on each side at 10 + 2 o'clock. However, the distal bites of these are placed more from the antero-lateral aspect of the urethra rather than trying to get bites of the periosteum i.e. these bites include mainly para-urethral tissue and the side of the urethra.
- Place sutures at 9 and 3 o'clock (you do not usually need to use the four bite suture as in Fig. 2.5a to do this as the lateral part of the fistula should be easy to close after circumferential dissection). The distal bites may have to be through the periosteum laterally if there is no other tissue available i.e. stitch bladder to bone.

Closure- posteriorly (8, 7, 6, 5, and 4 o'clock): The posterior row closure is performed as usual with any VVF with stitches at 8, 7, 6, 5, and 4 o'clock.

Note: Most of the distal sutures are placed in the periosteum and para-urethral tissue rather than the urethra. Not all repairs will require 12 sutures as shown in Fig. 2.18b. Aim for the minimum number required to close the defect.

	<p>It is important to place the urethral catheter before you finish the repair. Otherwise, if there is difficulty inserting it later, you may pass the catheter through the anterior wall of the repair so it ends up retropubically, which can be difficult to recognise. It is a good idea to have the metal catheter in place as you insert (but do not tie) the central 3-4 sutures. Then remove the metal catheter and insert the Foley catheter. Then tie all the central sutures. This prevents the Foley catheter from being caught by sutures.</p>
---	---

!Tip! Occasionally with bad circumferential fistulas, there is an upward tear in the anterior bladder when it is dissected off the pubic bone (Fig. 2.18c). To reach the apex, you often need to 'walk around' using two Allis forceps. Start laterally on one side and work your way around anteriorly until you reach the apex. Once mobilized, it is better to close this tear separately before doing the rest of the circumferential repair. It is easiest to do this in 1-2 continuous layers.

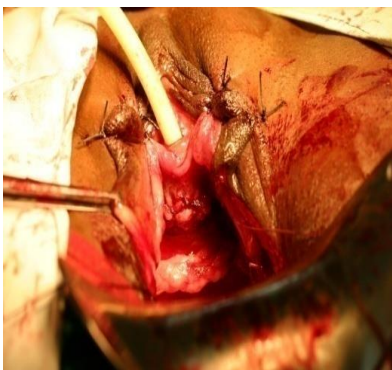

Fig. 2.18a: The repair is completed by closing the posterior layer.

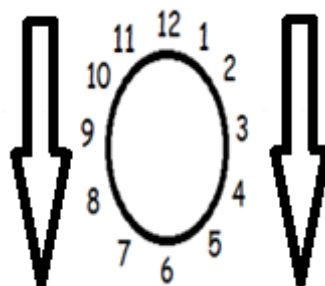


Fig. 2.18b: This summarises where the sutures are placed looking at the **bladder** aspect of the fistula.

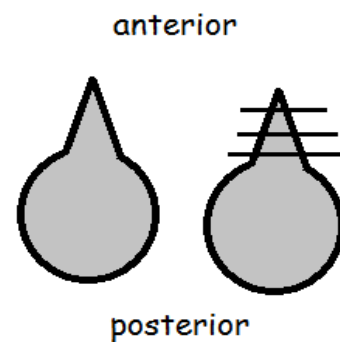


Fig. 2.18c: This shows an extension or tear of the anterior bladder wall which is closed separately before the circumferential repair.

(2.4) OVERCOMING SIZE DISCREPANCY AND WAYS OF CLOSING LARGE FISTULAS

Most large defects are circumferential, involve the urethra and need full mobilization on the bladder side. The problems with most large fistulas are:

- i. The distal part (urethra) is narrower than the proximal part (bladder) as seen in Fig. 2.19a+b+c. This means you have to squeeze together (concertina) the sides of the bladder when stitching, which reduces bladder capacity.
- ii. During closure of the defect, it will mean a lot of sutures are placed in the para-urethral and urethral tissues distally. The typical situation is where you are faced with a large defect and a short urethra of only one centimetre. You may end up with a urethra that sloughs off due to ischaemia.
- iii. Closure tends to pull the ureters distally towards the urethra. It is thought that ureters placed immediately adjacent to the proximal urethra could contribute to incontinence after repair.

There are several ways to overcome the problems of width discrepancy:




Fig. 2.19a: Shows a juxta-urethral fistula where a normal size urethra needs to be joined to a wide bladder defect. Fig. 2.19b: A cross-section view of urethra and bladder as seen in Fig. 2.19a. The black represents the edges of defects in the bladder and urethra. Fig. 2.19c: Shows an example of a VVF with discrepancy.

(OPTION 1): TRANSVERSE APPROACH

This is the traditional approach with transverse closure but modified to try to avoid the above problems.

- Most of the distal lateral sutures are placed in the bone/periosteum and the distal fascia. Only a few central sutures go through the urethra or the fascia over the urethra.
- Then the proximal sutures are placed in the bladder and more especially the fascia overlying the bladder.

If you have done a circumferential repair after the anterior sutures of 12, 11 and 1 o'clock and 10 and 2 o'clock have been placed, in relation to Fig. 2.19e:

- Place the most lateral sutures (marked 1) at 3 and 9 o'clock.
- The next sutures (marked 2) are placed at 8+7 and 4+5 o'clock.
- Then do midline sutures (marked 3) at 6 o'clock.
- You may then place extra stitches in between these to make sure there is no mucosa protruding.

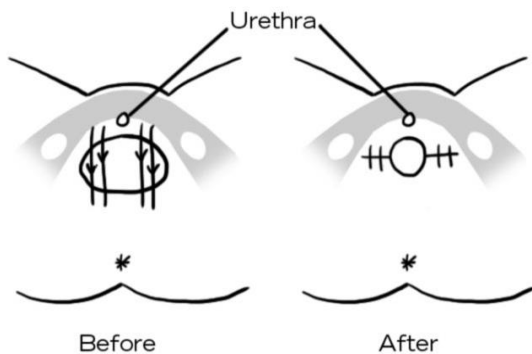


Fig. 2.19d: Shows diagrammatically how the bladder is reduced in size before joining to the urethra.

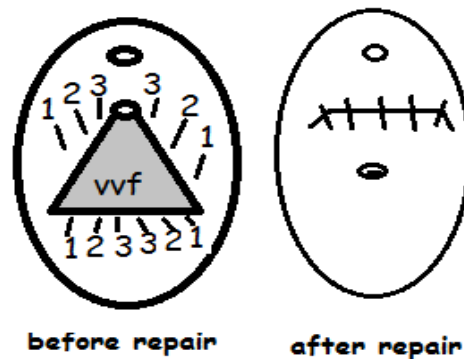


Fig. 2.19e: Shows the placement of the sutures.

During transverse closure, there are two main ways of overcoming the discrepancy:

- Take the distal bites vertical and the proximal bites more horizontal as in Fig. 2.19h.
- To close the sides of the defect (3+9 o'clock, 4+8 o'clock): for every one distal bite of the para-urethral tissue, take two proximal bites of the bladder which concertinas (squeezes together) the defect (Fig. 2.19 f+g). It may take several of these stitches to close the sides of the defect and there is a risk of making the bladder smaller using this method.
- Once the sides are closed, the central part of the fistula (7,6 + 5 o'clock) is closed by taking the distal bites vertically and the proximal bites more horizontally so that you end up with wider bites of the proximal edge as shown in Fig. 2.19h.

Tip! When trying to close a large defect transversely, it is a good idea to incorporate the fascia distally and proximally into the repair as shown in Fig. 2.5b. This is less likely to result in ischaemia of the distal end of the fistula.

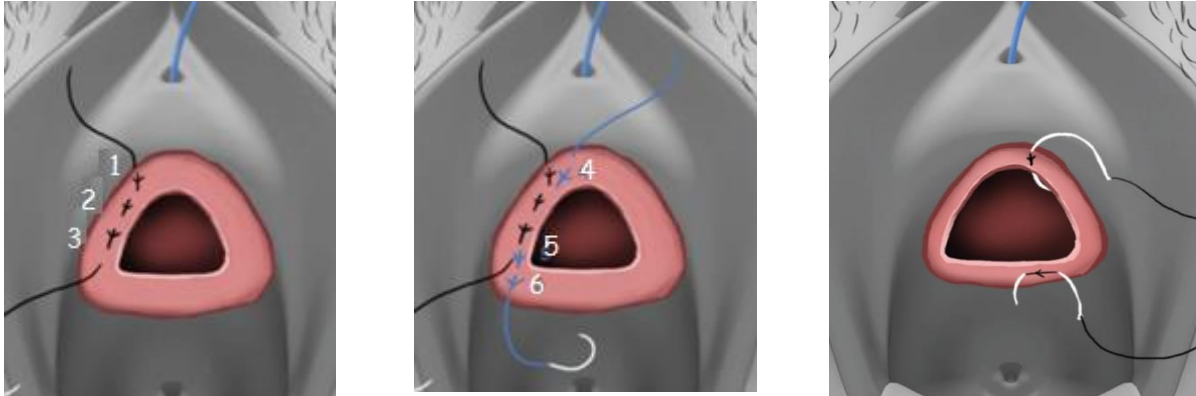


Fig. 2.19f: The first stitch is black with bites marked 1, 2 and 3.

Fig. 2.19g: The second stitch is blue with bites marked 4, 5 and 6.

Fig. 2.19h: The distal bites are taken vertically while the proximal bites are taken horizontally.

(OPTION 2): REDUCING THE BLADDER CIRCUMFERENCE BEFORE CLOSURE

(A) Formation of two legs followed by transverse closure: This is a very good way to manage very large defects.

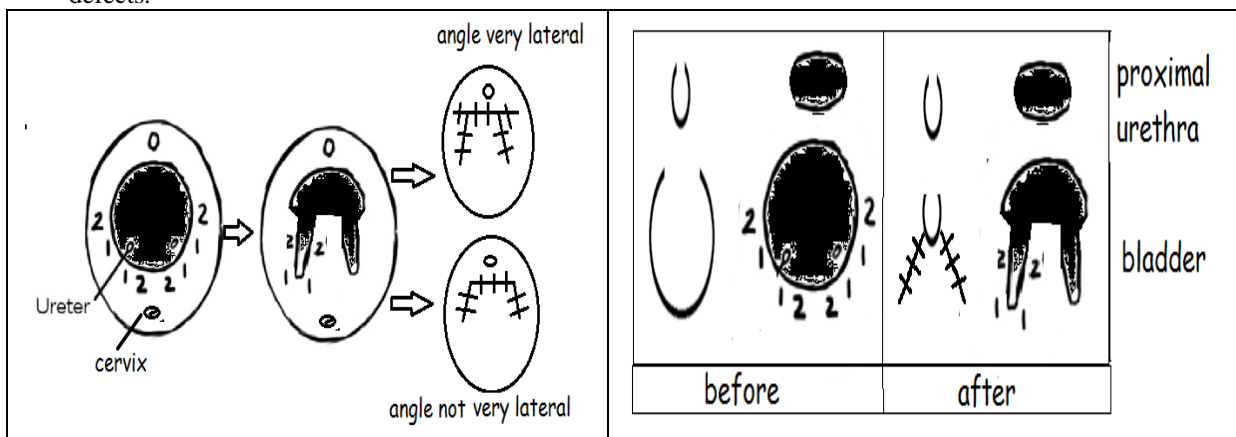
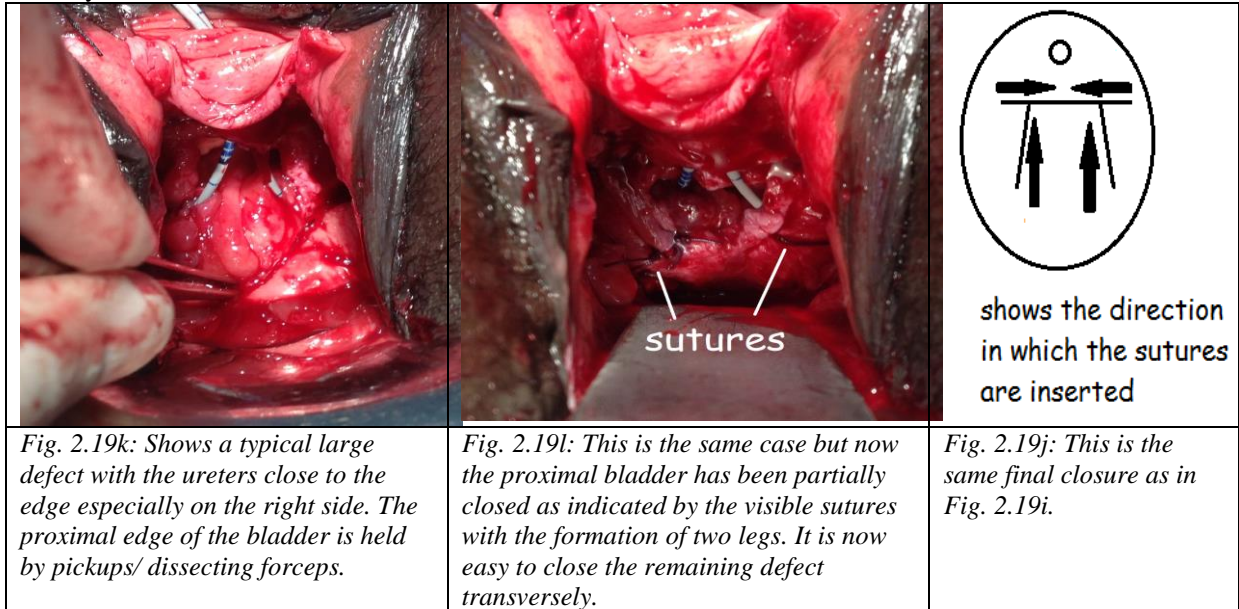


Fig. 2.19i: Shows the formation of two legs before the rest of the fistula is closed transversely. By reducing the size of the bladder defect, it is then easier to match it to the size of the urethral defect.

- If a circumferential dissection has been performed, then the sutures are inserted at 12, 1, 11, 2 and 10 o'clock.
- Legs closure is started laterally on each side close to the ureters by stitching the bladder to the bladder as in Fig. 2.19i. (Often both ureters are close to the edge or just outside of the bladder and need to be turned back into the bladder.) In the process of doing this, a leg is formed on either side. Usually, 3-4 sutures are required on both sides. It is usually safer to work on both sides simultaneously rather than completing one side and then doing the other. However, in some cases, you only need to make a leg on one side (Fig. 2.20 a+b).
- It is easiest to think of the bladder closure being performed in the line of the ureteric catheters as they travel distally towards the urethra. One of the advantages of this method is that it tends to keep the ureters in place rather than pulling them distally towards the urethral opening.

- The rest of the fistula is closed transversely (see Fig. 2.19j).
- On each side, at the junction of the urethra and the leg, it is a good idea to take a three bite stitch i.e. bite of the urethra, bite of the leg laterally and bite of the leg medially (see Fig. 2.20b + c).

! Tip! As you work distally on each side as you form the legs, watch that the distance between the two legs distally (width of the remaining open bladder) is sufficient to join to the urethra. Be careful not to go too far distally.



(B) Formation of one leg on one side followed by transverse closure: In some cases when the fistula is more to one side, it may only be necessary to form a leg on one side as shown in Fig. 2.20 a + b. The end result is similar to the formation of a T-junction (see step 3 chapter 1) although in a T-junction the leg is in the midline.

(C) Closure of bladder longitudinally: Occasionally it is possible to reduce the size of the bladder longitudinally so that the remaining defect is then joined to the urethra (see Fig. 2.20d). You can think of this as the formation of one leg in the midline. The T-junction of the urethra and the bladder in the midline will be closed with a mattress (preferred) or a triangular suture. The mattress stitch is inserted as the last suture when the defect is small. Note that this closure is essentially the same as in Fig. 1.20 d + e but starting in a reverse manner i.e. closing the leg of the bladder first.

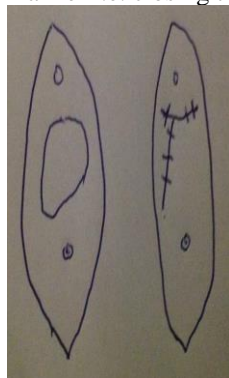


Fig. 2.20a: Shows legs closure performed on the right side only. The angle sutures distally were placed first before the leg was formed.

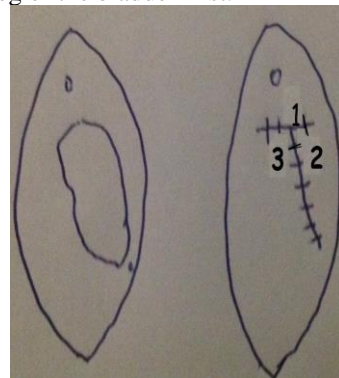


Fig. 2.20b: This is another example of one leg being formed on the left. The triangular suture at the junction of the leg with the urethra is marked in as 1, 2, and 3. This joins the distal part of the leg with the urethra.

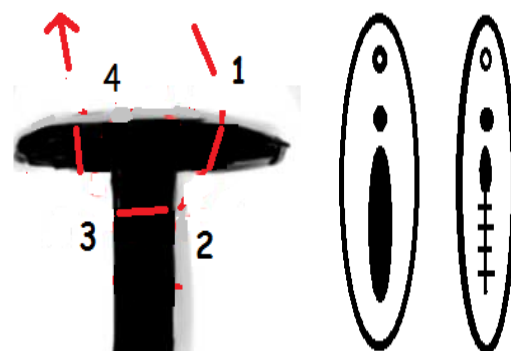


Fig. 2.20c: When inserting a mattress stitch to join the urethra to the bladder, it may work better to place the bites along the edges of the bladder as shown here. This may avoid tearing if the tissues are thin.

Fig. 2.20d: In this case, the bladder defect is closed longitudinally until the size of the defect is approximately the same as the proximal urethral opening.

(OPTION 3) FORMATION OF TWO LEGS FOLLOWING URETHRAL RECONSTRUCTION OR LENGTHENING

This is an option which is used occasionally after urethral lengthening (see below) or after formation of neo-urethra from the bladder or vagina (chapter 4).

(1) *Urethral lengthening*: If the urethra is very short, in some cases it is possible to first close the tissue proximal to the urethra longitudinally to lengthen the urethra to 2-3 cm (see Fig. 2.19m and 2.6b).

(2) *Legs*:

- (a) Place a triangular stitch at points 1, 2 and 3 as shown in Fig. 2.19n (A).
 - Point 1 and 2 = urethra or distal bladder.
 - Point 3 = proximal bladder near the midline. Make sure the stitch is placed extra- mucosal on the muscle layer and avoid going into the bladder lumen.
- (b) When tied, this results in the formation of two legs as shown in Fig. 2.19n: (B).
- (c) To close each leg, for exposure use two Allis forceps to hold the edges apart as you close each leg with interrupted sutures. Push a metal catheter into the angle to show it clearly as you place the stitch. Tie and leave the short end on artery forceps. It is easy to leave gaps so check carefully.

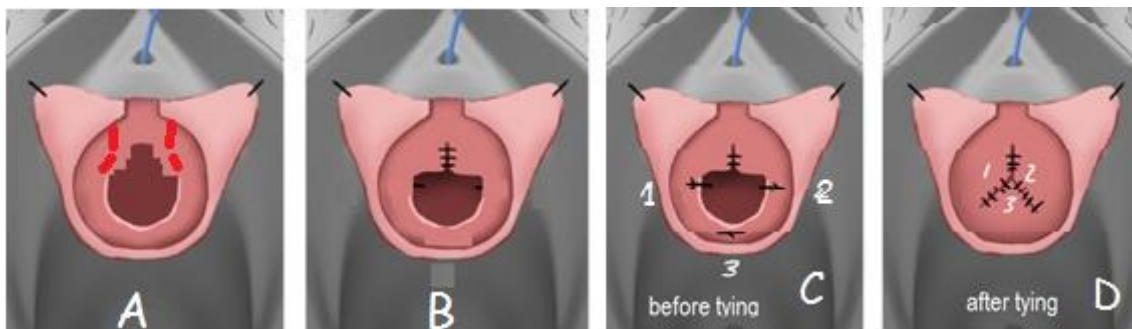
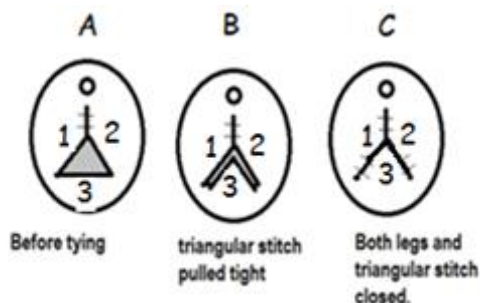


Fig. 2.19m:A: Shows a short urethra which can be lengthened from side to side. Incisions are shown in red.

B: Shows the urethra now lengthened.C: Shows the triangular stitch being placed at points 1,2, 3.

D: The triangular stitch is tied and a legs closure has been completed to close the fistula.



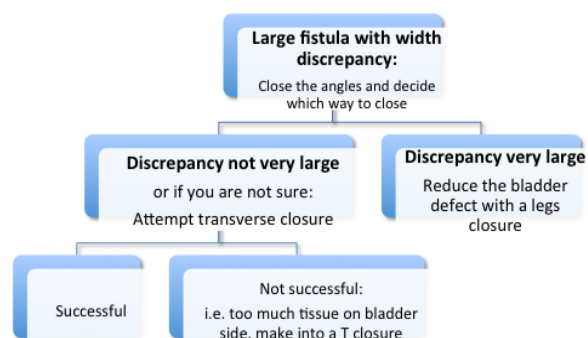
! Tip! When performing Legs closure, it is better to place but not to tie the initial triangular stitch because it can be difficult to find the angles (feet ends) of the repair. Place the triangular stitch but do not tie it. Then pull it tight to see where the “feet” angles will be. Place the angle (feet) stitches in and tie them. Only tie the triangular stitch once both legs are fully closed.

Fig. 2.19n: This shows the placement of the triangular stitch (1, 2, 3) in forming a legs closure.

Summary of dealing with width discrepancy in large fistulas

Either:

- Start transverse closure: Taking bites vertically distally and more horizontal proximally will overcome the problem in most cases. If not, you may occasionally have to make a T-junction in the midline (Fig. 1.20d+e).
- If a large discrepancy is obvious before closure, legs closure (Fig. 2.19i) is the best option.



CHAPTER 3

SPECIAL AND DIFFICULT FISTULAS

Section 3.1: Small and pinhole fistulas
Section 3.2: High Fistulas: Vesico-uterine fistulas
Section 3.3: High Fistulas: Vault fistulas
Section 3.4: VVF with ureter outside of the bladder
Section 3.5: Fistulas with bladder stones
Section 3.6: Double VVF
Section 3.7: Recurrent pinhole fistula
Section 3.8: Around the corner fistula
Section 3.9: Genital fistulas following radiotherapy

⚠ Top Tip! Even if a fistula is small and in the midline or lateral, it is a good idea to reflect the whole anterior vaginal skin bilaterally. This allows more options when closing the defect and may allow a good intermediate layer to be developed. This applies particularly to fistulas described in section 3.1, 3.7 and 3.8.

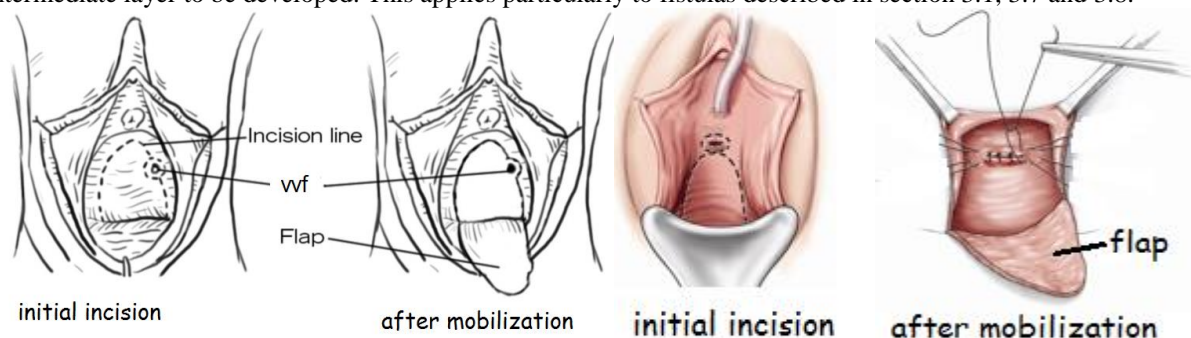


Fig. 3.1a: A wide transverse or inverted U can be used for most small fistulas which may be midline or lateral.

(3.1) SMALL AND PINHOLE FISTULAS

With a small fistula (< 1 cm) or pinhole (1-2 mm) in the mid-vagina or near the cervix, it may be difficult to see the ureters. If the sutures are placed too deep in the bladder wall, there is a risk of ligating or injuring the ureters. You are much less likely to ligate or injure the ureters with superficial bites of the bladder. These superficial bites of the bladder should incorporate the pubo-cervical fascia to ensure the suture does not pull out. These bites in the pubo-cervical fascia will provide an anchor of support and not endanger the ureters. Remember that the ureters run in the layer between the fascia and the bladder.



Fig. 3.1b: Shows a pinhole fistula with a probe being inserted into it.

Fig.3.1c: Shows closure of a pinhole fistula longitudinally. For clarity, the fistula is shown in the diagram larger than it would be.

Fig. 3.1d: In cases where the fascia is not used during the closure of the VVF, after the VVF has been closed, where possible, the pubo-cervical fascia (held by forceps) is dissected off the proximal flap of vagina and used as an additional layer for the repair by stitching it to the periosteum on either side of the urethral opening distal to the fistula. See Fig. 6.4c for a diagrammatic representation of this procedure.

Dissection of the vagina off the bladder: Even though the fistula is small, you still need a wide exposure to allow proper closure (see Fig. 3.1a) utilizing the pubo-cervical fascia which is mobilized from the vaginal skin.

Tip! Keep a narrow metal catheter or probe in the fistula while you dissect and close it so that you do not lose sight of the lumen.

Closure:

- (a) **Transverse closure:** You may close the pinhole fistula transversely in the standard method \pm incorporating the pubo-cervical fascia. Most of the bites are in the fascia rather than the bladder to avoid the ureters. If you close the pubo-cervical fascia separately (Fig. 3.1d), it can be re-attached to the periosteum in a transverse direction (Fig. 3.1d and 6.4c).
- (b) **Longitudinal closure:** Usually only three stitches are needed for closure of the fistula. Each suture is placed first and only tied when all three are placed (Fig. 3.1c).
- Place the first stitch proximal to the fistula. Take a deep bite of fascia, superficial bite of bladder close to one side of the fistula, superficial bite of bladder close to the other side of the fistula and finally a deep bite of fascia.
 - The second stitch is placed in the same way at the distal end of the fistula.
 - The third stitch is placed in the same way between these two.

Some surgeons avoid stitches through the bladder wall and only take bites of the fascia on either side of the fistula. As the fascia is adherent to the bladder, the fistula should close as you approximate the fascia.

Tip! You may also give frusemide to make sure there are no spurts of urine close to the edge, or ensure urine is still coming from the right or the left side after each bite. However, this cannot be done with true pinholes.

(3.2) HIGH FISTULAS: VESICO-CERVICAL/ UTERINE FISTULAS

Vesico-cervical or uterine fistulas may follow Caesarean section or sub-total hysterectomy. It may not always be clear from the history which was done as some menstruation may still occur from the uterine stump. As these are high fistulas, it may be easier to approach them abdominally. However, once demonstrated, the vaginal approach is not difficult in most cases.

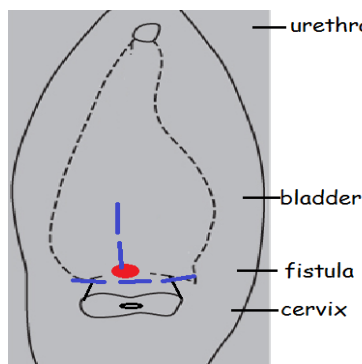


Fig. 3.1e: Shows the approach of finding the fistula by dissecting between the bladder and the cervix. The fistula site is in red. Incision is in blue.

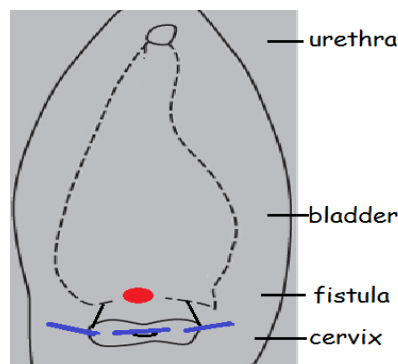


Fig. 3.1f: Shows the approach of finding the fistula by splitting the cervix open with a transverse incision. The fistula site is in red. Incision is in blue.

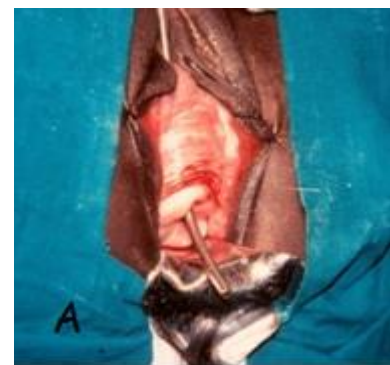


Fig. 3.2a: Shows a sound coming out through the cervix, indicating a vesico-uterine fistula. With a good cervix, the approach used would be as in Fig. 3.1e.

Diagnosis

- If dye is injected into the bladder, it comes out through the cervix. It sometimes helps to pass a metal catheter through the cervical canal into the uterus so that the urine or dye flows out of the cervical os more easily.
- It may sometimes be possible to see the fistula. Pull the anterior lip of the cervix up with a long Allis forceps which may make the track easier to see. Pass the metal catheter up the canal to retract the posterior wall of the cervix and expose the anterior wall so that any fistula of the cervix can be seen.
- Try to pass a (uterine) sound or metal catheter into the bladder via the urethra and then locate the opening in the anterior part of the cervix (as seen in Fig. 3.2a). If the hole is pin-point, this test may not work. Therefore always examine carefully vaginally, repeating the dye test if necessary.

Repair: There are two approaches to vaginal repair:

- Work from above the cervix (supra-cervical or between the cervix and the bladder as in Fig. 3.1e): This approach is preferred where possible. It is much easier to use this method if the anterior lip of the cervix is normal. It can be used when the dye test is positive but you cannot pass a probe from the urethra/ bladder down into the fistula.
- Work from inside the cervix (intra-cervical or through the cervix as in Fig. 3.1f) by splitting the cervix to make access to the fistula much easier. One of the advantages of this method is that it is easy to do even if the anterior cervix is scarred or torn. This method can only be used when a probe (metal catheter or uterine sound is best) can be passed from the urethra/ bladder down into the fistula.

Which approach you use depends on:

- How torn or scarred the anterior cervix is: if torn or irregular Method 2 is easier.
- Whether a probe can be passed through the fistula: If it can, Method 1 or 2 is possible. If it cannot, then Method 1 is possible although you may have to switch to an abdominal approach if it fails.
- If the cervix is pulled up in the vagina and cannot be pulled down, you may have to use the extra-peritoneal supra-pubic approach. This may also apply if the patient is very obese and access is difficult.

! Tip! In general, if you can pass the sound through the cervix, the fistula repair should be accessible from a vaginal approach. To pass the sound or probe, you may have to use your left hand in the vagina to feel for the probe and to guide it into the fistula opening. If a sound cannot be passed through the cervix, it may or may not be possible to repair vaginally. In these cases, a suprapubic approach may be needed, especially if the fistula is high in the bladder or for those not familiar with the vaginal approach (Method 1 below).

High fistula i.e. not visible initially: Try to pass probe via urethra out through the fistula/ cervix

Probe does not pass: Can either be a low cervical fistula (vaginal route possible using Method 1 below) or a high cervical/ uterine fistula (suprapubic approach only).

Probe passes: Vaginal approach usually possible. If it fails, then switch to suprapubic approach.

(METHOD 1) WORKING FROM ABOVE THE CERVIX (SUPRA-CERVICAL APPROACH)



Fig. 3.2b: Shows the incision to dissect the vagina off the cervix and bladder.

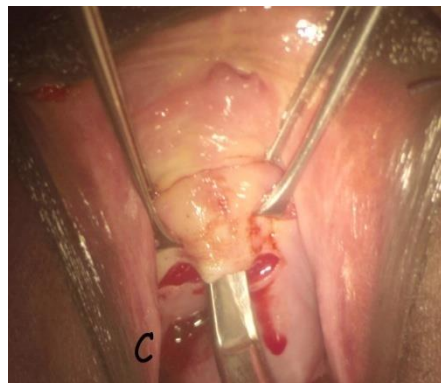


Fig. 3.2c: Shows the transverse incision made and the vagina is being undermined with scissors for the vertical extension.

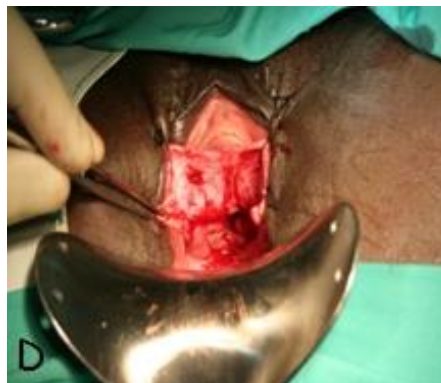

Fig. 3.2d: Shows the vaginal flaps sutured back for exposure.

This is similar to dissection for a vaginal hysterectomy i.e. dissecting the bladder off the cervix/ uterus.

- Holding the cervix, make a transverse incision about 1-2 cm above the os or along the upper border of the cervix.
- A vertical incision is added (Fig. 3.2b) which allows you to develop two flaps of the vagina, which are then stitched back laterally to give good exposure (see Fig. 3.2d). There are two options for making the vertical incision:
 - (a) With scissors, if access is good: introduce the tips of the scissors upwards in the midline from the transverse incision and spread the tips (Fig. 3.2c). This undermines the vagina which is then cut.
 - (b) With a knife, if access is poor or the tissues are scarred.
- During this dissection, an Allis or vulsellum forceps is applied to the cervix to pull downwards and posteriorly while the bladder is pulled upwards and anteriorly with a second Allis forceps. Stay in the

midline and close to the cervix until you find the fistula (distal end) i.e. you see the dye coming out. The fistula will be where the bladder is stuck onto the cervix/ uterus. If the metal catheter (from the urethra) passes into the fistula, this can assist in finding the fistula site. Once found, hold the fistula's distal bladder edge with an Allis and pull upwards.

- Free around the fistula circumferentially between the bladder and cervix until the proximal end is free. This is done by applying an Allis forceps on each side to provide gentle traction. Once there is enough mobilization, place a Langenbeck retractor or a Sims speculum inside the fistula to help expose the proximal end (Fig. 3.3d + e). Often the fistula opens up and becomes quite large when released from the surrounding tissue.
- The proximal edge is dissected until the edges are free.
- The ureters are usually in the distal flap and may have to be catheterized. They are never far away!

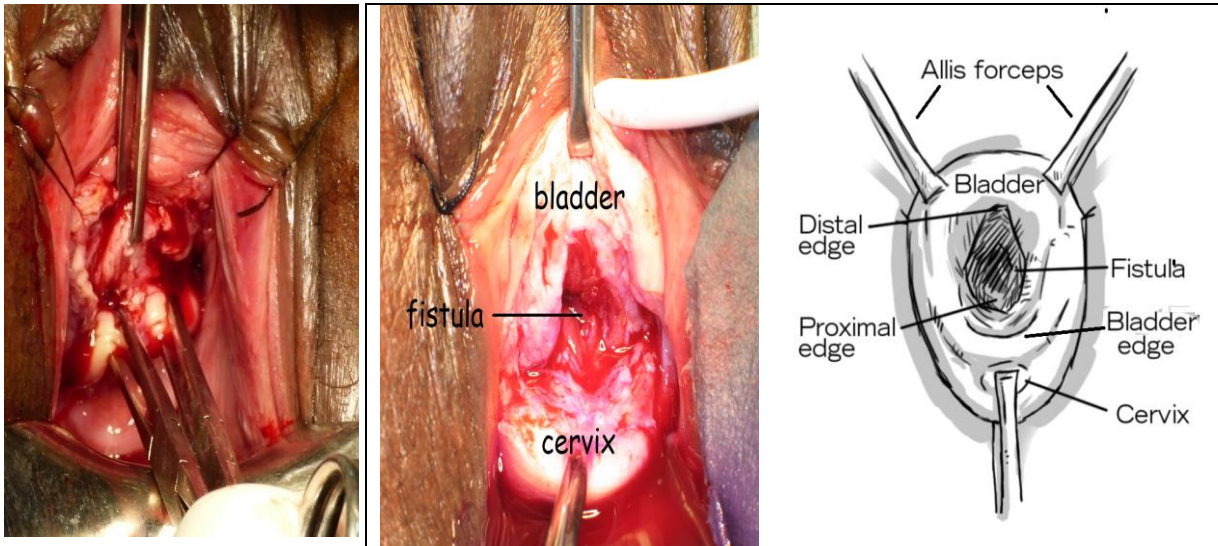



Fig 3.3a: The bladder is lifted by traction with a single Allis forceps while counter-traction is placed on the cervix with two Allis forceps.

Fig. 3.3b+c: By dissecting between the bladder and cervix, the fistula will open (urine/ dye or bladder mucosa seen as in this case). The fistula can then be held with Allis forceps. Initially hold the distal edge, then the lateral edges and eventually the proximal edge as you dissect between the bladder and the cervix.

	<p>Make sure the tips of the scissors are facing towards the cervix and not the bladder as you dissect. This will reduce the risk of injury to the bladder. Also, remember to stay close to the cervix as you dissect.</p>
---	--

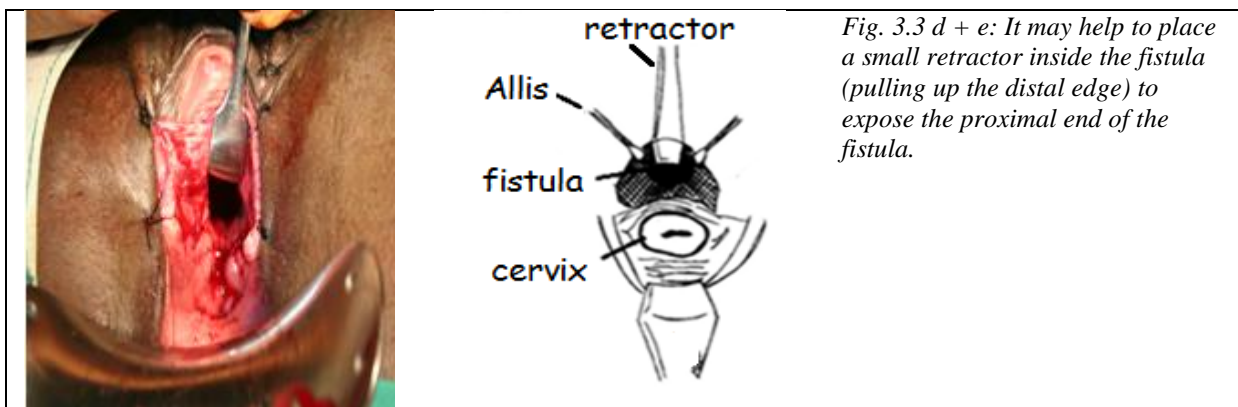


Fig. 3.3 d + e: It may help to place a small retractor inside the fistula (pulling up the distal edge) to expose the proximal end of the fistula.

- The closure is the same as for any fistula and is usually done transversely although it may be easier in some cases to repair it longitudinally (see section 3.3 on vault fistulas as the closure is often similar).
- You should usually repair the hole in the uterus/ cervix now. However, often there is no visible or palpable anterior cervix. If you are able to bring the sides of the cervix together in the midline after dissection, you can close the cervix over a small suction tubing or Foley catheter (8-14 Fr) placed in the cervical canal and leave this in the cervix for 7-14 days after surgery (see also Method 2 below).

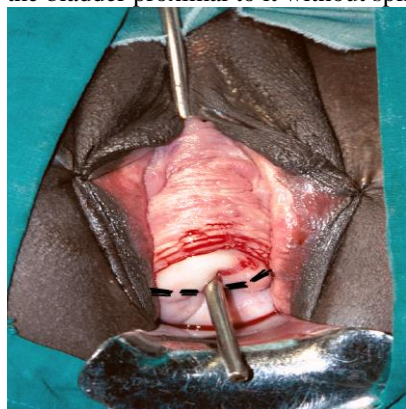Using this method, you can do most high fistulas vaginally that are initially not visible. However, an abdominal approach may be required if: (a) The cervix is pulled up out of sight so that you cannot make the initial incision. (b) When trying a vaginal approach you find the fistula extends up to the fundus of the bladder.

(METHOD 2) WORK FROM INSIDE THE CERVIX (INTRA-CERVICAL APPROACH)

A probe must be passed down from the urethra/ bladder into the fistula before you can attempt this method.

Overview: This method is difficult to describe because in most cases you cannot see the fistula initially. You can only see the probe. The key to understanding this method is the lateral incisions which are made deep on each side at 3 and 9 o'clock into the cervix (see Fig. 3.1f and Fig. 3.4). As these are made, the cervical canal opens up and the fistula becomes visible. Then you can make the distal and proximal incisions around the fistula. The rest of the procedure is the same as with any fistula repair. Remember to use steep head-down position with the patient's buttocks over the table edge.

Incision: In some cases, it may be possible to grasp the proximal lip of the fistula with an Allis and mobilize the bladder proximal to it without splitting the cervix.



However, in most cases, with the probe in the fistula, it is necessary to make a transverse incision through the cervix on either side of the fistula for exposure (Fig. 3.4). It is easiest to think that the incisions that cut the cervix are the usual lateral extensions except they go deeper (into the cervical tissue) than usual. This splits the cervix open transversely.

The incision in the cervix is best made with cautery to reduce the amount of bleeding although severe bleeding is unusual. Be careful not to go too lateral with the incision as the ureter lies just lateral to the cervix.

After making these lateral incisions, keep the probe in the fistula to retract as you incise around the probe (distal and proximal incisions).

Fig. 3.4: Shows the two lateral incisions (black dotted lines) made into the cervix.

Dissection: Once the incision is made, dissect distally, proximally and laterally in the same way as for any fistula.

- Distally: Mobilize the vagina off the bladder, so that you can stitch the distal vagina back with stay sutures for exposure. Be extra careful to stay close to the vagina to avoid opening the bladder. One way of doing this is to put your finger behind the vaginal flap and cut close to (your finger and) the vagina. It is not usually possible to find the ureters until the vagina is mobilized as the ureters are usually on the distal margin of the fistula. Often the anterior lip of the cervix is destroyed so be careful not to cut the bladder.
- Proximally: Put an Allis forceps on the proximal and lateral lips of the fistula and pull on these as you dissect the bladder off the vagina and cervix.



Tip! To help find the ureters on the distal margin, place two Allis forceps on the edges and pull distally.

Closure:

- Bladder: Close the bladder in a transverse direction usually although some surgeons close it longitudinally. Confirm adequate closure with dye test.
- Cervix: Because the cervix was split or was torn anteriorly, to reform it:
 - Place a suction tubing 14-18 F in the cervical canal. The cervix is reformed over this tube.
 - Take deep transverse bites of the cervical tissue on either side of the tubing (right and left) and tie. Usually 2-3 sutures are needed to bring the cervix back together.
 - Leave the tubing in the cervical canal for 7-14 days or ideally until the next menses to prevent cervical stenosis. To prevent it falling out, first the tubing should be transfixed with an absorbable suture and then the suture is fixed to the vaginal wall.

Vagina:

- First, close the lateral vaginal angles.
- Then close the midline. The tubing in the cervix should protect against closing the cervix. A midline stitch brings the anterior vaginal skin down to the cervix (Fig 3.5).
- Then fill in any gaps between the lateral and midline sutures.

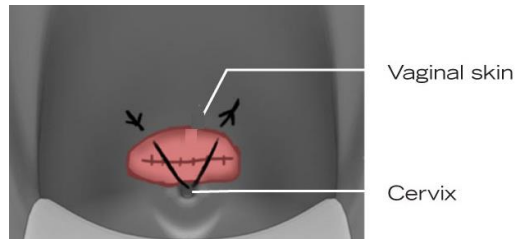


Fig 3.5: Shows the closure of the vagina to the cervix. It is important to avoid the cervical os being closed over as that would lead to haematometria.

(3.3) HIGH FISTULAS: VAULT FISTULAS

These occur post-hysterectomy, most commonly when performed for a ruptured uterus. The fistula is usually located on the anterior vaginal wall just proximal to the inter-ureteric ridge (trigone). For repair, either use the standard or Latzko method:

STANDARD (FLAP SPLITTING) METHOD

If possible, first catheterize the ureters through the fistula opening. They are usually on the distal margin of the fistula and are often close to the edge. The metal catheter is useful to display the inside of the bladder. If you cannot see the ureters, you may have to start the dissection first.

Incision + Dissection: The standard incision is made as in chapter 1. The vagina is dissected from the bladder. Remember to hold both the vaginal and bladder edges with forceps as you cut, as this makes access easier. Once mobilized, stitching back the vagina both distally and proximally will reduce the need for retraction of the edges by the assistants.

Tip! Mobilization of the fistula proximally is often facilitated by deliberately opening the peritoneal cavity into the pouch of Douglas behind the fistula. Some surgeons prefer to close the peritoneal opening later so that the blood, urine or dye does not wash into the abdomen with the patient in Trendelenburg position. However, this is not essential and it is easier to incorporate it into the vaginal closure.

Reference: *Vesico-vaginal Fistulas in Developing Countries: Paul Hilton in Textbook of Perinatal Medicine (2nd edition 2006). Chapter 201 Editors: Kurjak A and Chervenak FA. CRC Press.*



Even though the ureters open distally into the bladder, you can still injure them during proximal dissection especially if there is a lot of scarring from the original surgery.

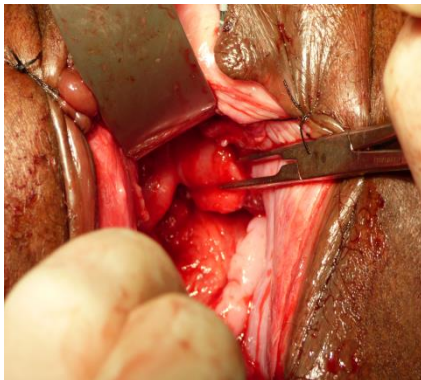


Fig. 3.6: Shows an extension or tear in the proximal wall. The proximal bladder is being held with Allis forceps to demonstrate the apex of the tear.

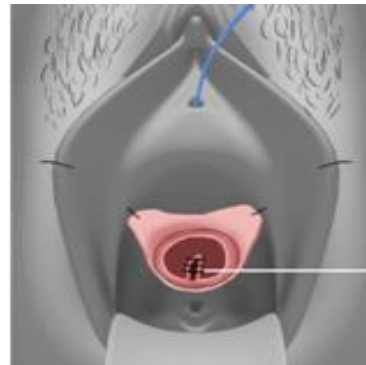


Fig. 3.7a: Shows the extension (white line) sutured with interrupted sutures from inside the bladder.

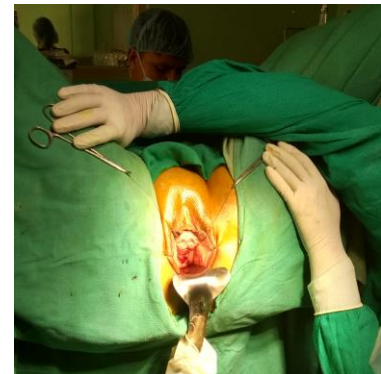

Fig. 3.7b: Shows the assistant stretching both angle sutures of the bladder with both hands to help in the closure of the bladder.

Closure: The bladder is closed in one layer usually transversely although some surgeons prefer longitudinal closure. It helps in the exposure if you get your assistant to hold and stretch both angle sutures to display the rest of the bladder (see Fig. 3.7b).

Extensions: Often with vault or vesico-uterine fistulas, the margins are irregular and there may be an extension of the fistula up the proximal bladder wall (Fig. 3.6 and 3.7a). This extension can be stitched first with interrupted sutures. There are several tips in dealing with these extensions:

- Place a Sims speculum or a small Deaver retractor into the bladder to retract the distal bladder wall (see Fig. 3.6).
- Closure is done longitudinally with interrupted stitches placed from inside the bladder so the knots end up inside the bladder lumen. The alternative is to place the stitches extra-mucosally by using a backhand grip as you place the stitches so the knots end up outside. It is not critical which method is used.
- After tying, keep the short ends of each stitch on artery forceps. Upward traction on these will help place the next stitch. When stitching longitudinally, it is easy to leave gaps between stitches so check for this.
- Once the extension is closed, you may either continue with a longitudinal repair (more commonly) or complete the closure transversely depending on the fistula shape.

THE LATZKO METHOD

This technique is useful if access is difficult. There is little, if any, shortening of the vagina from the procedure. This technique is easier than the standard method with minimal blood loss and is often used by those not so familiar to fistula surgery. The essential difference (in theory) with this method is that the sutures are placed in the fascia between the vagina and bladder rather than in the bladder and so there should be less risk to the ureters.

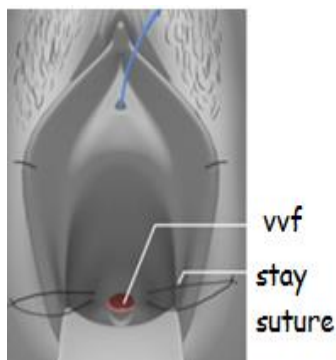


Fig. 3.8: Shows a stay suture inserted for exposure.

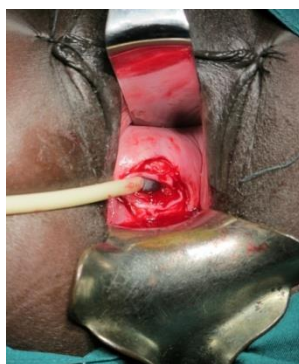

Fig. 3.9c: Shows a Foley catheter inserted into VVF.

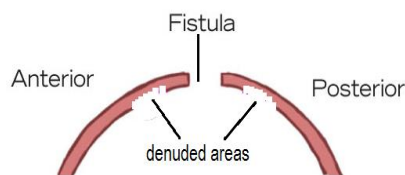


Fig. 3.9b: Shows that in a Latzko repair the anterior and posterior walls (denuded areas) of the vagina/ bladder are sutured together.

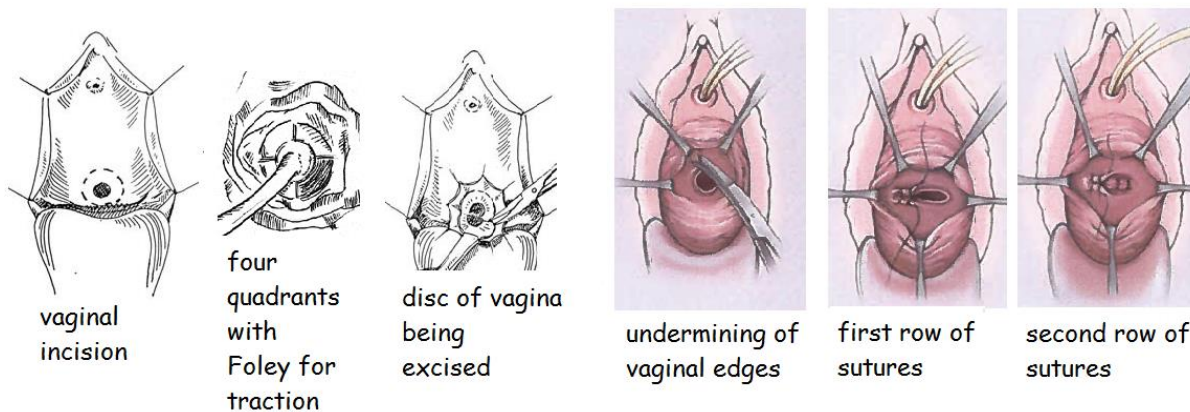


Fig. 3.9a: Shows the steps for Latzko repair.

For exposure:

- Use a Foley balloon to pull down and expose the fistula. The catheter is passed via the vagina into the fistula lumen and inflated (Fig. 3.9c). This allows you to make the incisions in the vagina easily. Vault fistulas are the only uro-genital fistulas where this technique is useful as there is sufficient mobility. A silastic catheter may be easier to insert as it is firmer.
- Insert two stay sutures about 3 cm from the fistula edge on each side to the lateral wall of the vagina as in Fig. 3.8.
- Injecting saline with adrenaline just beneath the vaginal mucosa facilitates dissection in the proper plane and reduces bleeding.

Incision: Make an outer circular incision in the vagina 1.5-2 cm from the fistula edge as shown in Fig. 3.9a. The incision should only be deep enough to go through the vaginal skin. The circular area is now divided into four quadrants (see Fig. 3.9a) and each quadrant is dissected separately and the vaginal epithelium is excised superficially. This leaves an underlying (raw) submucosal area which will be later used in the closure.

Dissection: After excising the vaginal epithelium, mobilize from the incision outwards by undermining the vaginal edges to develop as much fascia as possible. The scarred bladder edge of the fistula is not freshened or trimmed as this predisposes to haematoma formation.

Closure: All layers are closed in a transverse direction (Fig. 3.9a). The first and second layers bring together the fascia between the vagina and bladder, rather than the bladder itself and thus (in theory) avoids the ureters.

- 1st layer: the raw areas on the anterior and posterior walls are sutured together transversely. All sutures can be placed before tying them (after removing the catheter). The bites are taken just ½ cm from the edge of the fistula and do not go deep. Avoid taking bites of the bladder edge. Do a dye test after the first layer is closed. If the first layer of closure is watertight, the chance of success is good.
- 2nd layer: approximates the remainder of the raw surface of the anterior and posterior walls. The bites are taken close to the vaginal incision and should not be too deep either.
- 3rd layer: approximates the vaginal epithelium.

A combination of the Latzko with the standard method of fistula repair can be used. Use either: the Latzko incision and excise the vaginal epithelium or use the standard incision. You may then catheterize the ureters if they are close to the edge and proceed to repair the bladder as with the standard repair.

SUMMARY OF TIPS FOR MANAGING HIGH FISTULAS: VAULT AND VESICO-UTERINE

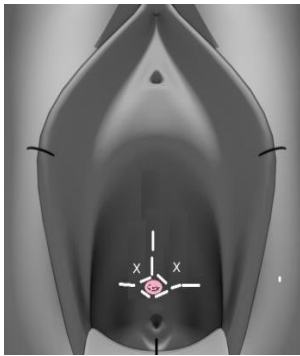



Fig. 3.9d: Shows the incision used to mobilize the vagina in proximal fistulas.

- It may help to make a midline extension when incising the vagina to help mobilize the vagina (Fig. 3.9d). Then grasp the junctions of the vertical and horizontal incisions (marked X in Fig. 3.9d) with an Allis forceps to help mobilize the vagina.
- A small Sims speculum or a small Deaver retractor can be useful for retraction of the anterior or lateral vaginal wall as you mobilize the vagina. It can later be used to retract the distal bladder wall.
- A large Deaver retractor is very useful especially in large patients to retract the posterior vagina/ cervix.
- When closing the bladder, keep the ends of the angle sutures long and place them on either side of the Auvard weighted speculum for retraction or get your assistant to stretch them (Fig. 3.7b). This traction helps to expose the remaining defect in the bladder and by placing the suture ends lateral to the speculum, they do not get in the way.

 Top Tips!	<p>As these fistulas are high, it can be difficult to keep sight of the proximal edges of the fistula during closure.</p> <ul style="list-style-type: none"> • A great tip is to use a metal catheter inserted into the fistula to find the edges. Then (a) If you still cannot see the complete edges clearly, apply Allis forceps to hold the edges securely. (b) If you can see the edges clearly, the metal catheter can be used while you place the central sutures as the defect becomes smaller instead of pickups/ dissecting forceps. • As you close, keep the short end of the previous suture on an artery forceps.
---	--

(3.4) VVF WITH THE URETER AT THE EDGE OF/ OR OUTSIDE THE BLADDER


In larger VVFs, the ureter may be at the edge of, or outside the bladder.

- If the ureter is close to the edge (Fig. 3.10): When the initial incision is made to separate the vagina from the bladder, the ureter is re-incorporated back into the bladder by incising the vagina lateral to the ureteric orifice so that the ureter becomes part of the bladder as shown with the dotted line in Fig 3.10.
- If the ureter opens away from the edge as shown in Fig 3.11 but it is still on the surface of the bladder wall and within 2 cm of the fistula, then it is usually possible to get it back into the bladder.
- If you cannot catheterize the ureter or it is stuck in scar tissue in the pelvic side-wall or you fail for any other reason, then abdominal re-implantation is necessary.
- The method you use depends very much on the situation. Therefore it is good to know all the methods. The following methods can also be used if the ureter is transected during dissection.

Method 1 (Wrap): Always put a ureteric catheter into the ureter first and bring it out via the urethra. This has the effect of pulling the ureter back into the bladder.

- A small amount of mobilization of the ureter may also be possible. The ureter has a rich blood supply in the adventitia so ensure that there is adequate peri-ureteric tissue if you mobilize.

- If the ureter is back from the edge of the fistula, split the bladder wall/ fistula opening down to the ureter – usually not more than 2 cm. In some cases, the ureter will be almost level with the fistula so that it is not necessary to split the bladder.
- It is then necessary in most cases to suture the ureter up to the edge of the fistula. The aim is to get the epithelia of the bladder down to the epithelia of the ureter and therefore reduce the risk of stricture. Using a fine suture of 4/0, the sutures are inserted from the ureter into the bladder to pull the ureter towards the bladder. One of these sutures is shown in Fig. 3.11a. The first bite goes from out to in (on the ureter), the second bite goes from in to out (on the bladder) and tie so the knot is outside. Start the sutures on the ureter about 3-5 mm from the edge. Alternatively, it may be easier to start with the bladder and then go to the ureter, depending which side it is. Four sutures will be placed circumferentially on the ureter (see Fig. 3.11b):
 - Place one posteriorly first and tie it. It is a good idea to (trans)fix the ureteric catheter to the bladder mucosa now as it can be very difficult to get it back into the ureter if it comes out later.
 - Then place two laterally: insert both lateral stitches before you tie. The ureter should now be pulled up to the bladder edge.
 - Place and tie the anterior stitch: this really covers the top of the ureter with the bladder and does not go into the bladder lumen i.e. bite outside of bladder on one side, then ureter wall and then outside of bladder on the other side.

	<p>Make sure the ureteric catheter is moving freely after you have inserted these sutures. If it moves but not freely, then the ureter is likely to become obstructed when the ureteric catheter is removed. In this situation, your bites have to be taken further back from the edge of the ureter.</p>
---	---

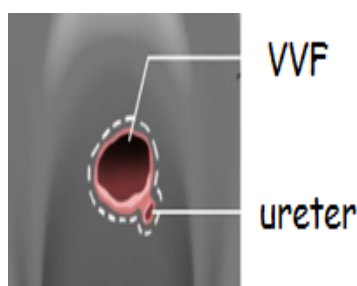


Fig. 3.10: Shows a ureter just outside the fistula/ bladder edge.

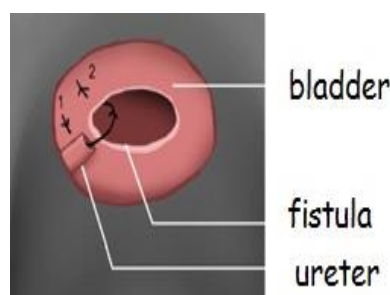
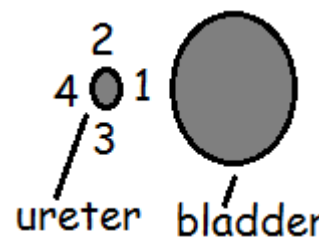


Fig 3.11: Re-setting the ureter back into the bladder as in Method 1.

Fig. 3.11a: Shows one of the lateral stitches being placed in the ureter.
 Fig. 3.11b: Shows the site of the four stitches 1= posterior stitch; 2+3= lateral stitches; 4= anterior stitch.



Method 2 (pull through): When the ureter is away (> 2 cm) from the fistula edge, an alternative option is to mobilize the ureter and then with a stab incision pull the ureter into the bladder using the same technique as you do when re-implanting abdominally. (A similar technique is described in chapter 9 under ectopic ureter.) This method only works well if the bladder has some mobility and is of a reasonable size.

- Mobilize the ureter as little as possible - about 2 cm. You can get nasty bleeders if you go up too far on the lateral pelvic wall. Catheterize the ureter. Place a stay suture on the exposed edge of the ureter. Alternatively, place four stay sutures on each quadrant of the ureter as these can help visualize the ureteric edges once the ureter is pulled through into the bladder.
- Make a hole through the bladder wall by pushing through a right-angled clamp, artery forceps or metal catheter (passed from inside the bladder).
- Grasp the ureteric catheter together with the stay stitch(es) and pull it into the bladder. The ureteric catheter is brought out through the urethra. Alternatively, this can be done in two steps i.e. the ureteric catheter can be pulled into the bladder first and then the stitch(es) on the ureter although sometimes it is difficult to follow the same hole again.
- Stitch the ureter in place (a) from the inside of the bladder with four stitches (b) from the outside of the bladder with 2-3 stitches of fine delayed absorbable sutures going from the ureter to the bladder muscle. If you can get a good closure from the inside, the outside sutures can be omitted. But if you fail to get four quadrant sutures from the inside, then you should place sutures from the outside as well.

Method 3: In this situation, the ureter is partially exposed by a torn bladder wall. In this situation, it is possible to close the bladder wall over the ureter/ ureteric catheter. It would be advisable to keep the ureteric catheter in place for four weeks to reduce the risk of any stenosis.

Post-operative Care:

- The ureteric catheter is left in for 14 days. The main purpose of it is to bypass any oedema that develops.
- Consider a renal ultrasound before discharge to check for hydronephrosis in case stenosis develops after re-implanting the ureter. However, you must consider that hydronephrosis may have been present before surgery. In addition, hydronephrosis will often be seen after re-implantation if the orifice is freely refluxing but not obstructed. Symptomatic obstruction (i.e. renal angle pain, fever) is more significant.

If re-implantation is not possible vaginally:

If there is wide separation of the ureter from the bladder and it is not possible to mobilize the bladder, only the fistula repaired. The ureter can be re-implanted into the bladder by an abdominal approach either then or later. The advantages of waiting until later are:

- You can see if the VVF has healed. If it has not healed, the VVF may be repaired abdominally at the same time as ureteric re-implantation.
- The bladder is often small and scarred with limited mobility which requires extensive mobilization from above in order to re-implant the ureter off tension. This mobilization may place tension on your repair that you performed vaginally and potentially increase the failure rate of the fistula repair. If in doubt, consider a staged repair and be sure to tell the patient she will still be leaking (from the ureter).

To avoid blockage of the ureter as you close the vagina:

- If the ureter can be catheterized, the catheter is brought out separately through the vagina. It is a good idea to use an infant feeding tube which can be transfixed with a suture to the vagina as the normal ureteric catheters have a much higher chance of falling out. Leave in the catheter for 10-14 days.
- If the ureter cannot be catheterized, then you will need to leave an opening or a drain in the vagina for the urine to flow freely post-operatively. Otherwise you may obstruct the flow of urine.

(3.5) FISTULAS WITH BLADDER STONES

Stones cause two problems in relation to fistula repair:

- The bladder wall may be friable, which increases the risk of breakdown.
- The risk of post-operative sepsis would be high as the urine is often purulent or offensive. Oedema of the bladder mucosa is another sign of bladder infection.

It is important to sound the bladder for stones before starting any fistula operation. If stones are found, there are two options:

- It is safest to remove the stone before any repair. Repair should only be attempted at least one week and preferably 2-4 weeks after the stone is removed.
- If you only find a stone after you have already started operating, then it would be appropriate to continue the operation after you remove the stone. There is also a more recent trend to remove stones and repair the VVF at the same time (see below). The steps to avoid infection or failure of repair in these cases are described below.

REMOVAL OF STONES BEFORE VVF REPAIR

- If the stone is small, it can be removed through the fistula. If necessary, you can crush the stone with an ovum forceps and remove it in pieces. The alternative is to pass your finger into the fistula and with your other hand supra-pubically, squeeze the stone out through the fistula. Then pass your finger back in, to check the bladder is empty. The bladder should be irrigated with saline to remove any fragments of stone. If you leave any small pieces inside, another stone will re-form.
- If the stone is large or the fistula is small or healed, it can be removed by making an incision in the bladder suprapubically.

SUPRAPUBIC INCISION FOR REMOVAL OF STONES

Perform an extra-peritoneal suprapubic cystotomy. The extra-peritoneal approach is preferred because a bladder with a stone in it always has high levels of bacterial contamination. Avoiding entry into the peritoneal cavity is a crucial step in preventing serious post-operative morbidity.


- Fill the bladder with 500 ml via Foley. If this is not possible because the stone is large and obstructing the Foley, ask an assistant to push the stone up vaginally which makes it easy to feel the bladder and stone abdominally.
- Make a transverse incision in the midline, close to the symphysis. If you stay close to the bone, you will stay extra-peritoneal and not accidentally injure bowel. Use a self-retaining retractor or two small retractors to keep the recti muscles apart. Avoid opening the peritoneal cavity - if you open it, close it before you open the bladder.

! Tip! If you dissect between the rectus tendons, just above the symphysis you can almost always enter the retropubic space without entry into the peritoneum. The medial aspects of the tendons can be divided (for 1-2 cm on each side) safely without compromising the rectus abdominis function. Once you separate the rectus tendons medially, you can incise the inferior, posterior rectus sheath in a transverse direction just above the symphysis. Usually, you are then in the retropubic space (peri-vesical fat and blood vessels are seen). You can bluntly dissect the bladder off the pubis posteriorly to allow the bladder to drop a bit. The stone can be pushed up to identify the bladder wall or you can try to lift the Foley balloon with your fingers.

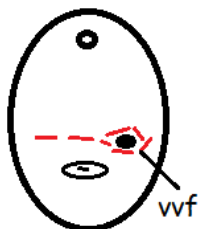- Insert two stay sutures in the bladder on either side of where you are going to make your incision or grasp the bladder wall with two Allis clamps.
- Make a longitudinal opening in the bladder in the midline between the sutures or Allis clamps. You then extend the bladder incision bluntly. Remove the stone. Once the stone is removed, the bladder is flushed extensively with saline.
- Close the bladder in two layers (mucosal layer and detrusor layer) to ensure proper watertight closure.
- The risk of wound infection is high, so only close the skin with 1-2 interrupted sutures and/ or place a drain.
- If urine leaks from the wound: check that the Foley catheter is not blocked. Sometimes the whole incision (skin, sheath and bladder) breaks down. Just keep the Foley in place and it will all heal eventually.

REMOVAL OF STONES AT THE SAME TIME AS VVF REPAIR (VAGINAL INCISION)

If the stone is big and the fistula is small, you can enlarge the fistula transversely by incising through the anterior vagina into the bladder, remove the stone and do a repair. The advantage is that it avoids an abdominal wound and may sort out the stone and fistula in one operation.

	This technique is only appropriate in some cases (especially more proximal fistulas) as otherwise you may create more damage. However, it is useful for all to know the principles of the technique in case you encounter a stone unexpectedly during a repair. If performed electively, it should be by an experienced surgeon.
---	--

- *If there is a (small) fistula*, make a transverse incision through the fistula to open the bladder further and remove the stone (Fig. 3.11c). Some surgeons prefer a vertical incision through the fistula as the risk of cutting the ureters should be less. What you do next is only a guide:
 - If the bladder is healthy enough (i.e. the tissues will hold the sutures) and the urine is clear or only slightly turbid, do a full repair in the same session i.e. close the bladder leaving the anterior vagina open as much as possible. In the presence of infection, only adapt the anterior vagina wall with a couple of sutures. I would stitch any lateral incisions made as these are often vascular. Leave the catheter in at least 18 days.
 - If the bladder is not healthy enough to attempt closing (i.e. tissues friable or very thin) or the urine is cloudy or purulent, without further dissection, only adapt the anterior vagina wall with everting interrupted 2-3 vertical mattress sutures leaving the bladder untouched so that infected urine can drain out via the catheter. By leaving the catheter (16F) in for at least 14 days and up to 28 days, the bladder will heal in about 60% of cases (Kees Waaldijk's series unpublished). If there remains a residual fistula, it is closed in a second attempt.
- *If there is no fistula or the fistula has healed:* I would prefer to use the suprapubic approach rather than risk creating a new fistula by doing a vaginal approach.



Case history: A patient with a history of one previous VVF repair five years previously, presented with large bladder stones and a pinhole juxta-cervical VVF. A wide transverse incision was made through the fistula (see Fig. 3.11c). Two large 4 cm stones were removed vaginally. Both ureters were visualized away from the edges of the fistula. The bladder was closed in one layer of interrupted sutures. The vagina was closed only with two angle sutures with the rest left open. The VVF healed although it required prolonged catheter drainage in the prone position in a very compliant patient.

Fig 3.11c: Shows the incision made to remove the bladder stones.

(3.6) DOUBLE VVFs

If there are two separate VVFs, then:

- If the two are close together, it may be easier to join them together and then repair. However, do not be in a hurry to join two holes together as you may end up with one large but difficult to close fistula. If you are unable to catheterize the ureters, it may be easier to join the fistulas together so that you have a bigger opening. However, be careful when dividing the bridge between them in case the ureter is in it.

- If there are two small juxta-urethral residual fistulas, it is often a good idea to join them together as they were probably one initially. If there are two separate lateral/ corner fistulas: see section 3.8 and Fig. 3.17b.
- If the two fistulas are wide apart, it is better to close them separately e.g. Fig. 3.13c.

Dissecting off the vagina: Even if you are closing the fistulas separately, it is a good idea to mobilize the vagina off both, prior to closure to improve exposure (see Fig. 3.13a).

- Make the incision around the proximal fistula and mobilize the vagina.
- Make an incision around the distal fistula and mobilize the vagina.
- Complete the mobilization of the vagina off the bladder. You may split the vagina in the midline to join the two incisions. You should now be able to see the bladder exposed and both fistulas.

Closure of fistulas: With the vagina dissected and both fistulas exposed, it is easier to decide how to close them. If you just close one fistula without considering the second, it may then be difficult to close the second leading to too many sutures with ischaemia and tension on the repair of the first fistula. Even if the two fistulas appear to be far apart initially, they will end up very close together by the time you have finished closing them.

Therefore never finish closing the proximal fistula without considering how you will close the distal one. There are two options:

- *If close together*, close them together: The sutures used to close one fistula can also be used to close the second one as shown in Fig 3.13b.
- *If there is a reasonable distance between them*, close them separately: Consider closing the proximal fistula longitudinally and the distal one transversely as shown in Fig. 3.13c. In this way, closure of one will not interfere with the other.

Sometimes you only discover the more proximal fistula after closing the distal one. In this case, if you want to close the proximal one transversely, you may have to remove some of the sutures from the distal fistula so the two fistulas can be closed together. Otherwise, you may cause ischaemia with too many sutures.

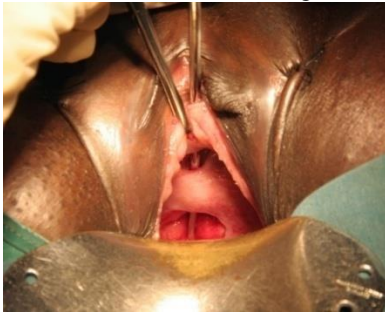

Fig. 3.12: Shows two fistulas.

The key points in managing multiple fistulas are:

- First, separate the vagina off both fistulas before you decide how to close them.
- Never close one fistula without considering how you are going to close the other fistula.
- If closing the fistulas separately, I prefer to start with the proximal one as I find access is easier doing it this way.



Make sure you do not mistake the two ends of a circumferential defect for two separate fistulas. Always check with the metal catheter to see how they relate to each other.

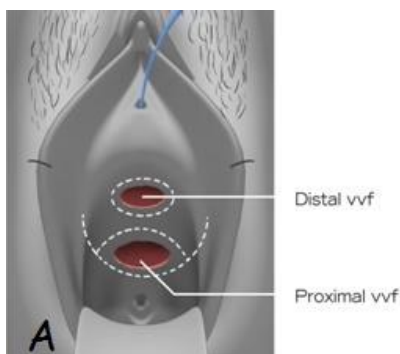


Fig. 3.13a: Shows the initial incision around both fistulas.

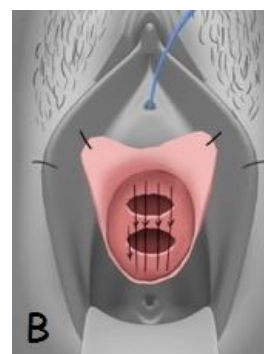

Fig. 3.13b: Shows the two fistulas being closed together.

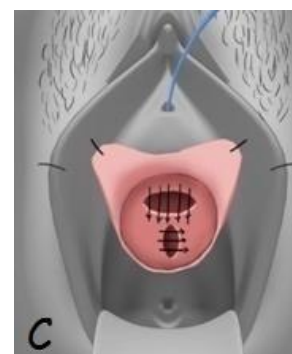

Fig. 3.13c: Shows the two fistulas closed separately.



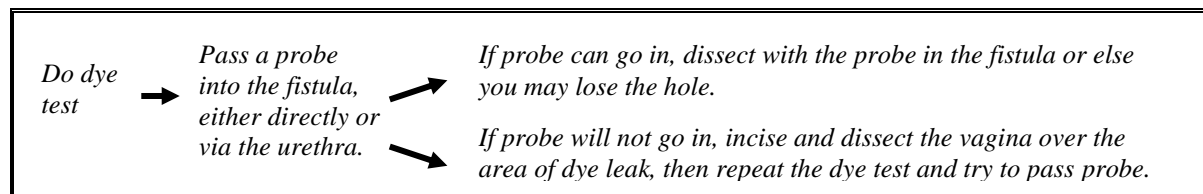
Tip! If there is a large VVF and a second smaller VVF in the urethra, consider doing a staged repair i.e. repair the urethral defect later. This is because the urethra may slough if you try to close both fistulas at the same time.

(3.7) PINHOLE FISTULAS FOLLOWING PREVIOUS REPAIRS

(Step 1) Finding the hole and inserting a probe:

- It is often necessary to inject dye into the bladder to confirm the site of the fistula. Once found, saline can be used instead of dye to pinpoint the exact site while avoiding tissue staining.

- Sometimes when you have difficulty finding the fistula with the dye test, rather than keeping injecting dye, it may help to empty the bladder and start again.
- There may be more than one fistula track in these cases. Sometimes there are multiple holes in the vagina but they all connect with one hole in the bladder (sometimes called the watering-can effect).
- You cannot usually see the bladder mucosa through the fistula but if a probe can be passed through the fistula and this connects (metal on metal) with the metal catheter in the bladder, this is sufficient to identify the fistula (see Fig. 3.14a).



! Tip! In these fistulas, it is very important to leave an island or large rim of vagina (0.5 – 1 cm) around the fistula so that you can identify the fistula later when the dissection is finished.

STOP If the probe goes into the pinhole but does not connect with the metal catheter in the bladder, the probe may be going into a ureter. Repeat the dye test. If the urine from the pinhole is clear = ureter is outside the bladder from a previous repair. See chapter 9 for management of such cases.

(Step 2) Dissection:

Even though the fistula is small, you still need a wide exposure to allow proper closure (see Fig. 3.14b). Make a transverse, cruciate or inverted U incision in the vagina across the fistula. It helps to keep the probe in the fistula as long as possible to help identify it as you dissect widely. The probe also acts as a retractor as you make your incision around the fistula opening. If you cannot pass the probe in, you can still dissect.

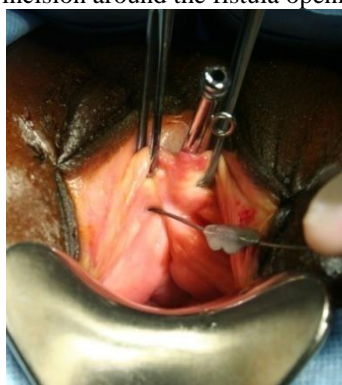

Fig. 3.14a: Identification of VVF with a probe.

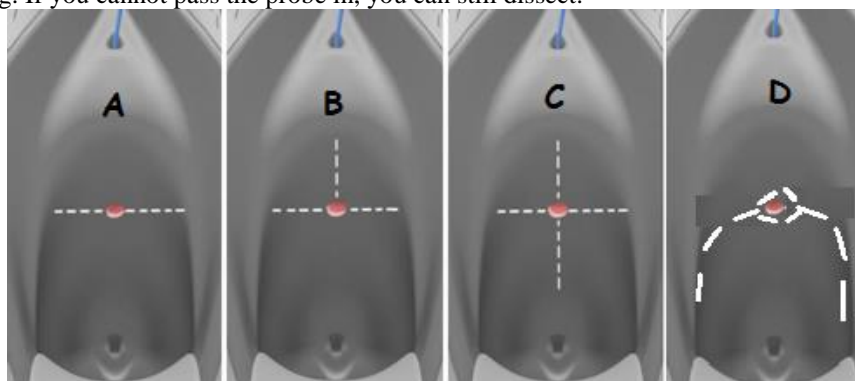


Fig. 3.14b: Shows the various incisions that can be made. Longitudinal incisions are against the natural tissue forces so transverse ones are better.

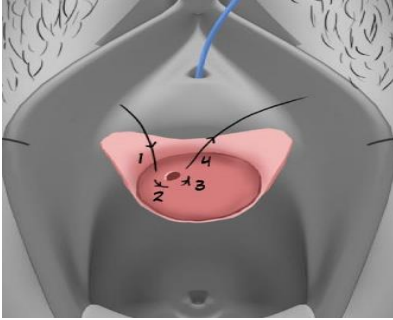
- Dissect as for any fistula staying close to the vagina. Usually in these cases, it is only possible to hold the vaginal edges and it is difficult to hold the bladder edges. The bladder is therefore retracted by the probe, which is pulled in various directions, depending on where you are dissecting.
- In larger fistulas, you can use a metal catheter or a Hegar dilator as the probe. The vagina is dissected off the bladder with a knife or scissors.
- After mobilizing the vagina, you are left with an island of vagina around the fistula, which is excised later. The island of skin prevents you from losing sight of the fistula which happens easily as the fistula is so small. With small fistulas, it is difficult to look for the ureters but at least make sure that the ureters are not in the edge of the fistula.

Note: Initially it may not be possible or necessary to hold the bladder edges with Allis forceps. However, it may be possible later and you may remove the probe/ dilator and hold the bladder edge with an Allis.

! Top Tip! There is often a lot of scar tissue in these fistulas, and it can be difficult to identify the margins of the bladder/ fistula. Scar tissue is hard whereas the bladder is soft. Continue excising scar until the edges are soft and pliable. When you have achieved this, it means you can close the fistula edges. If you just suture scar tissue together, it will not heal. Do not be worried about making the fistula slightly bigger in the process. Reminder: Hard tissue near the fistula = scar or cervical tissue. Firm tissue = vagina. Soft tissue = bladder.

(Step 3) Closure:

With the probe in the fistula, place several interrupted sutures and tie when all are placed (recommended). In very scarred cases, an interpositional flap may be considered.



If access is difficult, another option is to place a mattress or a purse-string stitch while the probe is in the fistula (see Fig. 3.15). In this situation, 3-4 bites are taken. If possible, the initial suture can be through the periosteum but this depends on the fistula site.

Fig. 3.15: The first bite (1) is taken through the periosteum. Then the fistula is closed with a purse-string (circular) suture.

Tip! If you fail to pass the probe into the area of dye leak or if you pass it but it fails to connect with a metal catheter passed from the urethra, then it is likely that you have not identified the fistula site. Usually, there is a track coming from the fistula so you need to excise more scar tissue and try again. Only when the probe touches the metal catheter can you be confident that you have reached the fistula site. However, with very small fistulas the probe may not enter the fistula.

Tip! A good rule is that when you have excised sufficient scar tissue around the fistula track, you should see a good flow of dye coming through the fistula instead of the initial small leak.

(3.8) AROUND THE CORNER FISTULA

If a fistula occurs laterally e.g. following a previous failed repair, then access can be difficult as these fistulas are always densely adherent to the underlying bone. The best way to tackle this is to mobilize out laterally by opening the para-vesical space so that the defect becomes more medial.

(Step 1) Dissect vagina: For good exposure of the bladder, a wide transverse incision can be made which is extended out laterally. Stitch back the distal flap.

(Step 2) Mobilize bladder: After dissecting the vagina off, either sharply dissect the bladder off the pelvic side-wall or use the “blast and spread” technique to mobilize the fistula (Fig. 3.16b):

- Pass the scissors tips closed through the fascia and close to the bone proximal to the fistula, using a sharp tap on the scissors (blast = scissors 2). Then spread the tips until you can get your finger in.
- Repeat this distal to the fistula (scissors 1). Be careful not to go too deep with the scissors to avoid causing deep bleeders. You are now left with the area of the fistula still attached to the bone.
- Then using a finger-tip above and below the fistula, pull medially on the bladder and dissect the fistula sharply off the bone.

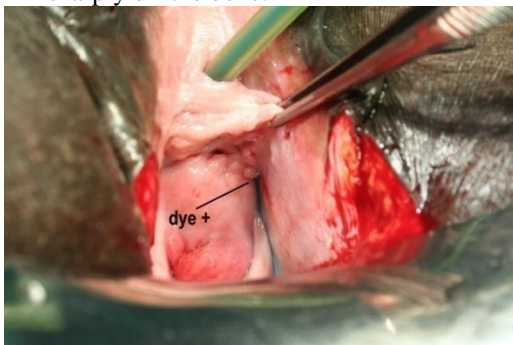


Fig. 3.16a: Shows a typical lateral recurrent fistula.

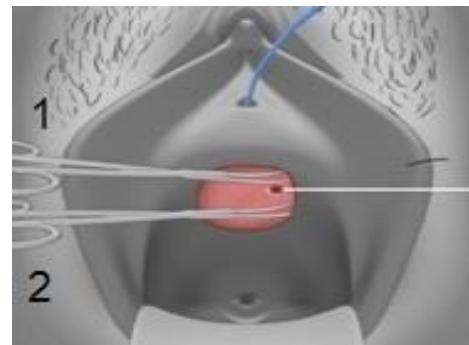


Fig. 3.16b: The blast and spread technique.

(Step 3) Bladder Closure: Place several interrupted sutures. Place all the sutures first before tying. Use the first/previous suture (on artery forceps) as a retractor while you place the second/next. The direction in which you place the sutures depends on the individual case. You may take the bites lateral to medial, or medial to lateral, or distal to proximal.

- As access is difficult, using a small J needle 22 mm (Vicryl W9223) or a 17 mm needle can be very useful. However, a 5/8 circle 26 mm needle may allow better bites of tissue and is usually the best one to use.
- Check with dye that there is no leak.

Tip! If after mobilization and when you are ready to start closure, the bladder edges do not come together easily, to free the lateral fistula edge more, you can incise into the bladder muscularis 1-2 mm deep to

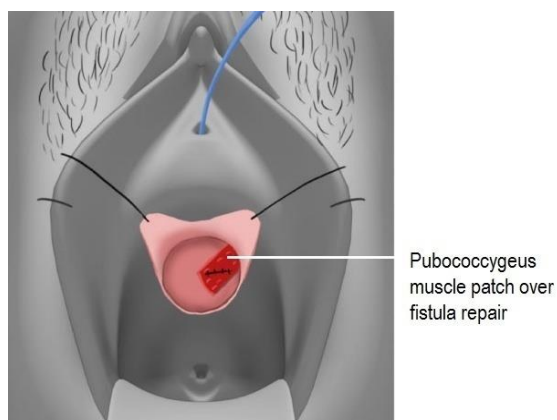
gain extra mobility. This should be done several centimetres back from and parallel to the (lateral) fistula edge for approximately 1-2 cm in length. Pull the bladder medially and feel the tension. As you cut with the scissors or knife you will feel the bladder edge coming in. In reality, you are often cutting into scar tissue on the outside of the bladder rather than bladder muscle. Be aware of where the ureter is when you are going to do this. This useful tip can be applied to any type of fistula where you need some extra mobility and is not specific to this type of fistula although this is where it would be most commonly needed.

(Step 4) Intermediate layer:

Try to get tissue over the repair to reinforce it as these fistulas often break down. This can either be with:

- Pubo-cervical fascia: if there is no obvious fascia laterally, try to develop a layer of it by freeing it from the proximal flap of the vagina near to the cervix.
- Pubo-coccygeus (levator ani): take a piece of muscle off the lateral side of the pelvis at whatever level is most accessible to the repair – the same place where you get the pubo-coccygeal sling (see chapter 1 Step 4). The patch is started proximally and freed so its base is distal. Hold with an Allis proximally as you develop the flap. You can then swing it in over the repair. Stitch it in place so that you get a watertight closure.
- Martius or Gracilis flaps are options. If you place a Gracilis flap over the repair, take it from the side opposite the fistula as this will fit in more easily than if you take it from the same side. It is easy to place the tendon end of the Gracilis over the repair.
- Very occasionally, to reinforce a weak repair, the bladder can be sutured to the lateral pelvic side-wall (see chapter 1c: step 3: If the dye test remains positive).

! Top Tip! A muscle patch can be used in any situation where you have a leak on the dye test but you think another stitch would make it worse. Put the patch over and then stitch it in so the repair is watertight.



Pubococcygeus muscle patch over fistula repair

Fig 3.17a: Shows a patch of levator ani (pubo-coccygeus) freed to be used to reinforce the repair.

STOP Repairs of lateral recurrent fistulas have a high failure rate. However, if you take the following steps, failure rates should be low:

- Adequate mobilization by opening para-vesical space so that the fistula comes in medially.
- Adequate removal of scar tissue so that you see the fistula clearly.
- If the edges do not come together easily, incise into the bladder muscularis for 1-2 mm deep to gain extra mobility.
- After the repair, get an intermediate layer over the repair: pubo-cervical fascia or pubo-coccygeus or Gracilis muscle or Martius flap.

ADDITIONAL OPTIONS FOR MANAGING DIFFICULT LATERAL FISTULAS:

Lateral fistulas are often the result of a failed repair of a circumferential defect.

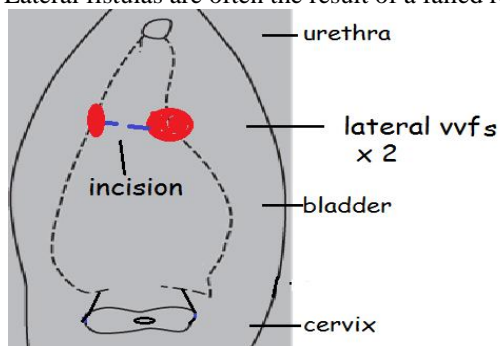


Fig. 3.17b: Shows two lateral fistulas and the incision (blue line) joining them.

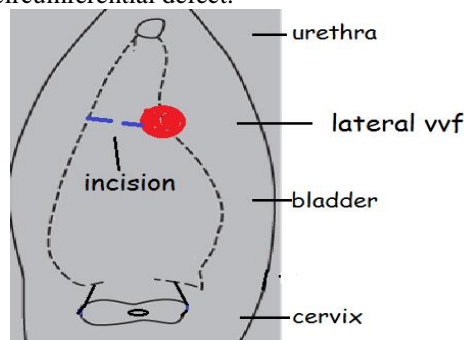


Fig. 3.17c: Shows one lateral fistula and the incision (blue line) to open the urethra/ bladder junction.

Option 1: Joining up two lateral fistulas: In this situation, all or most of the fistula(s) is visible (Fig. 3.17 b).

- If there are lateral fistulas on both sides (Fig. 3.17b), it may be easier to join the two holes by cutting the posterior bladder wall which separates the two holes. This is particularly useful if one or both of the fistulas

extends around laterally like a $\frac{3}{4}$ circumferential fistula. Once you have joined the two fistulas, you can get a clear view and access to both fistulas. The anterior part of the repair is usually intact (i.e. the 11, 12 and 1 o'clock positions although you can do a full circumferential dissection if this makes for a better and easier repair. You have to close the defect laterally and posteriorly like for a $\frac{3}{4}$ circumferential fistula.

- Even if there is only one difficult fistula (Fig. 3.17c), it may still be necessary to open the whole (posterior) junction of the urethra and bladder to access the fistula.

Option 2: Supra-meatal approach: In some cases, the posterior bladder/ urethra has healed but there is still a defect anteriorly on one or both sides at the urethro-vesical junction. Part of the fistula may be visible although more commonly all you see is dye leaking on one or both sides, and the fistula is not visible or accessible. In this case, a supra-meatal approach is a useful way to access these otherwise inaccessible fistulas. *Method* (see Fig. 3.18): Incise around the top of the urethral meatus just below the pubic bone i.e. an inverted U incision between 3 and 9 o'clock positions. However, you can sometimes manage with a more limited incision on the affected side as shown in Fig. 3.18a. Incise enough to visualize the fistula.

- With sharp and blunt dissection, the urethra and distal bladder are freed from the pubic bone. The fistula is now easily visualized with the help of a dye test if necessary and a good repair can be performed.
- If the urethra tears during dissection/ mobilization, then there probably was a circumferential defect with the urethra stuck to the bone. In this case, you have to mobilize the bladder anteriorly to bring it down so the defect can be closed.
- It is a good idea to place a Martius flap over the repair
- The one disadvantage of this incision is that it loosens the anterior fixation of the external urethral opening from its almost immobile/ fixed position which is required for the urethra to keep its length.

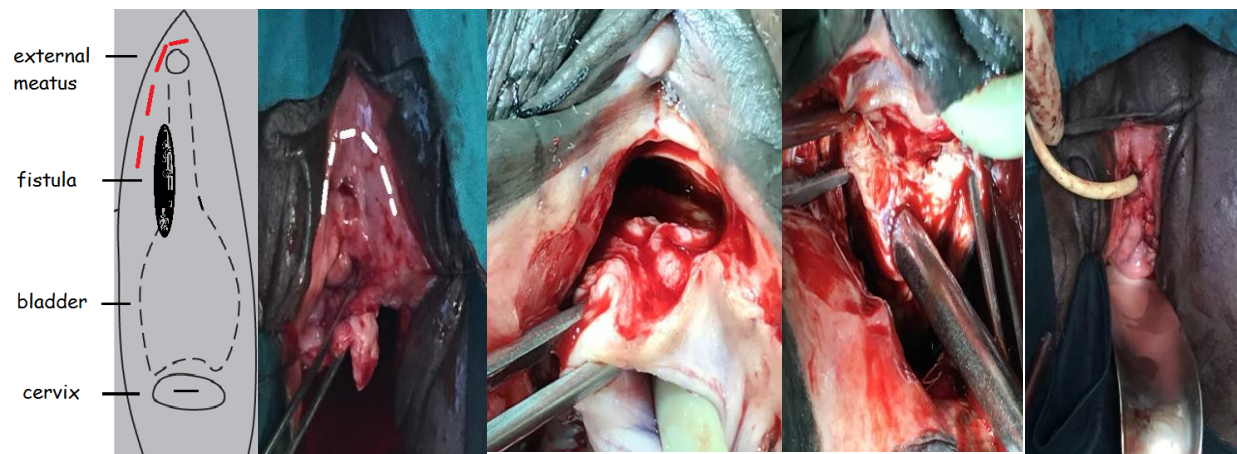


Fig. 3.18a: Shows a fistula involving the antero-lateral urethra and distal bladder. The supra-meatal incision is the red interrupted line.

Fig. 3.18b: The initial dissection has been made which failed to give access to the fistula. The dotted white line is the supra-meatal incision which is about to be made.

Fig. 3.18c: Shows the supra-meatal incision made with the Foley catheter in the external meatus and most of the urethra is now freed from the pubic bone on the right side.

Fig. 3.18d: Shows a metal catheter in the fistula on the right lateral side with the Foley catheter (just visible) in the external meatus which is swung up and over to the left.

Fig. 3.18e: Shows the incision in the vagina closed with the urethra back in place. The Foley catheter is inserted in the external meatus.

Option 3: Suprapubic approach: If the fistula is both high and lateral, it may not be possible to get access to close the defect and a suprapubic approach will be necessary (see section 5.3d). However, using the supra-meatal approach, one can usually avoid the suprapubic approach for lateral or antero-lateral fistulas.

(3.9) GENITAL FISTULAS FOLLOWING RADIOTHERAPY

Radiotherapy-induced fistulas are seldom if ever associated with spontaneous closure (i.e. even with the help of a Foley catheter) and operative management should be performed as appropriate. However, repair should not be attempted until at least one year after the completion of radiotherapy. There are four options in managing these cases:

- Conventional repair: these should always be performed with a flap to bring in fresh blood supply. The only radiotherapy induced VVFs or RVFs that I have managed to close successfully were performed with the

help of a Gracilis or rectus flap. Mobilization of the fistula is often difficult and the edges are more likely to slough. After repair of VVF, the Foley catheter is left in for 28 days. If a ureter needs re-implantation, then the ureteric catheter is also left in for 28 days.

- Colpocleisis is a good option especially if the lower vagina appears healthy (see below).
- Diversion (urinary = Mainz pouch or ileal bladder; faecal = colostomy) is another option because even with good technique, healing is unlikely.
- In RVFs, it is possible to do an anterior resection and then pull through healthy colon and do a low colo-anal anastomosis from below (as described in chapter 7).

! Tip! It is a good idea to do an examination in the operating room before any surgery to assess the defect. Give frusemide to locate the position of the ureters as they are often outside the bladder.

COLPOCLEISIS: In patients with VVF, or VVF with RVF, it may be possible to close off the vagina (colpocleisis). By closing the vagina away from the irradiated area, and in tissues with better blood supply, it means that healing is more likely. However, in some cases, the whole vagina has been radiated and the tissues may still fail to heal. If the vagina looks pale, then it is worth attempting colpocleisis. If it appears like slough tissue, then it is probably not worth attempting. The effects of a colpocleisis are:

- If there is a VVF, the upper vagina is made into a diverticulum of the bladder (see Fig. 3.19).
- If there is a combined VVF and RVF, the urine drains via the VVF into the upper vagina, and then via the RVF into the rectum.

Method: A circumferential incision is made 1-2 cm below the level of the fistulas and as far as possible on healthy tissue. By dissecting upwards, the cut edges of the vagina around the fistula are turned inwards by a single layer of sutures. By dissecting downwards, a lower sleeve of vagina is made. Part of this can be excised but leave sufficient flaps for the lower vagina to be closed. (Alternatively two circular incisions can be made at as high a level as possible, the second one situated one centimetre below the first. The intervening vaginal wall is then excised.) The bare para-vaginal tissues are approximated transversely (by approximating the anterior and posterior walls) in as many layers that can be achieved without tension. Aim for a minimum of four rows of interrupted sutures and sometimes several more (Fig. 3.19a). A flap is placed e.g. Martius or Gracilis. The flap is used as there is inevitably some space remaining here (Fig. 3.19b). Usually, the only closure below the flap would be a single layer of interrupted sutures in the vaginal or vulval skin of the introitus i.e. just proximal to the external meatus (Fig. 3.19c).

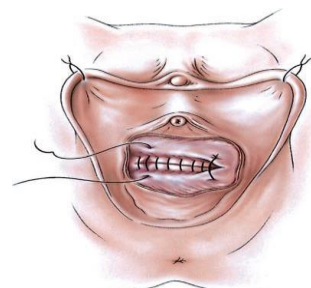

Fig. 3.19a: Colpocleisis being performed in several layers transverse front-to-back.

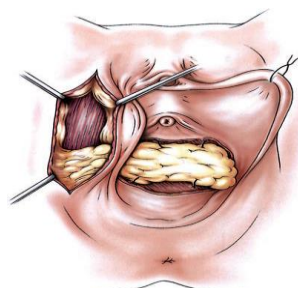


Fig. 3.19b: Shows a Martius flap being used to fill the dead space.

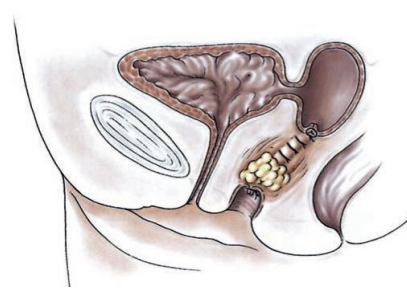


Fig. 3.19c: Shows the colpocleisis completed. Courtesy of Paul Hilton.

Specific complications:

Generally, colpocleisis is a safe and straightforward procedure and is well accepted provided the patient and her partner are prepared to accept the loss of sexual function. Nevertheless, there are two important complications:

- The effects of irradiation are life-long; post-radiotherapy fistulas may present many years (up to 50 years) after treatment. Because of this, even if at presentation only a VVF is seen, and even if the patient appears to be cured by colpocleisis, an ‘RVF’ may develop later (between the rectum and the ‘obliterated’ upper vagina). In such cases, the development of leakage of urine per rectum may occur as a late complication, in an apparently closed fistula.
- Because the effect of the procedure is to obliterate the vagina by approximating the anterior and posterior walls, if the closure is made too low, the urethra may in effect be pulled open, increasing the risk of post-repair stress incontinence. The risk may be reduced to some extent by using an interpositional flap (e.g. Martius or Gracilis) to fill in dead space and provide some additional urethral support.

CHAPTER 4

RECONSTRUCTION OF AND PROBLEMS WITH THE URETHRA

Section 4.1: New urethra made from the anterior vaginal wall during VVF repair
Section 4.2: New urethra made from anterior bladder during VVF repair
Section 4.3: Lengthening the urethra from the anterior vaginal wall without (or following) a VVF repair
Section 4.4: Fistulas distal to the urethral orifice
Section 4.5: Managing the torn urethra and urethral strictures due to non-obstetric trauma

- When a urethra has been destroyed, or when only a small part of it remains, a new urethra can be made. This can be done by utilizing either the anterior vaginal wall or the bladder wall. The aim is to create a narrow tube which can then be compressed by surrounding tissues or a sling. However, it is difficult to re-create a functioning sphincter so the result may be a functionless tube.
- The common situations requiring urethral re-construction are:

<i>Where there is a large VVF and no urethra remains.</i>	The new urethra is made either from the vagina (section 4.1) or from the bladder (section 4.2).
<i>Where the VVF has been closed (or is small and distal) but there is a very short or no urethra.</i>	This most commonly only occurs following a VVF repair. It may also occur before any surgery when the main site of injury is the urethra rather than the bladder. Fig. 4.1b would be a good example of this type. Other causes are sometimes seen e.g. previous excision of a tumour or trauma to the urethra. The new urethra is made from the vagina (section 4.3) by treating the urethral opening (or bladder opening if the urethra is completely absent) like a fistula.
<i>If the urethra is very short before a VVF repair:</i>	<ul style="list-style-type: none"> • It can be lengthened by using the retracted urethral tissue as it is often torn in the midline. See pages 38 + 46 and Fig. 2.19m. This is relatively simple to do where it is possible. • It can be lengthened using a bladder flap as in Fig. 4.9 a + b below.

(4.1) NEW URETHRA MADE FROM THE ANTERIOR VAGINAL WALL DURING VVF REPAIR

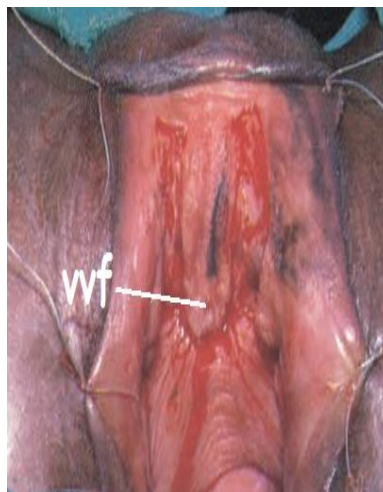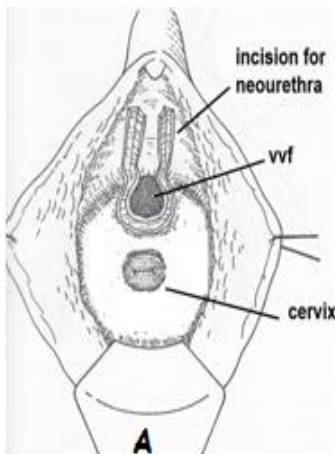


Fig. 4.1a: This diagram shows the incision around the fistula and the two incisions for the new urethra. Note there are no lateral extensions.

Fig. 4.1b: Photograph shows the U-shaped incision for the new urethra. In this case, the VVF is small so the case is similar to those described in section 4.3 (Courtesy of Kees Waaldijk). Once the incision is made, the lateral margins of the incision are undermined and mobilized.

This method uses vagina (base of original urethra) to make the urethra. It is particularly good if the tissue where the urethra should be is substantial i.e. it feels like the base of a split open urethra. If it just looks like skin, and bone is easily palpated underneath, this method is less useful.

(1) Incision

Make incision as in Fig. 4.1a around the bladder defect and then make two incisions for the new urethra. It is important to note that you avoid making the usual lateral extensions.

Incisions for the new urethra: If the incisions are not wide enough apart, failure is guaranteed. Therefore, plan your incisions carefully before you make them. Two vertical incisions are made 2.5 - 3 cm apart along the anterior vaginal wall. The length will depend on the anatomy of the particular case although 3 cm is usually sufficient.

- Do not make a new urethra too long, as this increases the risk of developing a stricture.
- As a rough guide, the new orifice ends up 2-3 cm below the clitoris.

(2) Dissection

Bladder: This is performed as described in section 2.3. In most cases, this will require a full circumferential dissection.

! Tip! Once the ureteric catheters are inserted, they can be fixed with a stitch to the suprapubic skin and lie in the floor of the new urethra. The new urethra will be stitched over them later. This keeps the catheters out of your way once they are inserted, rather than waiting until the closure of the urethra.

Urethra: Having made the two vertical incisions, dissect underneath medially for about 0.5 cm. Start a bit deep to the line of incision so the urethral wall will be thick. This dissection can be done with scissors.

Then dissect lateral to each incision as this will help to free the new urethra. You usually have to dissect deeply on each side so that the urethra is mobilized completely to the inferior pubic ramus to facilitate closure in a tension-free fashion. Often the retropubic space is entered on each side to facilitate mobilization of the urethra, urethro-vesical junction and the distal bladder.

(3) Start the closure of the bladder and urethra

Either the bladder or the neourethra closure can be started first. In most cases, start with the bladder closure (especially laterally) but it is a good idea to start closing the urethra early so that you can see what para-urethral tissues are available for closing the bladder.

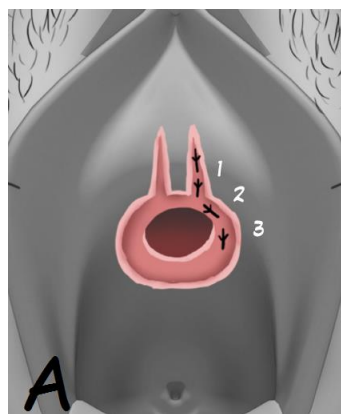


Fig. 4.2A: Shows the bites of the angle suture (1, 2, and 3) for closing the bladder.

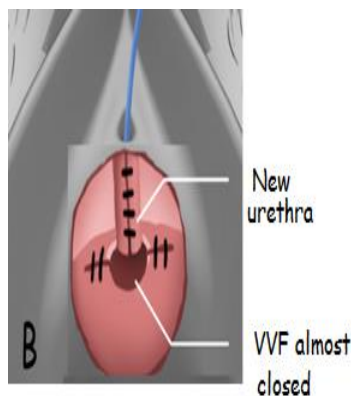


Fig. 4.2B: Shows the closed urethra about to be joined to the almost closed bladder.

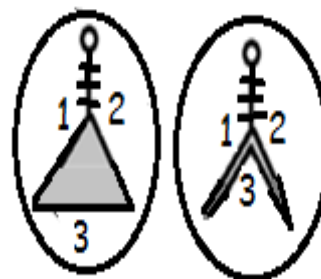


Fig. 4.2C: In this case, the new urethra is joined to the (open) bladder with a triangular stitch.

Bladder: There are several ways in which the bladder may be closed:

- (a) (Fig. 4.2A+B): Do the usual transverse closure of the bladder by stitching the lateral bladder to the bone and para-urethral tissues. The aim is to close most of the bladder first, with the exception of the central portion which will be re-connected to the new urethra. Most of the distal lateral bites (through the periosteum and para-urethral tissue) are taken in the line of the incision that you have made for the new urethra (Fig. 4.2A). Several sutures can be placed along almost the same line although Fig. 4.2A only shows one suture. However, these may reduce your access on each side when closing the urethra.

- (b) (Fig. 4.2C): If you form the new urethra first, then use a triangular stitch to join the urethra to the bladder which is not yet even partially closed. This results in the formation of two legs which are then closed. See Fig. 2.19m + n for more details.
- (c) (Fig. 2.19i): Reduce the size of the bladder by starting the closure with two legs. Then continue to reduce the bladder opening until it is small enough to join to the urethra.

Urethra:

- Put the distal suture in first, at the external urethral meatus which now holds the Foley catheter in place. With the Foley catheter in place as a guide, check after each suture that you have not caught it with a suture.
- Hold the two edges of the urethra with Allis or dissecting forceps and remove these forceps as you tie the stitch. Use interrupted 3/0 or 4/0 Vicryl or chromic catgut (Fig. 4.3).
- If the edges of the urethra do not come together without tension, you have to mobilize more on both sides by deepening the two vertical incisions.


	<p>It is important not to try to force a large catheter through a new urethra as this would increase the risk of breakdown. There is no problem using a size 14F Foley. The fit of the catheter in the urethra should not be tight as this may compromise healing due to excessive tension at the repair site. A Nelaton catheter is a useful option in this situation as this allows a 14 F to be inserted with a low risk of blockage (See Appendix 5).</p>
---	---

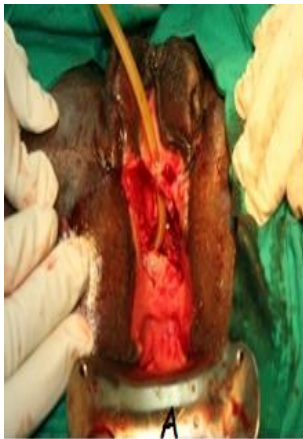

Fig. 4.3: A shows the new urethra being formed starting distally. This is then continued proximally as in B.

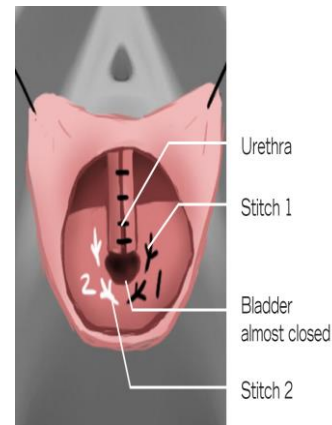
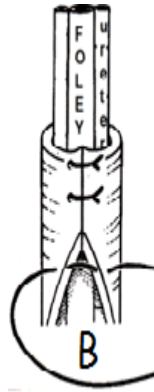


Fig. 4.4a: Closing the junction of the urethra to the bladder. Stitch 1 is shown in black and stitch 2 in white.

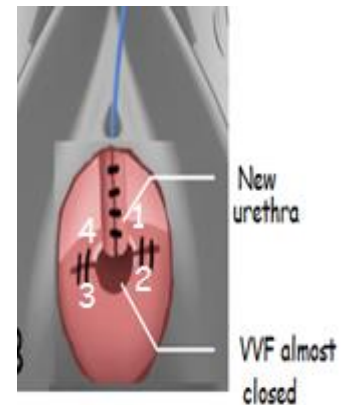


Fig. 4.4b: This shows a mattress suture (1,2,3,4) being used to join the urethra to the bladder.

(4) Connect the urethra to the bladder:

- If most of the bladder is already closed, then either:
 - The simplest is to use a mattress as in Fig. 4.4b. If there are still gaps on either side, fill them in with simple interrupted sutures.
 - Use two separate sutures as in Fig. 4.4a. For both stitch 1 and 2: One bite is along the side of the urethra. It does not enter the urethral lumen. Another bite is along the central part of the (almost closed) bladder edge.
- Another option is to join the urethra to the bladder as in Fig. 4.2C i.e. before you close the bladder. Check with dye to ensure the closure is watertight. Make sure you reinforce the junction of bladder and urethra well, as this is often where breakdown occurs. (This is popularly known as the crying corner because you and the patient will cry when it leaks here!) Do this by repeating the junction stitch but taking very superficial bites.

(5) Intermediate layer:

Once the urethra is closed, in some cases, another layer can be made from the more superficial lateral tissue which is just under the perineal skin. The skin lateral to the urethral incisions has to be undermined well to provide access to this para-urethral fibromuscular tissue (bulbocavernosus).

! Tip! When taking bites of the intermediate layer, if you go too deep or lateral, you will end up in the periosteum. This can reduce the mobility of the tissues, leading to difficulty in bringing the two edges together. It is better to work slightly more superficial.

(6) Closure of the vagina over the repair

While the bladder may heal without skin cover, the urethra rarely does.

- (a) Use the surrounding skin: You may need to mobilize the vagina off from the lateral walls more extensively and then swing in the flaps towards the midline to close. See Labial flap chapter 8.
- (b) It is strongly recommended to make a Singapore skin flap (Fig. 4.5b) to cover the anterior vagina in these cases as there is always a deficiency in the skin. Any tension in closing the vagina will only lead to breakdown of the repair.

Irrespective of what skin you use to cover the urethra, distally stitch the new external meatus to the surrounding skin with a single everting stitch (Fig. 4.5a).

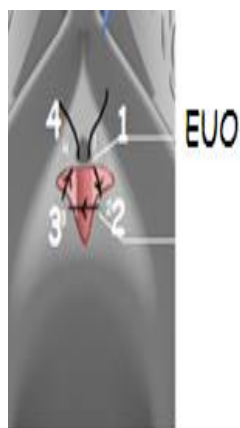

Fig. 4.5a: Shows the everting stitch to close the urethral meatus and to prevent meatal strictures.

- First bite: start inside the lumen of urethra and come out.
- Second bite: the skin from into out as shown.
- Third bite: skin on the other side from out to in.
- Fourth bite: goes back into the urethral lumen.

The two ends (1 and 4) are then tied together so the knot ends up inside the lumen. This may cause problems initially if she needs to do self-catheterization or use a plug.

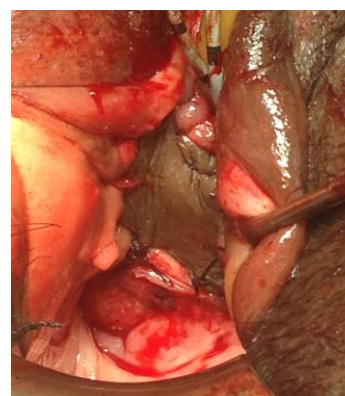


Fig 4.5b: Shows a Singapore flap used to cover the neourethra/ VVF repair.

(4.2) NEW URETHRA MADE FROM ANTERIOR BLADDER DURING VVF REPAIR

Overview of the procedure:

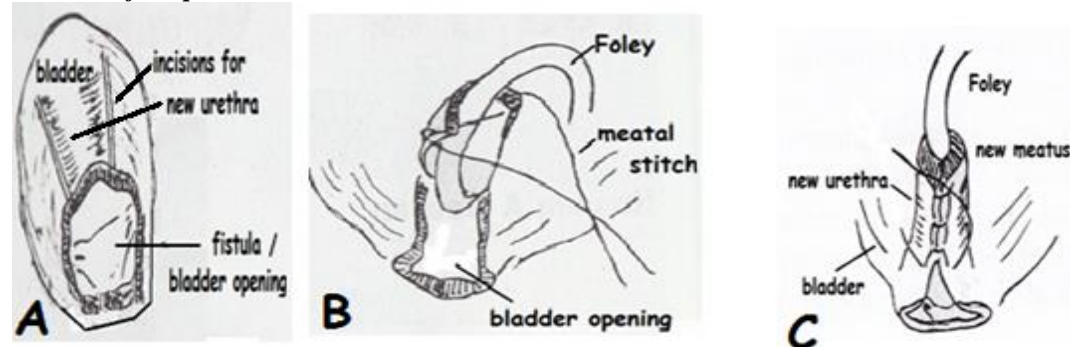
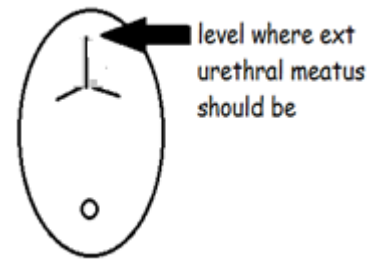


Fig. 4.6: Gives an overview of the operation. It shows the new urethra being formed from the anterior bladder. A: Two incisions are made. B: The meatal stitch is inserted around the catheter. C: The new urethra is closed. Note in this diagram the incisions are made before the meatal stitch, although it is easier to place the meatal stitch first and then make the incisions.


1. Prepare the urethral bed: Make a midline vaginal incision 2-3 cm long (Fig. 4.7a) where the urethra should be and extend this incision laterally and proximally on each side to form a triangular vaginal flap on each side. Stitch back these flaps laterally to aid exposure. These vaginal skin flaps can be used later to provide skin cover over the new urethra.

2. *Fix the bladder down:* The bladder must be stitched to the urethral bed. This is similar to the anterior layer of a circumferential repair.
 - The stitch path is from skin to periosteum and then bladder.
 - Place the first stitch at 12 o'clock going from skin and bony tissue over the former site of the urethra, and then to the anterior (distal) edge of the bladder i.e. to where the external urethral meatus should (and will) be.
 - Two more stitches are placed at 11 and 1 o'clock.

Fig. 4.7a: Shows the incision made to reflect the vaginal skin on each side. One flap is formed on each side.



3. *Form the meatus:*
 - Place the tip of a metal catheter into the bladder at 12 o'clock.
 - A transverse bite is taken on either side of (below) the catheter to bring the anterior bladder edges together and form the new external urethral orifice.
 - Keep the metal catheter in while placing the first stitch and then replace it with a Foley catheter before you tie the first stitch (Fig. 4.6B).
4. *Incise:* Make a vertical incision (Fig 4.6A) 2-3 cm into the bladder on either side of the midline which should be 3-4 cm apart or 1.5 cm on either side of the meatal stitch. The purpose of these incisions (when stitched together Fig. 4.6 C) is to narrow the bladder and form a narrow tube i.e. new urethra.

	The most common mistake in creating the new urethra is to not make the incisions far enough lateral to the midline. Remember, the new urethra has to wrap around a catheter in its full length without tension.
---	---

5. *Close urethra:* The new urethra is closed with a fine absorbable 3/0 suture. Stitch the urethra side to side (Fig 4.6C), taking good bites which makes the neo-urethra narrow.
6. *Close bladder:* The bladder is closed in whatever way it comes together easily which is usually longitudinally (Fig. 4.7b-D) but sometimes transversely (Fig. 4.7b-E). Sometimes it will close better with a legs closure (see section 2.4).

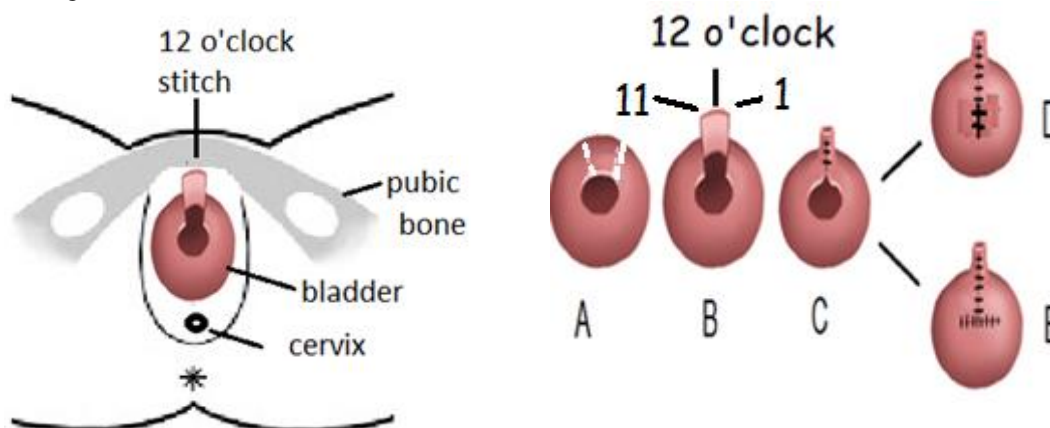


Fig. 4.7b: Shows how a tube is made from the anterior bladder and formed into a neo-urethra. In the diagram on the left, the position of the stitch at 12 o'clock which goes from the periosteum into the anterior bladder is marked on the periosteum. The 11 and 1 o'clock stitches are marked on the bladder only in B. In A: the incisions in the bladder are outlined. In B, the flap is being stitched back to form the anterior wall of the neo-urethra. In C, the posterior neo-urethra is closed. In D and E, the bladder is closed.

7. *Where possible take steps to reduce the risk of stress incontinence:*
 - a. Consider doing a pubo-coccygeal sling as described in section 1.4b.

- b. Some surgeons re-suspend the new urethra back behind the pubic symphysis with a separate stitch on each side (Fig. 4.8). With a PDS or Vicryl suture, take a bite of the periosteum and then take a bite of tissue on the side of the new urethra and tie it (see also Fig. 6.4). This is only possible if there is (pubo-cervical) fascia which is plicated across the midline and then fixed to the periosteum.

- c. Some surgeons place a Martius graft over the repair which may allow for a sling later.
8. *Fix the meatus:* The new meatus is sutured to the skin so that it does not retract.

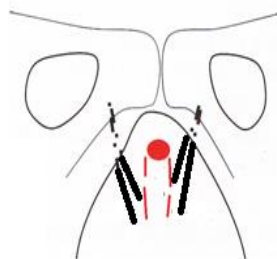


Fig. 4.8: Re-suspension of the new urethra to pubic symphysis.

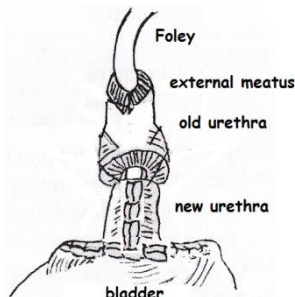
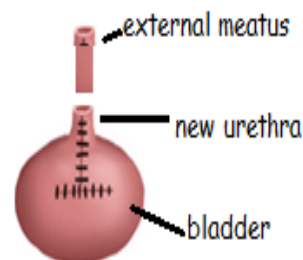


Fig. 4.9 a + b: Show the new meatus being joined to an old short urethra.



To lengthen a very short urethra: (see Fig. 4.9 a + b) If you make a new urethra to join to a very short urethra, you do an “end-to-end” anastomosis of the new urethra with the old.

- *Anterior layer:* Fix the bladder to just proximal to the short urethra with stitches at 12, 11 and 1 o’ clock. It is a good idea to also place the 10 and 2 o’clock stitches as these will be difficult to place later. Note that these are the same steps as when doing the anterior layer of a circumferential repair.
- Now place the “meatal” stitch and make the incisions to form the urethra as described above.
- *Posterior layer:* Place several interrupted sutures to join the new urethra to the old.

(4.3) LENGTHENING A SHORT URETHRA FROM THE ANTERIOR VAGINAL WALL WITHOUT (OR FOLLOWING) VVF REPAIR

In cases where there is a very short or no urethra, a new urethra can be made from the vagina by treating the old urethral/ bladder opening like a fistula. The technique is similar to that described in section 4.1.

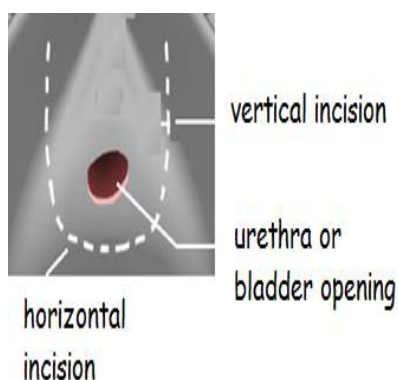


Fig. 4.10a: Shows the U incision in the vagina for forming a new urethra.

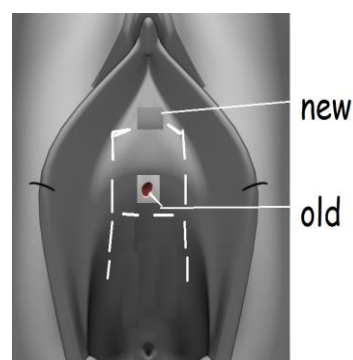
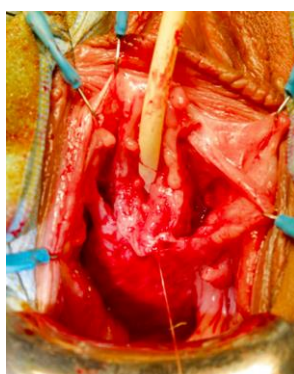


Fig. 4.10b: This shows an alternative H incision.

(1) Incision: Either a U (Fig. 4.10a) or H (Fig. 4.10b) incision can be made.

Horizontal incision: The success of this operation is dependent on the first incision, which is a horizontal/transverse proximal one. If this incision is not 2.5-3 cm wide the risk of failure is very high. The incision is placed just below the external urethral orifice (EUO) or if you are incorporating a small fistula (see Fig. 4.11)

it should be just below the fistula. Do not worry about the incisions being far away from the edge of the urethra/fistula at the sides. It is only necessary to be close in the midline proximally.

Vertical incision: (deep and lateral) Two vertical incisions are made, ensuring that they are not too distal (3 cm is typically sufficient). The incision should not extend further than the anterior edge of where the EUO should be. Cut deep into the tissue which often results in bleeding, that may need to be sutured.

In the H incision (Fig. 4.10b), the distal part (above the horizontal incision) allows the urethra to be reconstructed. The proximal part (below the horizontal incision) when mobilized, will free a flap of vagina which can be advanced distally to cover over the urethra (see Fig. 4.10 h+ i). However, it is still easy to form an advancement flap with the U incision.

(2) **Dissection:** Start the dissection at the transverse incision (proximally).

Hold an Allis forceps on either side of this incision. Be careful as you dissect in order to avoid entering the bladder, as often there has been a previous fistula repair. The general rule is to stay close to the vaginal skin, as it is better to make a hole in the vagina than a hole in the bladder. The vertical incisions are dissected as described in section 4.1.

! Tip! When separating the vagina from the bladder, to avoid button-holes, you should pull upwards (distally) rather than backwards (towards yourself) on the vagina.

(3) **Closure of the urethra:**

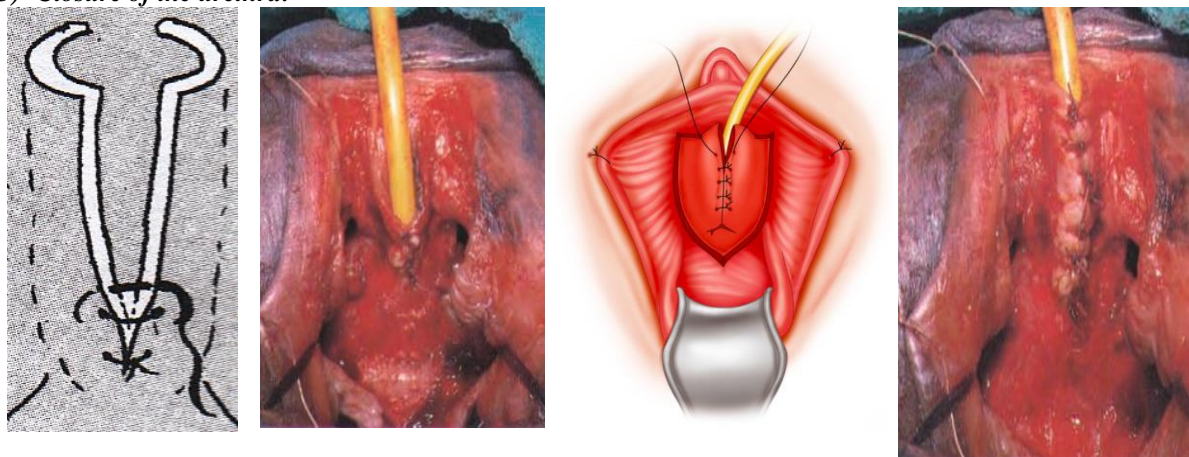


Fig. 4.10c: Shows the closure being started proximally. Courtesy of Sayeba Akhter.

Fig. 4.10d: Shows the closure completed. Photographs courtesy of Kees Waaldijk.

The difficult part is the proximal angle. This is done as a single angle stitch taking three bites (Fig. 4.10e).

- Once the proximal angle is closed, the rest of the urethra is closed side to side (longitudinally) working from proximal to distal. These sutures are placed transversely or obliquely (Fig. 4.10 c+d).
- Check as you place each suture that there is no mucosa or tissue protruding out between sutures. This is best done by getting your assistant to hold up the tied suture before you cut it.
- Also, check with a Hegar 8 or a narrow metal catheter that the urethra is patent after each suture. Alternatively, you may keep a narrow metal catheter in place until the whole urethra is reformed and then replace it with a Foley catheter. Usually, only one layer closure is possible.

(4) **Re-fixation of the fascia:**

Once the urethra is closed, look for the pubo-cervical fascia in the proximal flap in front of the cervix (see Fig. 4.10f). If it is present, then re-attach this fascia to the pubic bone with two sutures on each side (see Fig. 4.10g). The re-attachment of the fascia is critical to making the patient continent as it compresses the neourethra. In cases of VVF where the urethra is absent, this fascia is often absent.

- 1st suture (Para-urethral): this is placed at about 10 and 2 o'clock on the pubic arch.
- 2nd suture (Para-meatal): this is placed at about 11 and 1 o'clock on the pubic arch. Go from the periosteum just lateral to urethra down to take a bit of the fascia. This suture often covers over the urethral repair. Small transverse incisions can be made into the periosteum to help the fascia stay attached long-term.

(5) Closure of the vagina:

Either use a Singapore flap as described in Section 8.1 or use the vaginal advancement flap to come up and cover the urethra (Fig. 4.10h).

- If the skin is deficient, a Singapore flap is useful. It has the advantage of encouraging healing.
- If there is sufficient skin i.e. you are using an advancement flap, place (but do not tie):
 - Two medial sutures which are from the distal edge (apex) of the flap to the meatus on either side. These are marked 1 and 2 in Fig. 4.10i.
 - Two lateral stitches: these go from the skin distally, then bite the periosteum, then some pubo-cervical fascia and then the edge of the flap laterally near the cervix. These are marked 3 and 4 in Fig. 4.10i. The deep bites are taken to avoid tearing of the vagina. You mattress these sutures so go back up to the distal vagina and tie.

Note: While a bladder repair may heal without skin cover, a urethral repair does not.

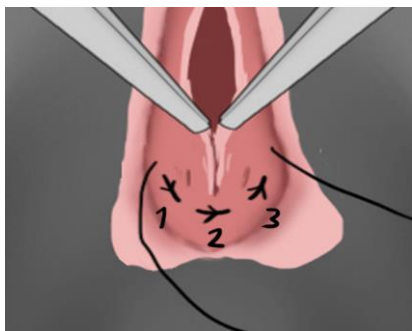


Fig. 4.10e: When closing the proximal corner, pick up the tissue in the midline (2) to prevent strictures developing. Get your assistant to hold each corner (1 and 3) with pickups. Then as you tie, the assistant can push these two corners inwards.

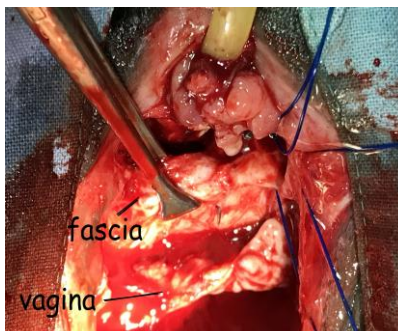


Fig. 4.10f: Shows the pubo-cervical fascia (held in Allis forceps) which is found deep to the proximal vaginal flap. It is about to be re-attached to the pubic bone anteriorly. In cases where the main injury is to the urethra, the fascia is usually well preserved as seen here.

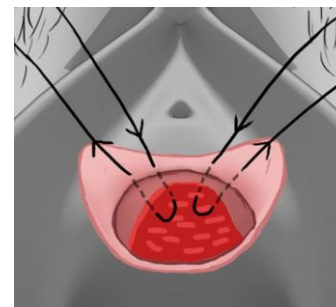


Fig. 4.10g: Shows the reattachment of the fascia to the periosteum. This adapts the posterior urethral wall to the anterior urethral wall which is critical for continence.

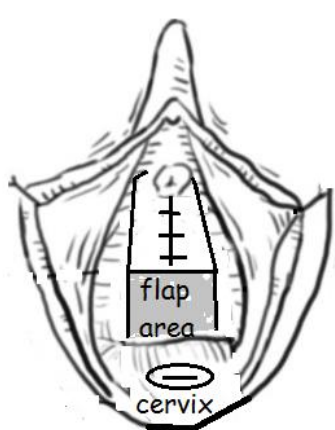


Fig. 4.10h

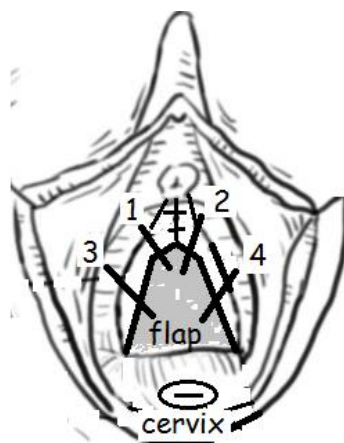


Fig. 4.10i

Vaginal advancement flap:

Fig. 4.10h: Shows the shaded area of vaginal skin before it is advanced distally to cover over the urethra.

Fig. 4.10i: Shows the flap now advanced to cover the new urethra. Two sutures are inserted on each side = 1,2,3,4. As long as the ratio of the base to the length is 1:2-3 then the flap will be viable.

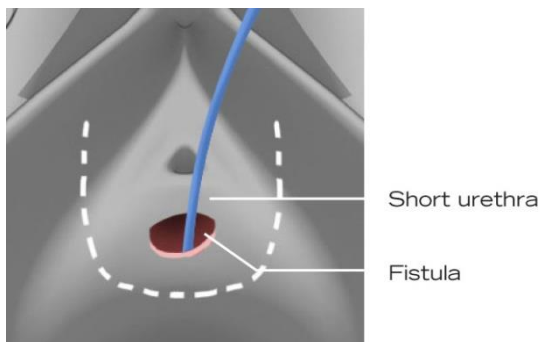
Summary of making a new urethra:

- Form the new urethra. Then where possible the para-urethral tissue is sutured as a 2nd layer over the urethra by approximating it in the midline. It is not always possible to get this second layer.
- If present, re-attach the pubo-cervical fascia to the periosteum.
- Vagina: either use an advancement flap (Fig. 4.10i) or bring in a Singapore flap (section 8.1).

! Top Tip! A firm (Nelaton) catheter without a balloon can be used when you have re-constructed the urethra. As there is no balloon channel, it allows a wider diameter for urine to drain and so it is much less likely to get blocked. Also, because it is firmer, it is easier to insert. However, it needs to be secured carefully with a suture just above the urethral meatus to prevent it falling out. (See also Appendix 5.)

Post-operative care after creation of neo-urethra

- The catheter is usually left in for 10 days, which helps the new urethra to canalize. The Foley catheter acts as a stent for the new urethra as it heals. The patient may require a catheter for a longer duration if she is unable to void and presents with urinary retention. The stitches around the urethra make it too painful for the patient to learn self-catheterization.
- If you have made a new urethra and the catheter becomes blocked post-operatively, consider inserting a supra-pubic catheter instead of removing the urethral catheter, as any urethral trauma may jeopardize your repair.



If there is a fistula close to a very short urethra:
In some cases, there is just a rim or bridge of urethra remaining distal to the fistula as in Fig. 4.11. In such cases, a good option is to incorporate the fistula into a new urethra i.e. you do not close the VVF directly but it is closed over by the formation of the new urethra.

Fig. 4.11: Shows a fistula close to a very short urethra.

(4.4) FISTULAS DISTAL TO THE URETHRAL ORIFICE

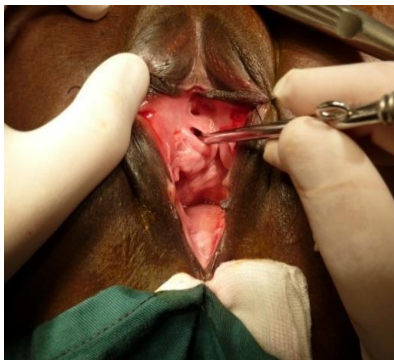


Fig. 4.12a: The metal catheter is in the normal urethral opening with the fistula seen above (distal to) it. Close up shown in Fig. 4.12b

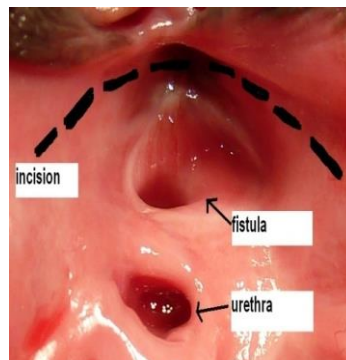


Fig. 4.12b: Shows the supra-meatal incision made to free the fistula off the pubic symphysis.

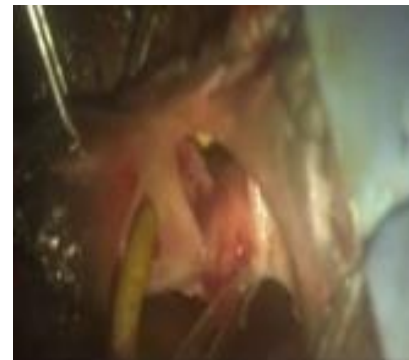


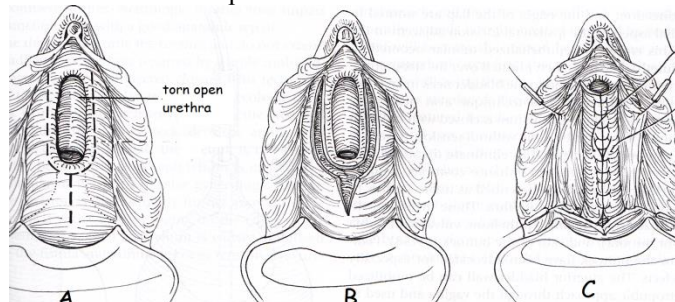
Fig. 4.13: This is another example of a post-symphysiotomy fistula to the left of the urethra. The metal catheter is in the urethra.

Occasionally you will be faced with a fistula which involves the anterior urethra. Most of these are caused by a previous symphysiotomy (Fig. 4.12 and Fig. 4.13). The approach to this type of fistula is to dissect around the fistula under the pubic arch (supra-meatal incision as shown by interrupted black line in Fig. 4.12b) similar to what is done during circumferential dissection. Once mobilized, the fistula is closed.

If during the dissection troublesome bleeding is encountered, cautery or suturing is not usually needed. All that is usually necessary is to place a gauze pack between the urethra and pubis, extending into the retropubic space for compression.

(4.5) MANAGING THE TORN URETHRA AND URETHRAL STRICTURES DUE TO NON-OBSTETRIC TRAUMA
THE TORN URETHRA

This may occur following a previous repair of a VVF or from a childbirth injury. It often seems like an 'absent urethra' on initial inspection.



The urethral bed has a red (transitional epithelium) appearance in comparison to the pink vaginal epithelium. A U-shaped incision is made, but it is at the junction of the (pink) vagina and the (red) urethra (Fig. 4.14A). The vagina at the sides is mobilized off and sutured laterally for exposure. The urethra is then closed, starting either proximally or distally and inserting a 14F Foley catheter.

Fig. 4.14: Shows a torn urethra being repaired.

URETHRAL STRICTURES DUE TO NON-OBSTETRIC TRAUMA

These cases are seen occasionally in fistula centres so it is useful to know how to manage them. Most of the ones I have seen have been caused by pelvic fractures.

Dilation: With any strictures, try dilating from below first. You need a narrow probe initially and then sequential dilators. Lubricate the dilators well before inserting. You should not push too hard as it is easy to make a false passage and then it is very difficult to find the way.

- In an adult, dilate to 16/18F in the anticipation that there will be some re-stenosis. If you only dilated to 12F it would probably narrow to an obstructive diameter fairly quickly.
- Dilation itself causes injury to the urethra resulting in a stricture so over-dilation is potentially harmful.
- Bleeding can occur without much dilation and is not a sign of over-dilation.

Suprapubic cystotomy: If you fail to dilate from below, under direct vision, make a suprapubic cystotomy and pass a sound or dilator from above down through the internal urethral opening. It helps to put a finger in the vagina from below as a guide. Alternatively, if you fail to dilate from above, you can dilate from below but put your finger into the bladder to guide the dilator up through the internal urethral opening. Then leave in a urethral and suprapubic catheter. After 7 days remove the urethral and clamp the suprapubic catheter to ensure she voids. If she voids well for two days, remove the suprapubic catheter.

Catheter post-dilation: The purpose of leaving in a catheter after dilating is not to prevent re-stenosis i.e. it will not keep the urethra open so that it heals wide. It is to reduce leakage of urine into the tissues. Therefore depending on the amount of trauma during dilation: (a) If minimal, leave the catheter in for one day (b) if a lot, leave in for three days (c) if perforation of the urethra, leave in for seven days.

Follow-up: Even if you manage to dilate the stricture, there is a high chance of recurrent stricture. An adult can do weekly self-catheterization to dilate. In a child, do it under anaesthesia after 2 months to determine how active the stricturing process is. If the urethra has not narrowed, then a longer time interval is possible and recurrent stricture is unlikely. If it is narrow again, she will need regular dilation i.e. every 3 months. Warn the patient (or her relatives) not to wait until passing urine is very difficult as the stricture will then be very tight and more difficult to dilate.

Distal stricture: Localized strictures within 5-10 mm of the meatus can be managed by circumferential excision of the distal urethra and meatus (*see Fig. 6.10c*). Then the healthy urethra is advanced and sutured circumferentially to the vaginal epithelium with interrupted sutures.

Other surgical treatment: see section 6.5.

CHAPTER 5

ABDOMINAL REPAIR OF URO-GENITAL FISTULAS

Section 5.1: Intra-peritoneal approach
Section 5.2: Interpositional layer
Section 5.3: Extra-peritoneal approach
Section 5.4: Combined abdomino-pelvic approach

INDICATIONS FOR ABDOMINAL REPAIR

Although the great majority (over 95%) of uro-genital fistulas can be closed vaginally (resulting in less morbidity), you may have to use an abdominal approach in the following situations:

1) *Decision is made before beginning surgery:*

- None of the fistula (VVF) is visible vaginally i.e. the fistula is high or lateral i.e. out of sight.
- If the proximal end of the fistula cannot be reached vaginally.
- A third group which includes any high fistula which can be approached vaginally or abdominally depending on the experience of the surgeon.

Abdominal repair is more often required with iatrogenic/surgical fistulas (following hysterectomy, Caesarean section, or rupture of uterus and bladder) than with fistulas resulting from prolonged labour. However, vault fistulas following hysterectomy can usually be managed vaginally.

2) *Decision is made during attempted vaginal repair* (see section 5.4) if:

- You fail to either mobilize the fistula i.e. you fail to bring the fistula down or reach the proximal end.
- One of the ureters needs to be re-implanted abdominally and the VVF is high, it may be simpler to repair the VVF abdominally.

3) *Miscellaneous:*


- Bladder augmentation is needed.
- An incorrect diagnosis of a ureteric fistula is made pre-operatively and on abdominal approach, when the bladder is opened, a small VVF is seen.
- There is another indication that requires laparotomy e.g. if the patient has a high fistula and also has an incisional hernia which needs to be repaired (can be performed at the same time).

APPROACH

There are two different approaches to trans-abdominal repair: intra-peritoneal and extra-peritoneal. Which one you use mainly depends on the size and accessibility of the fistula and your own preference. Generally, it is worth attempting the extra-peritoneal approach initially, switching to intra-peritoneal approach if necessary.

- *Extra-peritoneal:* The advantages of extra-peritoneal approach are less risk of infection (peritonitis), less risk of bowel injury especially if there are extensive adhesions and less risk of ileus.
 - If the fistula is small and accessible, you can avoid splitting the bladder down to the defect.
 - If the fistula is large, split the bladder down to the fistula to allow better access.
- *Switch to an intra-peritoneal approach* and (in most cases) split the bladder posteriorly if:
 - You have poor access to the fistula or the bladder is very small.
 - The tissues are very fibrotic and you want to bring in an interpositional flap e.g. omentum. However, it is possible to place an interpositional flap with the extra-peritoneal approach using the rectus muscle.
 - The ureter needs to be re-implanted.

The abdominal wall incision made is usually midline for an intra-peritoneal approach and transverse for an extra-peritoneal approach.

 **Tip! (Cherney incision)** If the exposure is inadequate with a transverse incision, you can cut the tendons of the recti muscles bilaterally 1-2 centimeters above the pubic symphysis. Do this after bluntly dissecting with your fingers to separate the tendons from the bladder before cutting. This greatly improves exposure. When re-fixing the muscle at the end of the operation, it helps to pull the muscle (with an Allis forceps or your fingers) towards the periosteum as you tie a mattress suture to re-approximate the muscle back to the periosteum.

(5.1) INTRA-PERITONEAL APPROACH

The intra-peritoneal approach is similar to the repair of a ruptured bladder which often occurs with a uterine rupture.

Preparation

- The patient is placed in the low lithotomy position with almost no flexion of the hips. The advantages of this position are:

- It allows a second assistant to stand between the patient's legs.
- It also allows access to the urethra and vagina if needed.
- A Foley catheter is passed through the urethra into the bladder observing strict aseptic technique. There are two reasons to do this at the beginning rather than after the operation:
 - The balloon of the Foley helps in identifying the bladder when opening the abdomen/ bladder.
 - Placing the catheter aids identification and protects the internal urethral meatus from occlusion by sutures if the fistula is nearby.
- You may also insert both ureteric catheters through the urethra before opening the abdomen. They can be fixed at the lower end to the drapes with artery forceps to prevent them from being expelled. If there is difficulty inserting the ureteric catheters, push the balloon of the Foley well into the bladder or insert them before you insert the Foley.
- The right-handed surgeon stands on the patient's left as with any pelvic operation.
- Enter the peritoneal cavity through a midline incision.
- If the uterus is still present, it can be pulled up out of the way by placing a stay suture directly on the uterine fundus. Take two bites and tie. Then secure the suture to the bar of the self-retaining retractor and tie it tightly. When this is removed at the end of the operation, cut above the knot to avoid bleeding from the uterus.

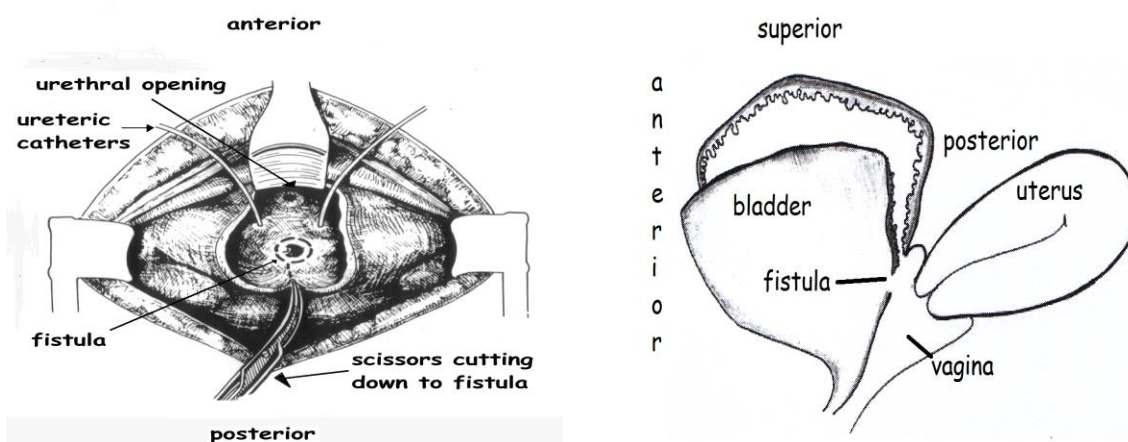


Fig. 5.1a: Overview of operation showing anterior/ posterior(AP) and lateral views of the splitting of the bladder down to the fistula.

- ◆ The bladder is opened in an AP direction and the fistula exposed as shown.
- ◆ The urethral opening is identified by the presence of the Foley catheter (not shown for clarity).
- ◆ The ureteric openings are located about 2-4 cm proximal and lateral to the urethral opening and urine can be seen coming out intermittently. If no urine is seen, give frusemide 10-20 mg IV along with intravenous fluids.
- ◆ The fistula is usually in the area of the trigone or above the trigone in the image on the left. In some cases, especially following rupture of the bladder, the fistula may extend from the fundus of the bladder to the internal urethral meatus.

STEPS OF THE OPERATION

Note: As shown in Fig. 5.1a, nearly all uro-genital fistulas involve the posterior wall of the bladder so that is where the fistula will be found.

(Step 1) Split the bladder down to the fistula:

Grasp the top of the bladder in the midline between two Allis forceps or two stay sutures. Split the bladder vertically in an A-P direction between the two Allis forceps (Fig. 5.1c). You can cut with scissors or cautery (use coagulation mode). If large arterial bleeding occurs, pick the vessels up with artery forceps. The incision in the bladder will partly be intra and partly be extra-peritoneal.

! Tip! It is often difficult to outline the extent of the bladder for a properly placed entry incision. It helps to grasp the Foley balloon through the bladder wall with two or three fingers and elevate the balloon to the central midline aspect of the bladder. This will give you an idea how large the bladder is and allows you to enter the bladder at the best location for repair. This is especially helpful if the bladder is very small. (An extra tip is to grasp the Foley before opening the bladder through the bladder wall below the balloon with a Babcock forceps so that it does not slip down.) While grasping the Foley balloon and elevating anteriorly, place Allis forceps by grasping the bladder with good bites on top of the balloon. An incision can be made between the Allis forceps

with easy entry into the bladder. Be careful not to puncture the balloon, or it will need to be replaced. However, balloon puncture virtually ensures that you are in the right spot!

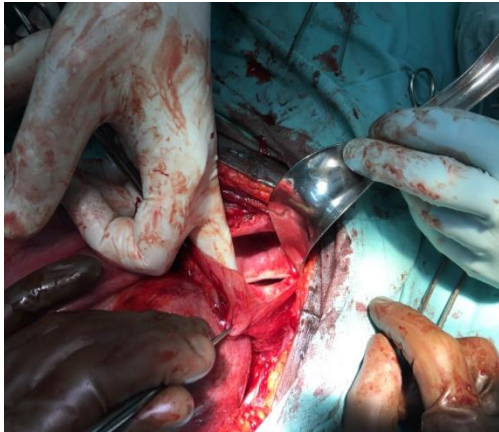


Fig. 5.1b: Shows the bladder split open revealing a large fistula with white edges. Note the Sims speculum being used as a retractor suprapubically.

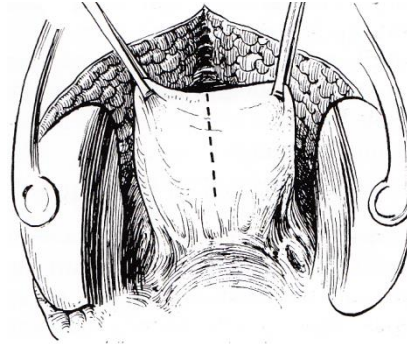


Fig. 5.1c: Shows the line of incision on the bladder which is vertical. The fundus of the bladder is stretched between two Allis forceps. (From *The Vesico-vaginal Fistula: J Chassar Moir. 1967*)

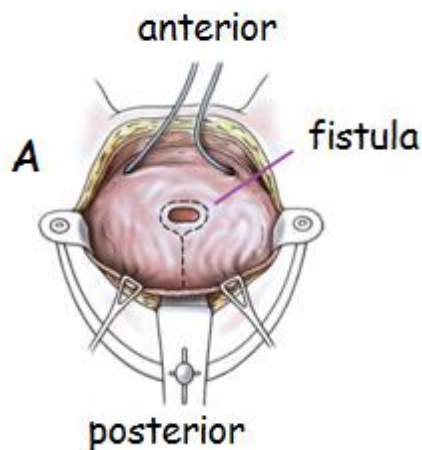


Fig. 5.1d A: Shows the incision on the posterior bladder wall with a midline split made from the dome of the bladder, and extended downward in a racquet-shape around the fistula.

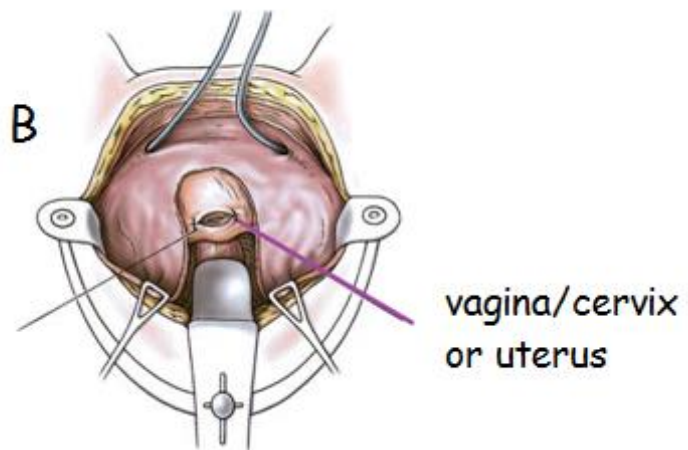


Fig. 5.1d B: The vaginal or cervical defect is being closed in a single layer; the bladder is then closed in either one or two layers. Adapted from *An atlas of gynecologic oncology, investigation and surgery: Chapter 30 Fistula Repair: Paul Hilton.*

Retractors:

- A Sims speculum may be used but is not ideal as the curve on the blade takes up quite a lot of space in the bladder. A better option is a small Deaver retractor which can be placed inside the bladder on the anterior wall (Fig.5.1a) to view the ureteric openings.
 - Another retractor to retract the posterior bladder wall may also help.
 - If the bladder is large enough, it may be possible to insert the self-retaining retractor into the bladder lumen as in Fig. 5.1d.
- (a) *The posterior bladder wall:* As you cut, you will first reach the utero-vesical fold. Open this, and free the bladder from the uterus if not already done. The splitting of the bladder is continued down the posterior wall until you reach the fistula. By staying in the midline, you avoid the ureters although you should note their position (see step 2). Cut around the hole of the fistula using a racquet-shaped incision (see Fig. 5.1dA).
- (b) *The anterior wall:* How far you cut down the anterior wall depends on the exposure required. Once the bladder is open sufficiently, it helps to pull the balloon of the Foley catheter up out of the way so that you can see the fistula and the ureteric openings. Only pull up the Foley catheter after you have cut down the


anterior wall sufficiently. To keep the catheter out of the way, clamp it directly with artery or towel forceps to the drape.

(Step 2) Catheterize the ureters once the bladder is open sufficiently. Catheterization of the ureters enables you to feel for them as you dissect the bladder off the vagina and this may reduce chances of injuring them.

- If you have difficulty catheterizing the ureters, place a Babcock or Allis forceps below the ureteric opening and pull upwards. This gives you control of the opening and makes it easier to catheterize.
- If you are using the common ureteric catheters or an infant feeding tube to catheterize the ureters, there is a strong tendency for these to fall out. Therefore fix these in place with an absorbable suture by taking a bite of the bladder mucosa near the ureteric orifice (and tie a knot) and then tie around the catheter and tie to the knot on the bladder mucosa. It also helps to fix the catheters (if they are going to be kept in post-operatively) to bring them out through the bladder wall now.


! Tip! Often the best way to avoid a ureteric catheter coming out from the ureter during the operation is to transfix it with a fine needle and absorbable suture.

! Tip! When you have opened the bladder and cut down to the fistula, you should infiltrate vasoconstrictor adrenaline solution where you plan to separate the bladder from the vagina/cervix. Stay within the bladder wall while injecting i.e. you should see the bladder mucosa swelling if you are infiltrating in the correct place. By reducing the bleeding as you dissect here, this will make the operation much easier. If there is bleeding as you dissect, infiltrate more solution.

	If one or both ureters are in the edge of the fistula, consider re-implanting the ureter. This will allow you to get a better closure of the bladder. There is also a risk that the distal ureter may necrose if you include it in the bladder closure.
---	---

(Step 3) Separate the bladder from the vagina around the fistula to allow closure of both. The bladder is sharply dissected from the vaginal wall for 1-2 cm distal to the fistula site. This may be difficult at the lower end where spreading with scissors may help to separate the vagina from the bladder.

! Tip! In trying to distinguish the bladder from the vagina, remember that the bladder wall is thicker than the vaginal wall which is about 3 mm thick.

	Be careful not to injure the ureters when dissecting the bladder off the vagina, as this is often the site of ureteric entry into the bladder. The ureter runs for 1.5 - 2 cm through the bladder wall before entering the trigone. If you are standing on the left side, the left ureter is more at risk as it is not so easily seen. The only way to avoid them is to palpate for the ureteric catheters carefully as you dissect. Anatomical distortion from the primary injury is common, placing the ureters at additional risk.
---	---

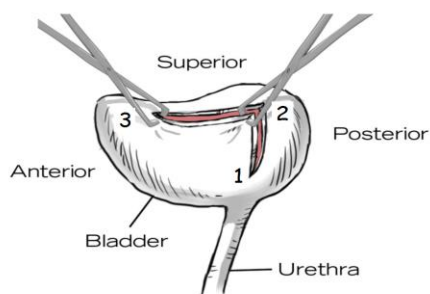


Fig. 5.2: External view of the bladder. The pink area is the open part of the bladder with the inner lining of the bladder exposed.


- The posterior wall defect lies between points 1 and 2.
- The superior wall defect lies between points 2 and 3.
- The ureters are usually located close to point 1 and are usually close to the balloon of the Foley.

! Tip! The ureteric catheters should be firm enough so that you can palpate them easily through the bladder wall, which is very important to avoid injuring the ureters.


(Step 4) Closure of the vagina: Close the vagina with interrupted sutures (Fig. 5.1d B). These should be placed a little back from the edges, to invert the vagina. Keep two (double) ends long to use later to suture to the omentum (see Fig. 5.3a). When a hysterectomy is being done at the same time, it is best to suture the vault open with a locking purse-string suture to allow any possible haematoma to drain.


An **interpositional layer** should be placed now if it is considered necessary (see section 5.1B below).


(Step 6) Closure of the bladder wall: this is usually done in two layers. Start the closure at the lower end of the bladder (Point 1 in Fig. 5.2). Then work up the bladder wall to point 2 to close the posterior wall. The posterior wall is the part most likely to leak so you have to take special care (Fig. 5.1e).

 Top Tip! The key is to do two layers of the bladder together; otherwise it may be difficult to get a 2 nd layer in later. Place an outer and inner suture at point 1 in Fig. 5.2. Then focus mainly on the outer layer as this is more difficult to do. Continue the inner layer after you have placed several sutures of the outer layer.	
Outer layer:	Done from the outer aspect of the bladder. Take mainly the muscle layer. Use 2/0 Vicryl suture.
Inner layer:	Done from inside the bladder. It is mainly mucosa that you take. Use a continuous 3/0 Vicryl suture. Place the first suture at distal apex but do not tie it. Then start the outer layer. Only tie the first bite after you have placed several sutures of the outer layer.
For both layers:	There are two options:(a) <i>Continuous suture</i> : is performed in most cases. (b) <i>Interrupted sutures</i> : as it is not so easy to maintain tension with a continuous stitch.

One layer closure: If the bladder wall is very thin or access is very difficult, you may have to settle for a one layer closure taking full-thickness bites done from the inside of the bladder. This is often the case when repairing a ruptured bladder in association with a ruptured uterus. Bites are taken 1 cm from the edge, full thickness. The sutures should be pulled tight enough so that it is water-proof but not so tight that you make the repair ischaemic. If necessary if the lower part is difficult, several interrupted sutures can be placed.

 **Tip!** When using a continuous stitch, it is critical to keep the suture tight. The key to keeping the suture tight is to grasp the suture your assistant is holding with the non-toothed dissecting forceps. Then pull it tight with your hand as you release the non-toothed dissecting forceps. Give the suture back to your assistant to keep tight.

 **Tip!** When closing the outer wall of the bladder, some surgeons use a backhand grip of the needle for stitching to give a better angle of access at depth i.e. start on the right side with a backhand grip and then the left also with a backhand grip. The knots end up on the outside.

 **Tip!** A long needle holder is very helpful if the repair is deep in the pelvis.

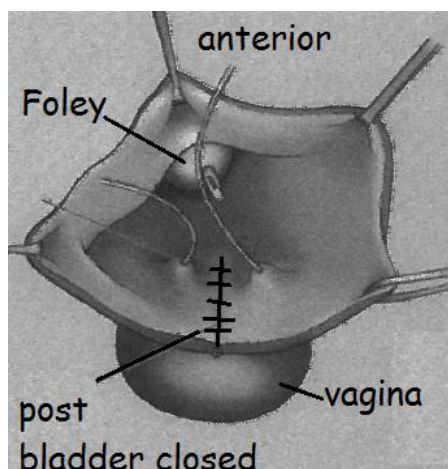


Fig. 5.1e: Shows the bladder from the inside with the posterior wall closed. The superior and anterior walls have yet to be closed (see Fig. 5.2).

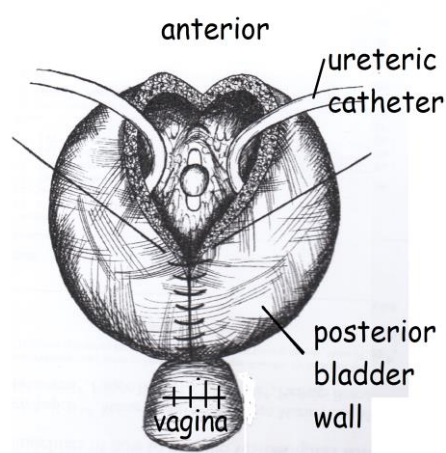


Fig. 5.1f: This shows a view from outside the bladder with the vagina already closed and the posterior bladder wall is now being closed.

Suprapubic catheters are not routinely used in abdominal repairs. While it is never wrong to use a suprapubic catheter, it is usually only considered where there is a high risk of breakdown i.e. in post-radiation cases, a difficult repair with possible tension or a thin bladder / poor tissue that you are unhappy with.

- In most repairs, one good size 18-20F urethral catheter is sufficient as this will block less easily.
- There is a greater tendency for haematuria following abdominal repairs which may be due to cutting through the normally vascularised anterior bladder wall.
- Post-operatively, if a suprapubic catheter was used, this can be clamped when the catheter is due for removal on day 14-21 and the urethral catheter removed. If there is any problem with urinating, the suprapubic catheter can be unclamped.
- The only disadvantage to a suprapubic catheter is the occasional leak from the track after removal of the catheter. A small leak of a few mls is common for a few days. If it is a large volume, then a urethral catheter can be re-inserted for 2 weeks to allow the track heal.

Ureteric catheters: At this point, the surgeon now has to decide on whether or not to keep the ureteric catheters in. If they are near the edge of the fistula repair they are left in. Otherwise, they are removed before fully closing the bladder. To leave the catheters in, bring the catheter out of the bladder either:

- Through a small stab incision in the anterior wall of the bladder or through one end of the bladder incision at point 3 in Fig. 5.2.
- Through the Foley catheter via the urethra: thread the ureteric catheter into the Foley catheter and then burst or deflate the balloon of the Foley in the bladder. While you hold onto the ureteric catheter, your assistant pulls out the Foley from below and re-inserts a (new) Foley from below.

Before completing the closure of the bladder, remove all blood clots from the bladder. Flush the catheter(s). Close the anterior/ superior wall of the bladder from points 2 to 3 in Fig. 5.2.

(5.2) REINFORCING THE REPAIR WITH AN INTERPOSITION FLAP

This step is thought to reduce the risk of failure, although it is not necessary in all cases. It may have its greatest advantage in post-radiation fistulas. It is also recommended during any intra-peritoneal repair. It is best placed after the vagina is closed but before closing the bladder. The choices are: (a) omentum (b) visceral peritoneum from the para-vesical area (c) rectus abdominis flap (d) newer options such as amniotic membrane or buccal mucosa graft.

(A) OMENTUM: If the omentum does not come down without tension, it needs to be mobilized (see Fig. 5.3 b + c). Once the omentum is mobilized, it is fixed to the vagina and bladder with three stitches (Fig. 5.3a). To fix the omentum, pass both ends of each of the three stitches through the omentum either with (a) a free needle or (b) an artery forceps which you can push through the omentum. When all three are passed, tie them down. Alternatively, the omentum can be pulled into the vagina and fixed from below.

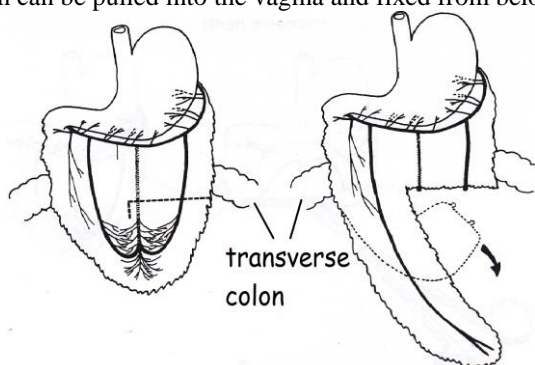
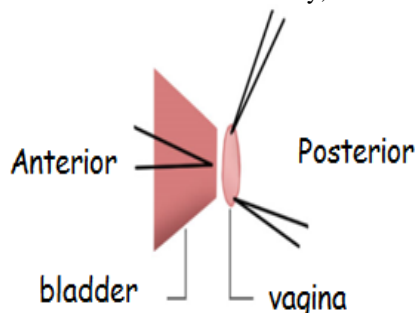


Fig. 5.3a: View from above showing the three stitches that are used for fixing the omentum between the vagina and bladder. The two on the vaginal angle have been placed to close the vagina and are left long.

Fig. 5.3b: If the patient has a long or normal length omentum but more mobility is required (it almost reaches the pelvis but not quite), an incision is made below the transverse colon. Just check that there are sufficient vessels in the part that you bring down to the pelvis.

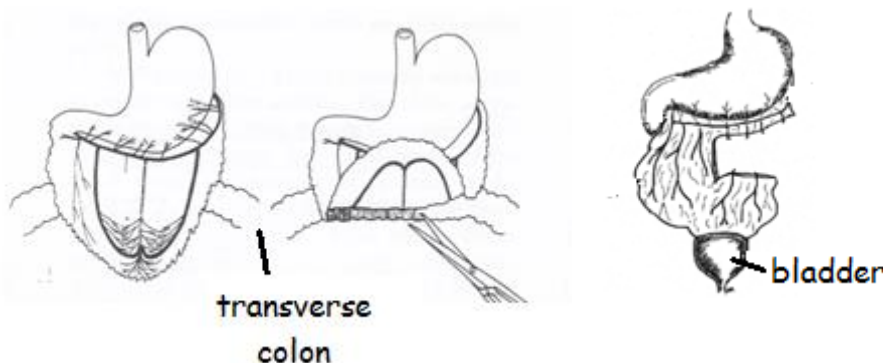


Fig. 5.3c: If the omentum is short (diagram on left), it is necessary to first mobilize it from the transverse colon as shown in the middle diagram. Then an incision is made close to the stomach to gain sufficient omental length to reach the pelvis. The figure on the right shows the omentum which has been partially divided on the left side and brought down to the bladder.

(B) RECTUS ABDOMINIS MUSCLE FLAP: Muscle is an excellent layer to interpose because of its vascularity and for this reason, it is preferred for recurrent or radiation-induced fistulas or where the omentum is inadequate or missing. The long arc of rotation of the inferior epigastric pedicle facilitates the positioning of the flap even low in the perineum. The blood supply to this muscle comes from three sources: (1) From above: superior epigastric artery. (2) From below: the inferior epigastric artery which originates from the external iliac artery. (3) Segmental vessels T7-12. Either the right or left side can be used. There are two ways of taking the rectus muscle:

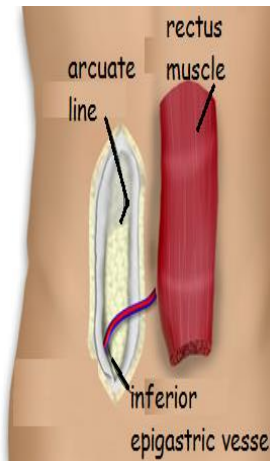


Fig. 5.3d: Shows the rectus muscle mobilized with its blood supply intact inferiorly.

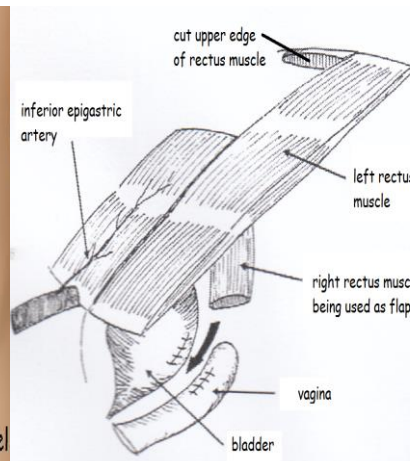


Fig. 5.3e: Shows the rectus flap on the right side about to be placed between the bladder and vagina.

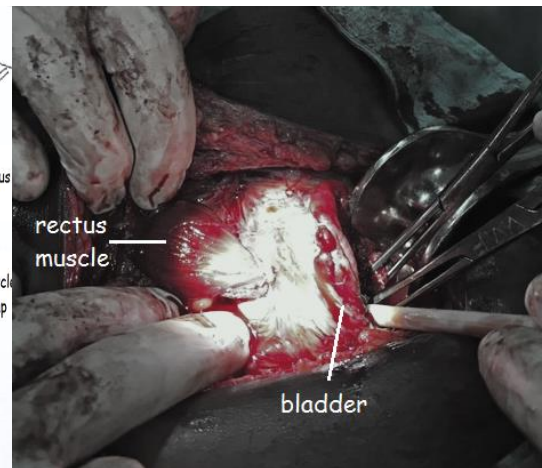


Fig. 5.3f: Shows the rectus muscle on the right, freed at the lower end and about to be swung behind the bladder. The white suction tip is in the bladder.

Short flap: The muscle is freed from the pubic bone. It is not usually necessary to divide any pedicle. The lower end is then swung in between the bladder and the uterus/ vagina (Fig. 5.3f). This is usually easy to do provided the muscle is not scarred and gives an adequate amount of muscle in most cases. As long as it reaches the fistula repair site with no tension on the pedicle, it should work well. However, in cases where there is a lot of scarring, it may not be possible to mobilize the muscle to get it to rotate sufficiently. It is therefore more suitable for vesico-uterine fistulas rather than VVFs.

Long flap: this gives a much longer flap of muscle.

- Make a vertical incision from above the umbilicus (midway between the umbilicus and xiphoid i.e. level with the lower ribs laterally) down to the symphysis. The longer the incision, the easier it will be to pull the muscle into the pelvis.
- The subcutaneous tissue is elevated off the anterior rectus sheath for 2-3 cm laterally. This will help with closure later.
- Separate the anterior and posterior rectus sheath, and then dissect the anterior rectus sheath laterally off the rectus muscle. Where the sheath is adherent at certain points, it must be dissected off the muscle without damaging the muscle fibers as the muscle is very thin in these areas.
- Once the dissection of the muscle has been completed to the lateral border, the muscle can be divided at a point half-way between the umbilicus and the attachment to the ribs.
- The muscle is then mobilized off the posterior rectus sheath above the arcuate line.
- The intercostal vessels entering the muscle laterally are divided. The inferior epigastric artery enters laterally on the deep surface of the muscle in the middle of the lower third of the muscle and can be seen running along the posterior border of the muscle. There is no point mobilizing the muscle below the insertion of the vessel as it will not gain any additional length.
- This leaves the muscle attached to its lower pedicle, the inferior epigastric vessels. The vessels enter laterally usually surrounded by yellow fat. By lifting the muscle up, the inferior epigastric vessels can be seen attached to the posterior surface of the muscle.
- The muscle is then swung into the pelvis and fixed around the fistula repair site. By attaching a suture to the lower end of the muscle, the suture is pulled into the vagina and the muscle is fixed in the vagina.

- The anterior and posterior rectus sheath is re-approximated in the midline with the fascial edge on the contralateral side. It is often helpful to separate the skin and soft tissues off the anterior sheath for a few centimetres on each side to allow for a precise closure.

Reference: VVF repair with Rectus Abdominis Myofascial Interposition Flap: Reynolds WS et al. In Urology 71 (6), 2008.

(5.3) EXTRA-PERITONEAL APPROACH

This alternative approach often avoids having to split the bladder open extensively and is simpler.

- The patient is placed in the low lithotomy position. It is often helpful to elevate the fistula site by a vaginal pack or place a swab on a sponge forceps which can be manoeuvred during the operation (optional).
- Foley (\pm ureteric) catheter is passed through the urethra into the bladder.
- The surgeon stands on the patient's left as with any pelvic operation.

INCISION

- It is preferable to make a transverse incision on the skin, even in the setting of a prior vertical midline incision (often present in these high fistulas which are usually iatrogenic). This is to avoid the scarring and adhesions from the previous midline vertical incision. The disadvantage of a low, transverse incision arises when ureteric re-implantation is necessary or you want to place omentum between the bladder and vagina. However, if this need arises, you can cut the recti muscles from the pubic bone to gain extra exposure (see Cherney incision page 75).
- Alternatively make a low midline incision and expose the retropubic space by separating the recti muscles.

!Tip! To stay extra-peritoneal as you open, push the scissors between the recti muscles close to the pubic bone. Then spread the scissors open. Then with the scissors still open, pull them out and insert a finger from each hand. Dissect with your two fingers of each hand deeply at first and then laterally so that you sweep any tissues off the muscle. The self-retaining retractor can be placed between the recti muscles to keep them apart. Later it may even be possible to place this into the bladder itself as seen in Fig. 5.4A.

The bladder is located by feeling the balloon of the Foley. The bladder dome is opened longitudinally with a midline vertical incision between two Allis clamps or two lateral stay stitches and the fistula exposed which is usually in the area of the trigone or above the trigone.

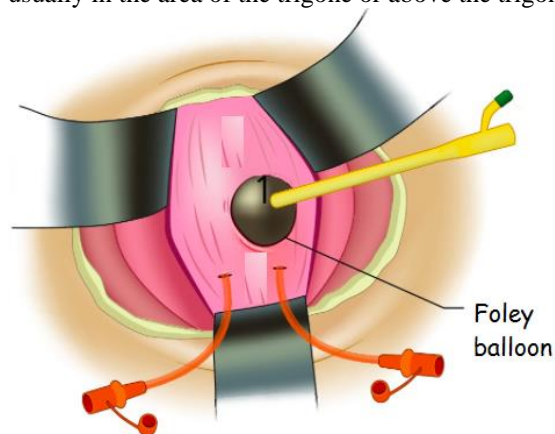


Fig. 5.4A: If the fistula is not too small, a Foley catheter can be inserted into the fistula to provide traction.

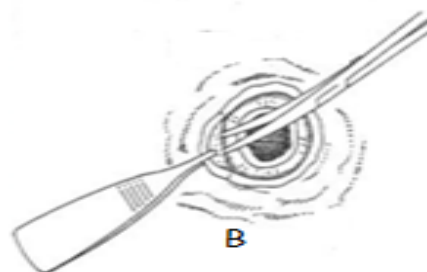


Fig. 5.4B: The bladder is being separated from underlying tissue. Thorek scissors which have a more right-angled tip can be helpful here.

EXPOSURE

- Place a self-retaining retractor between the recti muscle to keep them apart.
- Once the bladder is open, to improve the exposure, place a lateral stay stitch on each side and wrap each of these around the self-retaining retractor on both sides i.e. one end goes under the retractor and the other end goes over the retractor; then re-attach artery forceps to both ends. Clip close to the retractor for tension.
- A curved retractor can be placed in the fundus of the bladder to pull the bladder up. This has the effect of pulling the fistula site upwards.
- The ureteric orifices must be identified and preferably catheterized throughout the procedure. If they are involved near the edge of the fistula repair, the ureteric catheters are retained. Otherwise they are removed

on closure of the bladder. To ensure that they do not fall out during the operation, it is a good idea to transfix them with a fine needle.

- In small defects, only a metal catheter or probe, or a ureteric catheter can be inserted to confirm the site of the fistula.
- Inject diluted adrenaline solution around the fistula.
- To pull the fistula upwards, where possible, use both of the following:
 - Insert a Foley catheter into the defect, inflate the balloon (5-10 ml) and pull up on this (Fig. 5.4A).
 - Place 2-4 stay sutures to access and elevate the fistula. This is very useful in most cases.

DISSECTION + REPAIR

There are two options in dissecting the bladder off the vagina:

- a) **Work within the bladder** to dissect the fistula i.e. without splitting the bladder open.
- Incise around the fistula 2-3 mm from the edge with scalpel number 11.
 - The fistula edges are dissected into layers (Fig. 5.4b). In some cases this may be the uterine/ cervical wall with the uterine cavity opening into the bladder. In others, it is the upper vagina. The bladder is separated from the vagina 2 cm all around. Excessive dissection is not necessary. An angled dissecting scissors (e.g. Thorek) is useful.

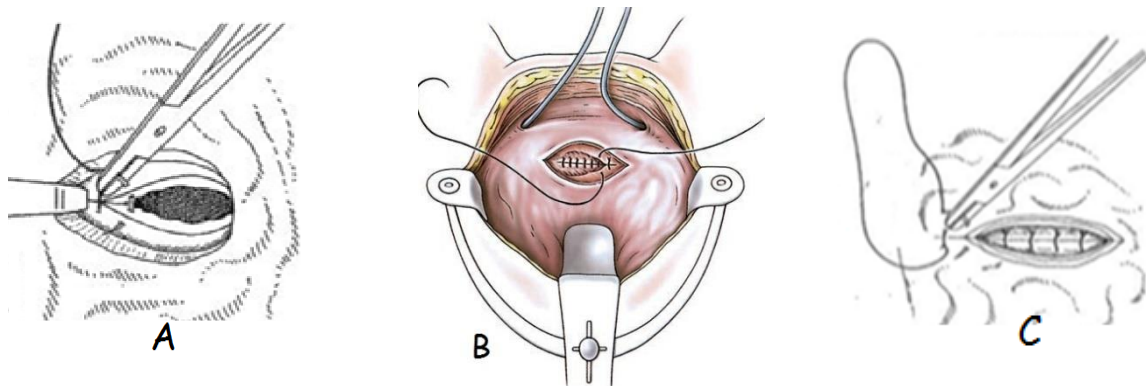


Fig. 5.5: A: Shows the vagina/uterus being closed with a single layer of (inverting) interrupted sutures.

B: Shows the deep layer of the bladder being closed with a layer of interrupted sutures, picking up the vagina and also to close any dead space.

C: A continuous suture is being inserted into the bladder mucosa for haemostatic purposes.

- (b) **Split the bladder:** if this gives you better access to the fistula although you may enter the peritoneal cavity in the process. If the bladder is split open, the closure of the bladder is performed as described for intra-peritoneal repair i.e. two layers of continuous sutures.

Tip! If you need to split the posterior wall of the bladder down to the fistula, it is worth bluntly dissecting any tissue (peritoneum) off the back of the bladder first. This will make it less likely that you will enter the peritoneal cavity.

Repair: The repair of each layer is done through the fistula and closure is usually performed in three layers starting with the deepest.

- Vagina or uterus:** The deepest layer is repaired with interrupted absorbable sutures (Fig. 5.5A). Leave the short ends of the angles on an artery forceps.
- Interpositional layer:** Rectus muscle (Fig. 5.3f) may be inserted now especially if there is an increased risk of breakdown e.g. tissues friable, urine infected.
- Deep bladder:** The next layer (the bladder wall) is exposed. A layer of interrupted or continuous submucosal sutures of 2/0 or 3/0 Vicryl is inserted (Fig. 5.5B). Secure each angle first and work towards the midline. Then tie both in the midline.

Tip! Leave the short ends of each angle of the deep bladder layer on an artery forceps as it may be difficult to see the angles of the (mucosa) fistula after this layer is tied.

- Superficial bladder:** 3/0 Vicryl: Lastly the mucosal layer is closed with interrupted or more commonly continuous sutures as this gives better haemostasis (Fig. 5.5C).

Note: some surgeons do all layers continuously. Sometimes only one layer (interrupted or continuous) is possible for the bladder closure as a second layer can affect the blood supply to the first.

- The dome of the bladder and abdominal incisions are repaired by the routine methods.
- It is important to remove all blood clots from the bladder before closure and ensure adequate drainage through the catheters. A suprapubic catheter is not necessary for uncomplicated repairs – usually one good size 18-20F urethral catheter is sufficient (see notes on suprapubic catheter with intra-peritoneal approach).

(5.4) COMBINED VAGINAL AND ABDOMINAL APPROACH

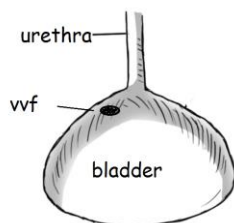
Even the most expert vaginal surgeon will have to admit that this is occasionally necessary. Usually one starts vaginally and then switches to the abdominal approach. Here are some of the situations that it may be necessary:

- 1) A high vesico-uterine or vault fistula can be a challenge especially if it goes up the posterior/ proximal bladder wall and is fixed into scar. With iatrogenic fistulas, the anatomy can be very distorted. If you are unable to finish the mobilization from below, the repair can be completed from above.
- 2) If during repair of a high fistula, you find that one of the ureters needs to re-implanted abdominally, it may be easier to complete the repair of the bladder abdominally as well.

! Tip! In both of these situations, it is usually a good idea to close the vagina before proceeding to the abdomen for two reasons: (1) to stop bleeding (2) to avoid having to re-position the patient at the end of the procedure.

! Tip! Try to leave a probe or metal catheter through the fistula before abandoning the vaginal approach but this is not always possible.

- 3) If repairing a circumferential VVF, the anterior edge of the bladder is not accessible because it is pulled into the abdomen. At laparotomy, it is easy to mobilize the anterior edge from the anterior abdominal wall. The bladder defect is closed with the lower end of the bladder formed into a tube which is then pulled through into the vagina to anastomose with the urethra. Two strong stay sutures are attached to the lower bladder to help with the pull through.
- 4) If you fail to access a very high and lateral VVF vaginally, which is usually associated with a previous failed vaginal repair. (Note: the suprimeatal approach (See section 3.8) is an alternative and easier way to manage these fistulas.) When you open abdominally, you will usually find the fistula at the urethro-vesical junction laterally (Fig. 5.6). If it is difficult to find the fistula, do a dye test.



- *If the bladder has not been opened:* inject dye up the Foley catheter to find the fistula.
- *If the bladder is already open:* do a dye test by injecting dye directly into the opening with a 10 ml syringe. Hold the bladder edges with Allis forceps and use suction to prevent any dye spilling out. Look from the outside of the bladder to see any leakage. The fistula usually appears as a slit-like opening.
- Close the fistula from above i.e. from the outside of bladder/ urethra i.e. extra-vesical approach.

Fig. 5.6: When viewed supra-pubically, the fistula will be found low down near the bladder neck.

After the fistula, (the bladder opening if any) and the abdominal wall are closed, close the vaginal aspect of the fistula from below. As it may have been difficult to get a good closure of the fistula, an additional step would be to sew the bladder to the pelvic side-wall over the leak and then maybe even add a muscle patch over it (see Chapter 1 step 3: If the dye test remains positive).

PROBLEMS WITH THE CERVIX DURING ABDOMINAL REPAIR

If the patient presented with menses coming through the bladder/ urine with or without urinary incontinence, once the layers are dissected out, see if you can close some remaining cervix over a small tube coming out of the vagina to ensure the patency of the cervical os. Use one of the following:

- A plain tube (12F) which is transfixed by a suture and then fixed to the vagina or perineum.
- A Foley catheter inflated in the uterine cavity via the cervical canal and vagina. This can also be transfixed with a suture instead of inflating the balloon.

The tube is retained until it falls out or the patient menstruates as the os may stenose again. If it is not treated in this way, the accumulated menstrual blood may force its way through the site of the bladder repair with resultant recurrence of the fistula.

CHAPTER 6

URINARY INCONTINENCE POST-FISTULA REPAIR

Section 6.1: Causes and evaluation of post-repair incontinence
Section 6.2: Conservative treatment of post-repair incontinence
Section 6.3: Surgery for stress incontinence: general
Section 6.4: Surgery for stress incontinence: repairing defects in the fascia
Section 6.5: Surgery for stress incontinence: sling operations and other options
Section 6.6: Urethral stricture

(6.1) CAUSES AND EVALUATION OF POST-REPAIR INCONTINENCE

At least a quarter of women whose fistulas have been closed successfully remain incontinent and these patients are classified as having post-repair incontinence. It seems the longer the follow up, the higher the incidence becomes. Causes include stress incontinence, detrusor over-activity and voiding dysfunction. The patient can leak as much trans-urethrally after surgery as she did through the original fistula. *Reference: Urinary incontinence following obstetric fistula repair: World J Obstet Gynecol 2016 May 10; 5(2): 182-186. Goh J.*

- (a) The most important factor in post-repair incontinence is the extent of any urethral damage. There is loss of the bladder neck/ posterior urethra and the overlying pubo-cervical fascia. This results in loss of coaptation of the anterior/ posterior urethra rather than urethral hyper-mobility.
- The posterior urethra may lack the normal support of the pubo-cervical fascia and the vaginal wall.
 - The anterior urethra is often fixed to the back of the pubic symphysis, especially with circumferential defects. This interferes with the normal mobility of the urethra which is important in continence.
- (b) Reduced bladder capacity due to bladder damage with a large fistula is a less common cause.

SUMMARY OF POST-REPAIR URINARY INCONTINENCE		
TYPE	DIAGNOSIS	TREATMENT
Stress	<p><i>Hx:</i> The patient is usually dry in bed and wet on standing or with activity or with cough.</p> <p><i>Ex:</i> Look for leakage of urine via the urethra on coughing. To ensure that it is pure stress, exclude:</p> <ul style="list-style-type: none"> • A small fistula close to the urethra: even if urine is passed through the urethra. • Bladder stone or small bladder capacity. • Overflow: measure residual volume. 	<p><i>Conservative:</i> wait 4-6 months. Pelvic floor exercises may help but are unlikely to cure incontinence.</p> <p style="text-align: center;">(Urethral plugs if available.)</p> <p><i>Surgery:</i> Either or both: (a) Repair of the endopelvic fascia (b) Fascial sling.</p>
Urgency	<p><i>Hx:</i> Ask about frequency and urgency. If nocturia exceeds two times per night, this suggests urgency. If she is not getting up at night, this indicates a good bladder capacity and no urgency.</p> <p><i>Ex:</i> Check for a small bladder capacity/ cystometry. With a metal catheter, check for bladder stones which are not uncommon after a fistula repair especially if the patient still has some incontinence.</p> <p><i>Investigation:</i> Exclude a urinary tract infection. Ask her to keep a voiding diary to see bladder capacity.</p>	<ul style="list-style-type: none"> • Pelvic floor exercises. • Anti-cholinergic e.g. Oxybutynin 5 to 15 mg/ day. • Bladder drill: drink plenty and timed voiding. • Bladder augmentation to increase capacity. • Bladder Botox and neuromodulation.
Overflow: stricture or bladder atony	<p><i>Hx:</i> Usually the patient is wet in the bed as well as with standing. She may have difficulty passing urine.</p> <p><i>Ex:</i> The urine comes through the urethra especially when she coughs and so it may be misdiagnosed as “stress”. Measure the residual urine after voiding.</p>	<ul style="list-style-type: none"> • Intermittent self-catheterisation. • Timed voiding and double voiding. • If stricture: dilation or urethroplasty.
Fistula	<ul style="list-style-type: none"> • <i>Bladder:</i> Do dye test to exclude bladder fistula. • <i>Ureteric:</i> Do ultrasound of kidneys if you suspect a ureteric fistula to look for hydronephrosis. 	<ul style="list-style-type: none"> • <i>Conservative:</i> Catheter treatment if VVF discovered early enough. • <i>Surgery.</i>
Mixed	Stress and urgency is the most common combination.	May treat the stress first as this restores normal bladder filling and emptying.

In one study, 50% of those who leaked on walking after repair were dry at six months. *Reference: Women with obstetric fistula in Ethiopia: a 6-month follow-up after surgical treatment: Browning A, Menber B. BJOG. 2008*

Nov; 115(12):1564. However, the opposite often happens. The patient may go home “dry” only to return later with severe stress incontinence.

Incontinence persisting after repair can be predicted by:

(1) *Urethral involvement*: this is the strongest determining risk factor with the risk of persistent incontinence being 8.4 times greater.

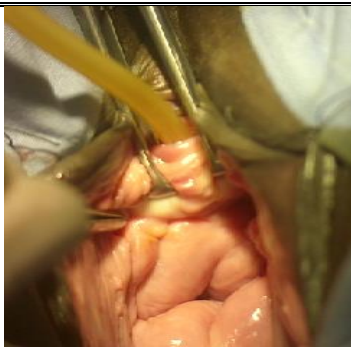

- The urethra is involved in up to two-thirds of fistulas.
- The shorter the distance from the external urethral opening to the fistula, the more likely stress incontinence is to occur post-operatively. The critical urethral length for continence is approximately 1.5 to 2 cm. Those with Goh or Waaldijk Type 1 fistula are most likely to be continent whereas those with Goh Type 4 or Waaldijk Type 2Bb are least likely to be continent.
- The normal female urethra is about 4 cm long. The average length of the urethra in patients with stress incontinence post-repair is 1.4 cm.

(2) *Size of the original defect*: The risk for persistent incontinence increases by 1.34 times for each 1 cm increase in the diameter of the defect.

(3) *Significant vaginal scarring*: i.e. scarring that is severe enough to prevent the use of a Sims speculum without incising it. The risk for persistent incontinence is 2.4 times greater.

(4) *Small bladder capacity*: The risk for persistent incontinence is 4.2 times greater. A small bladder capacity in this study means the bladder is unable to contain 100 ml of fluid at the end of surgery.

Reference: Browning A. Risk factors for developing residual urinary incontinence after obstetric fistula repair. BJOG 2006; 113:482-485. In this study circumferential involvement, a very important risk factor for developing stress incontinence, was not analyzed separately.

	<p><i>Fig. 6.1a: When doing a dye test in cases of post-repair incontinence, to prevent the dye leaking out through the urethra, an Allis forceps is placed on either side of the urethra as shown. Then as you inject the dye, distal traction on the Allis forceps is applied to prevent leakage through the urethra. If the patient is not anaesthetized, you can compress the urethra with a swab.</i></p>	<p>For any patient with post-repair incontinence:</p> <div style="text-align: right;">  </div> <ul style="list-style-type: none"> ➤ Do a dye test as this often reveals a small fistula. ➤ Exclude any bladder stones. ➤ Check bladder size, capacity and pressures.
--	--	--

EVALUATING A PATIENT WITH POST-REPAIR INCONTINENCE

The key to managing these patients is to make an accurate diagnosis. So take a good history, examine them carefully with a good light, speculum and do a dye test. It helps if the patient has a full bladder so have her drink plenty of fluids prior to examination.

(1) **Estimate urethral function:**

- Although it is difficult to be sure if the urethra is intact, a length of 3 cm or more should be adequate provided scarring is minimal. (See Fig. 1.6 a + b on how to measure urethral length.)
- A urethral plug (Appendix 8) may also be tried because if the patient is dry with this, the problem is clearly urethral rather than bladder related. However, if she is wet with the plug, this does not exclude a urethral cause. Also, even if you think there is a small bladder, the capacity may increase with the use of a plug.

(2) **Estimate total bladder size:** The length from the external urethral opening (EUO) to the dome of the bladder (DOB) is measured with a sound.

Normal: should be ≥ 8 cm and if it is, it suggests the problem is stress incontinence rather than a bladder problem and usually requires alternative treatment e.g. stress operation or plug.

Abnormal: a length of ≤ 6 cm, suggests a small bladder capacity. These patients are nearly always wet secondary to small capacity.

Borderline: 7 cm is a borderline measurement and other causes should be excluded.

Note: You can measure the true bladder length by measurement of total bladder length minus the urethral length. A true bladder length of < 6 cm is small.

(3) **Estimate bladder capacity \pm pressures:**

- Insert a Foley catheter into the bladder after voiding and measure the residual volume to exclude urinary retention as a cause of overflow incontinence.
- *Gravity dye test:* Attach a bladder syringe without the plunger to the Foley catheter held about 20 cm above the external urethral orifice and pour the fluid into this. You can pinch the Foley catheter as you

fill the syringe so that you know how much you have poured in. The bladder is filled by gravity with 50 ml, then 100 ml of water or saline. (If there is leakage before 100 ml, press on the urethra to occlude it or pull on the Foley catheter so that the balloon occludes the urethra.) Filling may be stopped at 150 ml (normal bladder capacity is 350 to 400 ml). If 100-150 ml flows into the bladder, this suggests that the bladder capacity is okay. If there is no marked urge to urinate by the time 150 ml is inserted, then the catheter is removed and the patient is assessed for stress incontinence.

- *Bladder diary*: Ask the patient to measure and record the volume of urine she voids for a period of 3 days. Analyse the average volume she passes (functional capacity) and night frequency (nocturia).

!Tip! When doing the dye test, it is easy to miss a pinhole fistula of the urethra as the Foley catheter may be against the fistula. It helps to move the catheter once the dye is injected to allow dye to leak out through any fistula.

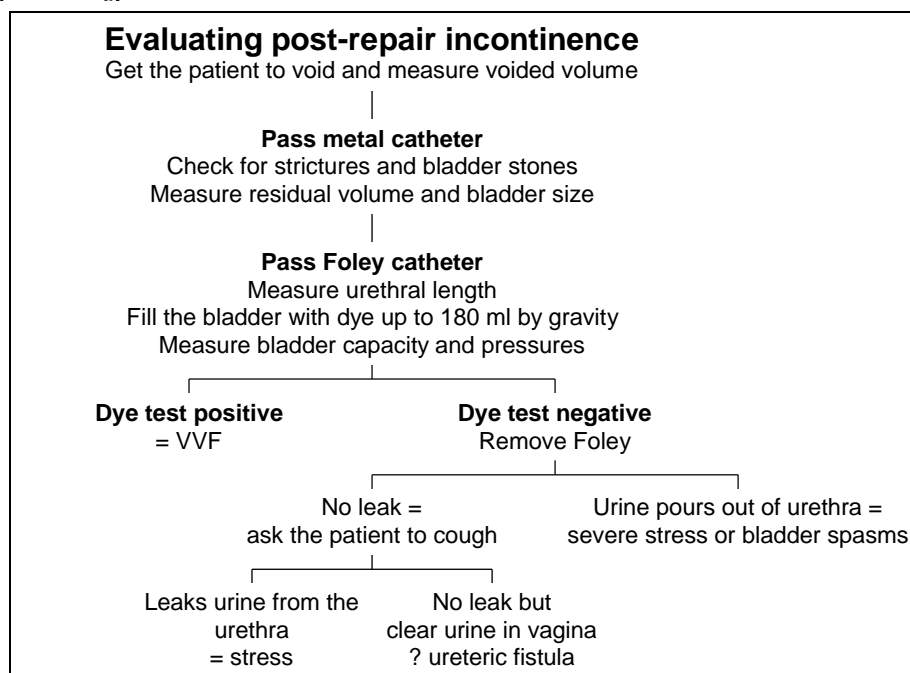
- *Bladder pressures*: This can be estimated by observing the fluid level in the syringe or the Foley catheter as in Fig. 1.24 g + h. If this is less than 20 cm i.e. above the meatus with the bladder holding at least 100 ml of water, then significant urge incontinence is excluded and stress incontinence is suspected.
 - Changes in the intra-vesical pressure are apparent as fluctuations in the fluid level i.e. the meniscus in the syringe.
 - Ask the patient if she feels her bladder is full at any time. Any sudden rise in pressure accompanied by an urge to void indicates an involuntary bladder contraction and detrusor instability, although increases in abdominal pressure can masquerade as bladder spasms.

!Tip! During cystometry, you have to remember that any pressure changes seen are changes in bladder pressure, not necessarily bladder contractions. Any increase in intra-abdominal pressure (movement, cough, strain, even talking) will lead to fluctuations in intra-abdominal/ bladder pressure. The combination of symptoms with pressure change is much more clinically valid than pressure change alone.

(4) Evaluate vaginal elasticity and mobility:

- Patients often leak when pressure is exerted with a speculum on the posterior vaginal wall. This is thought to be due to stretching of the vagina removing any remaining elasticity which is already deficient. Such patients may require a skin flap (see page 90 and chapter 8) to restore the normal elasticity. This has been found to reduce the risk of stress incontinence.
- If there is little mobility of the anterior vagina, then a sling is less likely to work.

Reference: Browning A, Williams G, Petros P, Prevention and cure of post vesico-vaginal fistula repair incontinence by insertion of skin graft in the bladder neck area of vagina- update on hypothesis and interim report; Pelviperineology 2017; 36: 9-11.



Case History: The following is included to show how difficult it can be to make a diagnosis of what is causing “post-repair incontinence”. A 30-year-old patient had four previous repairs and now has “post-repair

incontinence". She was wet more during the day than during the night. During the last repair, the bladder capacity was recorded as 40 ml.

- *In the outpatient clinic:* It was uncertain if the problem was due to a small bladder or an incompetent urethra. When bedside cystometry was performed, the bladder pressures appeared high. The dye test was negative but dye poured out through the urethra.
- *In the operating room:* A gravity dye test (see chapter 1C) allowed 120 ml to flow into the bladder. The true bladder wall length was 8-9 cm minus urethral length of 1 cm. On this basis, it was felt that the small bladder capacity was not the main cause of the incontinence so a stress procedure with plication of the fascia under urethra was undertaken. After this procedure, a dye test (100 ml injected rapidly) was performed which showed a small leak at the site of the previous repair. This was repaired and a layer of pubococcygeal muscle was placed over the repair.

Lesson: Repeated examination is necessary to make a diagnosis. The gravity dye test is useful for measuring the bladder capacity.

PERSISTENT FISTULA AFTER REPAIR

- (a) *VVF:* A catheter can be re-inserted if the defect is discovered within 3 weeks of the initial operation. If conservative management fails, the next attempt at repair should preferably be after 2 to 3 months so that the tissues are less friable.
- (b) *Ureteric:* There is urine in the vagina but the dye test is negative.
- It is possible for a VVF to heal (dye test negative) but for a ureter which was in the edge of the fistula to retract outwards and present as a ureteric fistula (see Fig 9.8).
 - More commonly a ureteric fistula may have been present before the VVF repair, but only becomes obvious when there is continued urine leakage after the VVF is closed successfully and the dye test is negative. The VVF usually occurs from the obstructed labour and the ureteric fistula is iatrogenic i.e. usually Caesarean section performed to treat the obstructed labour.

STUDIES PERFORMED IN POST-REPAIR INCONTINENCE

In one study where urodynamic studies were done in 149 patients who had an obstetric fistula repaired but had ongoing urinary symptoms (not just incontinence), the following were demonstrated:

Stress only: 49%	No stress or no detrusor over-activity: 5%
Stress and detrusor over-activity: 43%	In addition, 7% had post-void residual volumes of 150 ml or more.
Detrusor over-activity only: 3%	

Therefore over 90 % of women had urodynamic stress incontinence and 46 % had detrusor over activity.

Reference: Urinary symptoms and urodynamics following obstetric genitourinary fistula repair: Goh JTW, Krause H, Tessema AB, Abraha G. International Urogynecology Journal and Pelvic Floor Dysfunction Volume 24, Issue 6, June 2013, Pages 947-951.

In another study of 22 patients with post-repair incontinence urodynamic studies showed:

Stress incontinence with normal bladder compliance 41%	Stress incontinence with detrusor instability 41%
Stress incontinence with low bladder compliance 14%	Overflow incontinence 4%

Reference: Stress urinary incontinence after delayed primary closure of genitourinary fistula: A technique for surgical management. Carey MP et al. Am J Obstet Gynecol 2002 May; 186 (5): 948-53.

Therefore while stress incontinence is the major factor in post-repair incontinence, urgency is often present as well. It may be worth treating for urgency for a minimum of one month if medications are available and symptoms are persistent.

(6.2) CONSERVATIVE TREATMENT OF POST-REPAIR INCONTINENCE

Getting the patient to drink plenty helps to increase bladder capacity and should be part of conservative treatment. Also, encourage her to urinate frequently during the day.

(1) STRESS INCONTINENCE

No surgical treatment should be considered for 3-6 months after fistula repair because:

- Many cases improve with time especially if the fistula was non-circumferential.
- There is a risk that you may re-open the fistula if you operate, or create a new fistula in a difficult site.

However, surgery may be performed earlier in some cases if it is not convenient to wait six months provided that tension slings are not applied.

(2) URGENCY URINARY INCONTINENCE

While there is a lot of evidence for treating urgency incontinence in general, no one has ever done a study in fistula patients. Frequency is a big problem in fistula patients and it does not seem to improve with time.

- (a) Drugs: Anti-cholinergics e.g. Oxybutynin 5 mg 3 times daily can be used

- (b) for a month. Then reduce to 5 mg at night-time for 3 months. Tolterodine 2 mg twice daily or mirabegron 25-50mg/day are other options. Amitriptyline 50-75 mg at night-time is another more widely available but less satisfactory option. Be sure the post-void residual is normal before starting anti-cholinergics and do not use in the elderly or those with constipation.
- (c) Pelvic floor exercises: may be more useful in urgency than stress incontinence.
- (d) Timed voiding (bladder training).
- (e) Encourage the patient to drink plenty which may improve bladder capacity.
- (f) Surgery: Augmentation of the bladder if very reduced capacity (see section 10.2).
- (g) Bladder Botox and neuromodulation are other possible options.

There are two main types of abnormal bladder function:

- (a) *The over-active bladder*: In this case, the bladder undergoes increases of pressure as the bladder contracts during filling but then the pressure returns to normal in between contractions. The patient feels urgency symptoms. These patients often leak around their catheters in the early post-operative days.
- (b) *The non-compliant bladder*: i.e. the bladder cannot stretch. This is usually due to loss of elasticity or size. There may be a thickened bladder wall.
 - It is more common with neurogenic bladder, those with long-term obstruction and post-radiation. It is likely that many obstetric fistula patients with small bladders would be non-compliant.
 - During bladder filling, the pressure gradually increases all the time and does not fall. As bladder pressure will always affect the kidneys, if the pressure increases without any leaking via the urethra, then hydronephrosis occurs. The kidneys only tolerate pressures up to 20 cm H₂O.
 - These patients are more likely to have impaired sensation and just leak small amounts all the time, often increased with activity.
 - Patients with a non-compliant bladder are more likely to develop high pressures if you place an obstructive sling.

(3) MIXED STRESS AND URGENCY INCONTINENCE

- The traditional teaching in non-fistula patients has been to treat the urgency incontinence first and then the stress. This is because too many voiding disorders occur if you do a stress operation on patients with urgency incontinence. The patient can be treated with anti-cholinergics first and encouraged to drink plenty. Then if the urgency symptoms improve, an operation for stress can be considered.
- However, the experience in fistula patients has been that the outcome after a stress operation for patients with mixed incontinence is the same as for those with pure stress.
- The disadvantage of surgery is that you may increase the bladder pressure by creating an obstruction to the bladder neck with a sling procedure. However, in most cases, if a sling is placed in a patient with a smallish bladder it will result in frequency and not high pressures. After a sling is placed, it is unlikely that the bladder pressures will have increased if the patient:
 - Is not in retention and the residuals are < 100 mls.
 - Has a normal flow i.e. the patient does not have a weak flow or has to lean forward to micturate.
 - Shows no evidence of hydronephrosis or change in creatinine levels after 6 months.

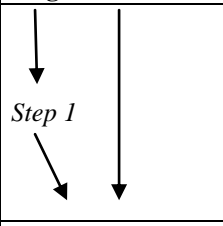

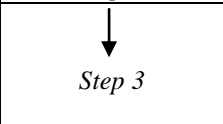

If there is evidence of increased pressure or if the patient has to pass urine frequently (e.g. every 30 minutes) then it would be a good idea to do an augmentation of the bladder.

(6.3) SURGERY FOR STRESS INCONTINENCE: GENERAL

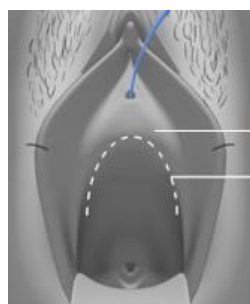
- If stress incontinence persists, consider surgery. There is little evidence to support the different treatments used for post-repair incontinence as long-term follow up of these patients is difficult. Therefore, most of what we do is based on experience. The problem with any surgery for stress incontinence is that initial results are often good but with time the incontinence often recurs.
- The factors that affect the function of the urethra as a sphincter are:
 - (a) *Length*: usually a urethra of 1.5 cm is needed for continence although some patients may be continent with a length of 1 cm. The continence mechanism is along the entire length of the urethra.
 - (b) *Width*: the narrower the urethra, the greater the resistance it can produce. In cases of stress incontinence, the urethra becomes wider with funnelling of the proximal urethra.
 - (c) *Support*: The aim of most operations is to support the posterior urethra and bring it closer to the anterior urethra and the pubic bone.
- The normal function of the urethral support system requires the contraction of the levator ani muscle, which supports the urethra through the endopelvic fascia. With an increase in intra-abdominal pressure, there is a reflex increase in the tone of the smooth muscle of the pubo-cervical fascia, which pushes the posterior urethral wall upwards and forwards towards the anterior wall. There is also an increase in the tone of the internal and external sphincters. All these increased forces occur just milliseconds before there is any increase in the intra-vesical pressure.

Reference: Waaldijk K. In "Obstetric trauma surgery art and science: functional pelvis anatomy in the female".

- Repair of fascial defects with re-fixation to the pubic bone will lengthen and narrow the urethra, and improve its support.

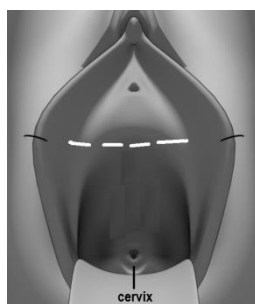
Initial transverse vaginal incision:	SUMMARY OF THE STEPS COMMONLY USED IN SURGICAL MANAGEMENT OF STRESS INCONTINENCE:
	<p>Step 1: To narrow, lengthen and support the urethra, plicate the pubo-cervical fascia (pelvic diaphragm) under the urethra. This layer is then re-attached to the periosteum of the pubic bone on either side of the urethra. It is important to look for defects within the pelvic diaphragm and/or its attachment to the pubis bones and then repair them meticulously. Do not look just for fascia but also for smooth muscle since that is the main component of this layer. In some cases, there is not sufficient fascia to work with or it is completely fixed and immobile so you will have to skip to Step 2.</p>
	<p>Step 2: Add a fascial sling using the fascia of one of the following: the rectus sheath, fascia lata or the fascia of a Singapore flap which is a combination of steps 2+3.</p>
	<p>Step 3: If when you make the vaginal incision, the urethral opening springs forward or the cervix goes back or if there is any tension when you are closing the vagina, this would indicate a stiff anterior vagina with loss of normal elasticity. In these cases, consider a skin flap to avoid any tension in vaginal closure so there is no pull on the urethral opening.</p>
	<p>Intra-operative assessment of the effectiveness of the procedures is not very reliable. However:</p> <ul style="list-style-type: none"> • If the patient appears to be wet at the end of the procedure, it is likely that she will be wet later. • If she appears to be dry when you get her to cough or press supra-pubically, there is a good chance that she will be dry post-operatively.

Incision: Two common incisions are used which are quite similar. My preference is for the transverse incision as I find this gives better exposure of the distal tissues although a mix of the two incisions is also good.



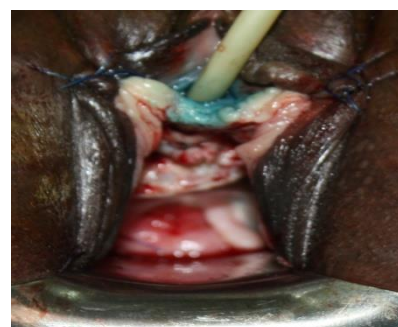
apex of incision
incision

Fig.6.1b: Shows the inverted U incision. The apex of the incision should be approximately 2 cm proximal to the urethral meatus.



cervix

Fig 6.1c: Shows the transverse incision and Fig. 6.1d shows the same incision with the flaps now mobilized and the distal flap sutured back for exposure. Note that a dye test has been done before making the incision to exclude any small fistula.



- (a) **An inverted U incision:** (Fig 6.1b) is used to open the anterior vagina with the apex about 1.5 to 2 cm below the external urethral meatus. The anterior vaginal wall is dissected from the underlying pubo-cervical fascia and bladder to form a flap of vaginal skin. The incision is from ischial spine to ischial spine.
- Before you make the incision, place one Allis forceps just below or on the edge of the urethral opening and a second one, 1-3 cm lower.
 - Once the incision is made, move the two Allis forceps onto the edge of the incision i.e. to either side of the incision at the apex.
 - When dissecting the vagina off the bladder, stay close to the vagina. This avoids injuring the bladder and conserves more fascial tissue for plication.
 - To mobilize the distal flap, it is useful to use the curved Thorek scissors.
- (b) **Transverse incision:** is made 2 cm below the external urethral orifice. The incision is made wide enough to expose the urethra fully and to be able to feel the pubic bone laterally. The distal flap is mobilized and stitched back (Fig. 6.1d). Then the proximal flap is dissected. The advantage of this incision is that it gives better exposure distally than the inverted U incision.

(6.4) SURGERY FOR STRESS INCONTINENCE: REPAIRING DEFECTS IN ± REATTACHMENT OF THE ENDOPELVIC (PUBOCERVICAL) FASCIA

There are two ways of tightening the fascia and re-attaching it to the periosteum:

- (a) Most commonly you have to mobilize the fascia on both sides so that you can pull it across the midline under the urethra i.e. the defect in the fascia is in the midline and longitudinal so the fascia is first plicated across the midline. This is similar to an anterior colporrhaphy but more lateral dissection may be performed. See Fig. 6.3b, Fig. 6.4a.
- (b) In some cases, especially when the fistula was small or distal, the defect is more transverse with detachment of the fascia from the pubic bone. The fascia is found between the vagina and the bladder under the proximal vaginal flap. In these cases, the fascia is sutured directly to the periosteum without plication. See Fig. 6.4b and photograph in Fig. 3.1d.

The procedure can be performed at the time of the fistula repair to avoid stress incontinence in high-risk cases, or later as a separate procedure to treat stress incontinence. When performed later, there is an increased risk of urethral and bladder injury. The following are the steps of the procedure when it is done later. First, exclude any small VVF that you may have missed. Repeat a dye test as in Fig. 6.1a.

Dissecting out the fascia

- Pull the urethra/ bladder with the overlying fascia medially as you dissect laterally. Put Allis forceps on the fascia and pull medially as you dissect the fascia from the vaginal skin or bone out laterally.
- Start just below (proximal) and lateral to the urethral orifice. Stay close to the bone as you do this. A good tip is to start as distal and lateral as possible to avoid the bladder and urethra.
- If you open the para-vesical space (Fig. 6.2), this is recognized by seeing fatty tissue and the levator muscles laterally. However, it is better not to deliberately open this space as this will detach the fascia from the bone.

Repairing the defects in the endopelvic fascia: There are three common defects:

- (1) *Midline defect:* In over 90% of post-fistula repair incontinence, there is a median defect in the fascia. This can be checked for by pulling on the anterior vaginal wall before any dissection and see how mobile it is. Normally it is only slightly mobile whereas when there is a defect, it is more mobile. The defect is closed with interrupted sutures. Use 2/0 or 3/0 Vicryl or preferably PDS. Insert the most distal or proximal sutures first – it does not matter which you start with although I find it easier to start distally first. With the proximal suture, also take a bite of the cervix in the midline as the cervix is the focal point for fixation of the pubo-cervical fascia (Fig. 6.3a).

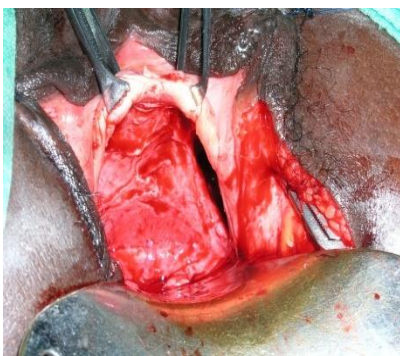


Fig. 6.2: Shows the para-vesical space open on the left. (K. Waaldijk)

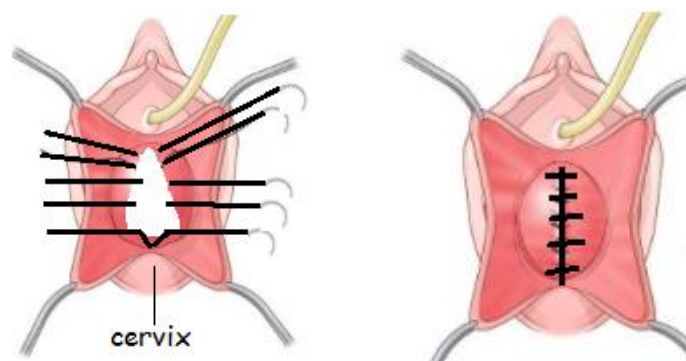


Fig. 6.3a: Shows the median defect in the pubo-cervical fascia being repaired.

- (2) *Distal transverse defect:* This may occur with midline defects or separately when it is seen in distal fistulas or urethral trauma. Therefore in some cases, the fascia does not need to be plicated longitudinally but only re-attached to the periosteum (Fig. 6.4b) i.e. on either side to the posterior aspect of the pubic bone (where the arcus tendineus is situated). It is fixed 2 cm from the midline where the arcus tendineus fascia is supposed to be and then more medially to the pubis bone periosteum.

Where the distal fascia is detached from the bone, the urethral orifice is often open widely (patulous urethra as in Fig. 6.3b) and you can often see into the bladder i.e. may even see the balloon of the Foley catheter. Re-attaching the fascia to the bone closes this defect to give the urethral orifice a normal appearance.

- Use PDS No. 1 suture or Vicryl if that is not available. Nylon sutures are best avoided as they often protrude out the vagina and will lead to stone formation.

- First, make small deep transverse para-urethral incisions on either side over the periosteum to improve the chance of the fascia staying attached.
- Two sutures on either side (para-urethral) are passed from the pubic arch at 10 + 11 and 1 + 2 o'clock positions to the fascia (see Fig. 6.4 a + b). This is performed directly from the pubic bone to the fascia without going through the vaginal wall.

(3) **Lateral defects:** In any circumferential fistula, there are antero-lateral fixation defects with the para-vesical spaces open (See Fig. 6.2) so the fascia needs to be re-attached to the bone with two sutures on either side.

! Tip! The endopelvic fascia has to be connected circumferentially to the pelvic bone for it to function properly. In genuine stress incontinence, there is no need to re-fix the fascia to the bone.

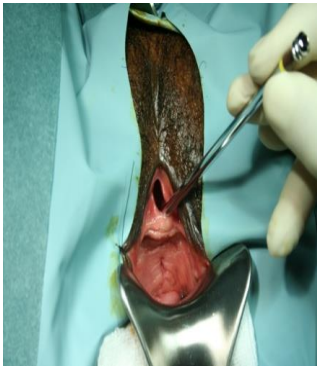


Fig. 6.3b: Shows a patulous urethra.

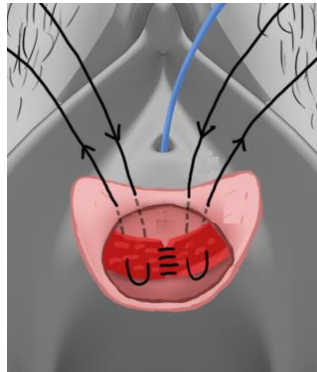


Fig. 6.4a: Shows the sutures going from the bone/ arcus tendineus to the fascia.

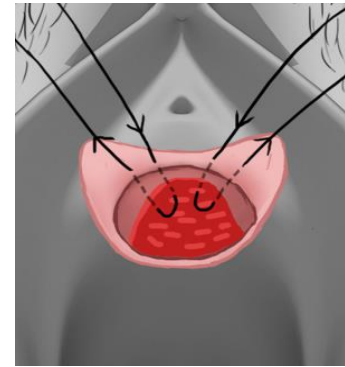



Fig. 6.4b: Shows the fascia being re-fixed to the periosteum without plication.



Flow chart for managing fascial defects in cases of post-repair incontinence.

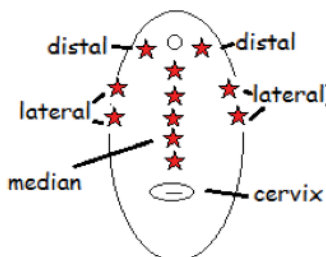


Fig. 6.4c: Summarises the position of the sutures inserted to correct the various fascial defects.

- When taking bites of the pubo-cervical fascia, if you go too deep there is a risk to the ureters.
- With any deep sutures to re-attach the fascia to the bone, avoid being too close to the urethra as this can result in partial necrosis of the urethra.
- Any defect within the endopelvic fascia (diaphragm) and its circumferential fixation has to be repaired.

! Tip! In genuine stress incontinence, there are median defects in the fascia without tissue loss whereas in post-repair incontinence, there are median defects with tissue loss.

(6.5) SURGERY FOR STRESS INCONTINENCE: FASCIAL SLINGS

This uses a free graft of the rectus fascia or the fascia lata of the thigh which is then fixed to the rectus fascia on one side, passed retro-pubically to run under the urethra as a sling and is then passed retro-pubically and fixed to the rectus fascia on the other side (see Fig. 6.6a + b for overview). Another more recent option is to use the fascia of a Singapore flap as a sling (see below).



- The fistula must be healed for at least four months before you can do a sling operation.
- Avoid the temptation to operate before four months just because the patient lives a long distance away and may have difficulty coming back. You will only make her worse.
- The urethra is a fragile structure which may necrose with tension.

Position: The patient is placed in the standard lithotomy position (as for fistula repair) with the buttocks well over the edge of the table. You need access to the vagina and the lower abdomen, so prepare a wide sterile area. Usually, the sling is performed after plication and fixation of the pubo-cervical fascia (section 6.3) although in some cases the sling will be performed without any repair of the pubo-cervical fascia if it is largely absent.

(Step 1) VAGINAL DISSECTION

- Exclude any small VVF with a dye test.
- Pass a Foley catheter and inflate the balloon with 3-5 ml. By pulling on the catheter, feel the position of the balloon which indicates the position of the bladder neck and where your initial incision should be. This is where the sling should sit.
- Make a transverse or inverted U incision and dissect laterally as described in section 6.3. Form a tunnel on each side for the sling to pass. As there is often scarring, dissect with scissors. Initially, aim laterally in the direction of the patient's shoulder on the side you are dissecting (see Fig. 6.4d) until you can get a fingertip into the area. Then with the scissors held vertically and the handle down (parallel to the perineum), aim 2-3 cm from the midline and keep the tips of the scissors close to the pubic bone at all times. Removing the vaginal speculum often helps when doing this step. When you have dissected sufficiently, a finger in the vagina should be able to touch a finger pressing down supra-pubically. This will later enable you to guide the Stamey needle down from the suprapubic region more safely by keeping it close to your finger passed up the vagina.

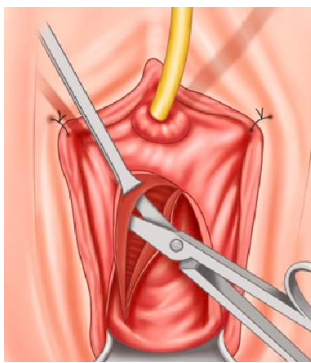


Fig. 6.4d: Shows curved scissors being passed under the pubic bone aiming towards the right shoulder.

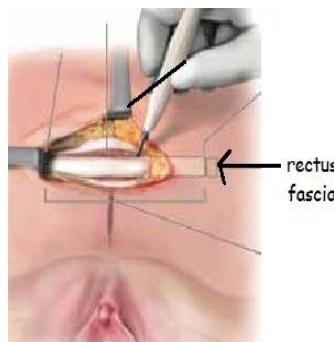
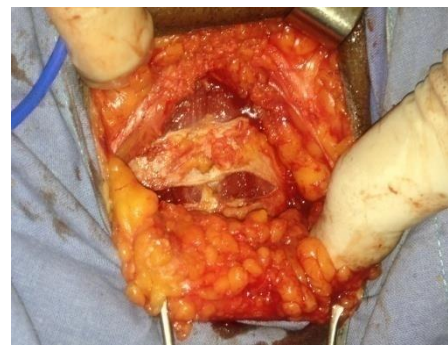

Fig. 6.5a + b: Shows a piece of rectus being cut out for the sling.

**(Step 2) ABDOMINAL DISSECTION**

Make a 5-6 cm in length transverse incision approximately 2-3 cm supra-pubically. Once you reach the rectus sheath, mobilize the fat off the sheath upwards for about 3 cm, then cut a 2 x 5 cm wide strip from the sheath (Fig. 6.5 a+b). Once the strip of sheath is free, pass a Prolene No. 2 suture into each end taking two bites of the sheath (Fig. 6.5c). Do not tie the suture, but leave the ends about 8 cm long on an artery clip.



Fig. 6.5c: Prolene stitch is attached to each end and a marker stitch is placed in the middle.



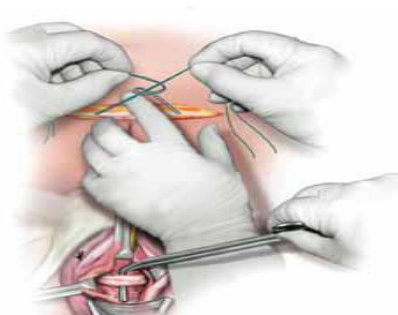
Fig. 6.5d: Shows a Stamey needle used to pass the sling.

! Tip! Place a stay stitch in the centre of the sling (as in Fig. 6.5c) so that you can see later that the sling is centered over the urethra. You can use any suture material to do this.

(Step 3) PASSING THE SLING

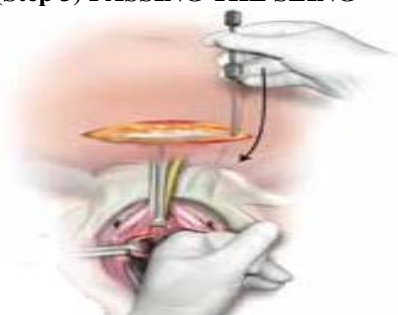

Fig. 6.6a: The Stamey needle is being passed from above the pubic symphysis into the vagina to retrieve the Prolene ends.



*Fig. 6.6b: Shows the ends of the Prolene suture being tied across the midline abdominally. Vaginally it shows a forceps being placed between the sling and the urethra so that the sling is not too tight. However, in post-VVF cases, this is **not** done as it would not give adequate support.*

- Make sure the bladder is empty and leave the catheter in situ. You may perform another dye test before placing the sling if there is any concern from your dissection. Small iatrogenic fistulas after dissection are not rare.
- With the sheath still open, a Stamey needle (Fig. 6.5d) is passed from just above the pubic bone in line with the pubic tubercle. To avoid injury to the bladder, stay close to the back of the symphysis. The rule is to stay close to the bone but do not scrape it. Move slowly and if it gets stuck, you usually need to change the angle. A Stamey needle will cause minimal trauma to the bladder if there is accidental perforation.
- With your left hand in the vagina (Fig. 6.6a), the Stamey needle should come in direct contact with your left index finger. Guide the needle first into the para-urethral space and then into the vagina.
- Now attach the two ends of the Prolene on one side (with the sheath attached) into the Stamey needle. Pull the needle back up.
- The same procedure is repeated on the other side.

! Tip! One way of checking if the Stamey needle has accidentally entered into the bladder if cystoscopy is not available is to use the metal-to-metal test. Pass a metal catheter via the urethra to see if you can feel the Stamey needle in the bladder. Also, the dye test may alert you later, showing leaking suprapubically or vaginally.

! Tip! If a Stamey needle is not available, long artery forceps can be inserted suprapubically to retrieve the Prolene sutures from the vagina. The disadvantage of artery forceps is that if the bladder is entered, the opening will be larger and is less likely to heal spontaneously.

! Tip! If a midline abdominal incision has been made for another reason, to harvest the sling you can cut a strip of fascia on one side longitudinally from the edge of the incision.

Adjusting the tension on the sling: How tightly you tie the sutures determines the tension on the sling. There are two options:

- The sling is inserted free from tension. Have a catheter (16F) in place throughout the operation. However, it is not possible to ensure that there is absolutely no tension on a sling. Even if one could do that in one position (i.e. on the operation table) it would not be possible to say the same applies when the patient gets up. The best you can do is to ensure there is some support, without obstructing. If a sling is inserted at the time of urethral reconstruction or fistula repair, it should definitely be inserted this way.
- The sling is inserted with tension so that you deliberately try to obstruct. In many fistula patients, if you do not pull the sling tight enough, it will not correct incontinence. However, if there is too much tension, it will result in erosion of the tissues or urinary retention.

(Step 4) FIXING THE SLING: use either of two methods:

(A) Fix each side separately:

- Site: Suprapubically to the lower flap of the rectus sheath about 2-3 cm from the midline on each side.

- Fix the two ends of Prolene to the rectus sheath using a free needle. Pass the ends of the Prolene from inside to outside on the rectus sheath approximately 1cm apart.
 - Then fix the other side in the same way.
 - Close the sheath incision before you tie the sling sutures, otherwise the sling tension tends to pull the sheath down, which makes closure more difficult. Ensure that the sutures used to close the rectus sheath are not too close to the sling sutures as they may interfere with tying of the sling sutures. Alternatively, it is safer to close the sheath with interrupted sutures to avoid interference with the sling sutures.
 - On the right side, tie the two ends of the Prolene together and leave the ends long.
 - It is easier to adjust the tension properly as you tie the left side with the right side already fixed.
 - Check vaginally that the centre of the sling (marked with stay stitch *Fig. 6.5c*) is over the urethra.
- Last step:* After the Prolene sutures are fixed on each side to the rectus sheath and the tension adjusted, it is a good idea to tie the ends on one side across the midline to the ends of the other side as an extra security.

(B) Tie both sides together: After passing the sutures through the sheath, instead of fixing the sutures to the rectus sheath, you can tie the two sides across the midline as in *Fig. 6.6b*. Fill the bladder with 100 ml and get the patient to cough. The tension is adjusted so that there is no leakage when the patient coughs. However, if you have already plicated the pubo-cervical fascia, the patient is often already dry by this stage. There is probably a greater risk of obstruction and retention if this method is used.

(Step 5) AFTER FIXING THE SLING: Fill the bladder with 100 ml of dye. This allows you to see:

- If you have injured the bladder you will see dye coming out vaginally or supra-pubically but not through the urethra. If this happens, remove the sling and try again. It is usually only the needle (and the Prolene suture) that has perforated the bladder, so the opening should be small. A Foley catheter should be left in for two weeks if you have perforated the bladder.
- If the bladder can now hold this amount of fluid it indicates the operation is likely to be successful.
- Do a cough test: after doing the dye test, remove the Foley (measure the new urethral length) and get the patient to cough. If she has been sedated, push supra-pubically instead. As mentioned above, the patient can appear dry in the operating room but may still have incontinence later.

Other options:

There are some additional manoeuvres that can be of use if doing a sling after previous VVF repair but these are not routine:

- (a) Open the retropubic space more rather than passing Stamey needle blindly. If bleeding occurs, it can be controlled by upward compression. The surgeon's fingers in the vagina are applied against a sponge forceps pressed down from above. This compresses the veins and then they can be cauterised.
- (b) Do a deliberate cystotomy or cystoscopy to check that you have not injured the bladder.

FASCIA LATA SLING

If it is not possible to get a good strip of fascia from the rectus due to previous surgery or deficient fascia, then this is a good alternative. In fact, because the fascia is stronger here, many surgeons prefer using this fascia rather than the rectus sheath. It also avoids the risk of abdominal wall hernia. However, for post-fistula patients, you cannot be sure if you will proceed with a sling (e.g. bladder opened during dissection) so it is often more convenient to use the rectus fascia.

- Put the patient on her side with a pillow between her thighs, or adjust the lithotomy position so that you can access the lateral thigh.
- Make a 4 cm longitudinal (easier) or transverse (more cosmetic) incision in the lateral thigh approximately 3-5 cm above the lateral femoral condyle. The reason for making the incision low is that there is usually less fat to cut through, the closer the incision is to the knee.
- Using two small Langenbeck retractors placed in the centre of the incision, stretch the incision to expose the fascia.
- With a knife, make two parallel longitudinal incisions of 4 -5 cm length and 2 cm width in the fascia. Then using scissors, cut the upper end of this strip of fascia transversely and mobilize the fascia down to the lower end which is now cut transversely.
- Do not close the defect in the fascia lata, as this creates tension and pain. Muscle will not herniate. Close the thigh skin with absorbable suture.
- You will now have to make a 3-4 cm transverse suprapubic incision in the skin to fix the sling.

SINGAPORE FLAP AS A SLING: (see also chapter 8). It is possible to use the fascia of this flap as a sling especially if the fascia is of good quality. I usually do the fixation of the suture to the rectus on one side only i.e. on the opposite side from where it is harvested although you can do it bilaterally. Using Nylon or Prolene suture (take a figure of 8 bite of the fascia), the fascia is attached to the rectus sheath. In this case, the fascia is still

attached to its blood supply. The long-term effectiveness has not been studied. I would only use it if I was placing a Singapore flap for vaginal closure.

MODIFIED SLINGS FOR POST-FISTULA CASES

These variations are or have been used to improve the success rate of slings or reduce complications. The first option is the only one that I use regularly.

(1) To reduce the risk of erosion: Because the amount of tension applied to the sling has to be greater or the tissues are weaker, there is a significant risk of erosion by the sling into the bladder and/or urethra resulting in the formation of a new fistula. To reduce this risk, one of the following modifications should be added:

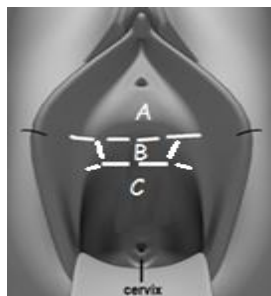


Fig. 6.7a: Shows an area of vaginal skin (B) which is left intact

- Place a Martius flap under the sling in the midline or
- Leave an area of the vaginal skin attached to the urethra/ bladder (Fig. 6.7a). After making the usual transverse incision, make another one 2 cm below it. Then make two incisions laterally so that area B is formed (Fig. 6.7a). The sling is then placed over area B and attached with a few sutures so that it stays apposed to this area. This intact vaginal skin acts as a buffer between the sling and the bladder. The potential problems are:
 - (a) It can be difficult to know exactly where to leave the skin island intact so that the sling will sit on it. Pull on the Foley catheter and feel the balloon, which will indicate the site of the bladder neck. The sling should sit just distal to this site.
 - (b) There is a risk of seroma when the vaginal skin is buried. To avoid this, cauterize the skin of area B (to be buried) with diathermy very superficially to a depth of 1 mm to prevent the formation of any secretions by the skin.

The incision is then closed over to bury the sling. For closure of the vagina, either: (i) undermine the vaginal skin distally (A in Fig. 6.7a) and proximally (C) and oppose it to bury the skin and the sling. (ii) As there is often insufficient skin in these cases, a Singapore flap may be required for closure.

(2) To reduce the risk of complications: Mini-sling

In this operation, instead of fixing the rectus sheath suprapubically, it is stitched directly to the pubic bone on either side of the urethra at 10-11 o'clock and 1-2 o'clock positions with PDS No. 2 suture (on right in Fig. 6.7b). Avoid using non-absorbable suture as it often protrudes out through the vaginal skin and can lead to stone and granulation formation.

- It would be mainly indicated in those cases where there is dense scarring or little mobility of the tissues so that you do not want to do much dissection.
- The main problem with this sling is that the amount of tension that can be generated is limited so it is often not effective. Make sure the sling is in apposition to the urethra rather than tented across the urethra. To achieve some tension, if the sling is too long, the bites are taken (see Fig. 6.7b) on the left side along the sheath rather than at the end of the sheath. After placing the suture, verify that the tension is tight enough with testing via cough or suprapubic pressure. If she is still leaking, you can place an additional stitch to tighten the sling further.
- If there is excess fascia left over, this can either be excised or double backed over the main fascia to provide extra bulk.
- The risk of injury to the bladder or erosion to the urethra should be very low.

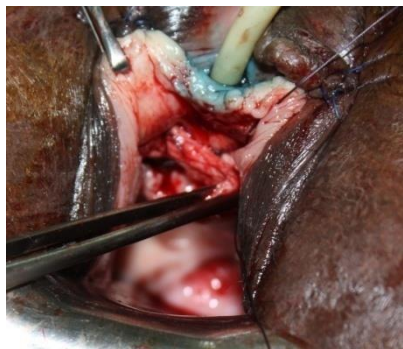

Fig. 6.7b: Shows a mini-sling procedure. The rectus sheath has been stitched on the right side to the pubic arch at 11 o'clock and is about to be fixed at 1 o'clock.

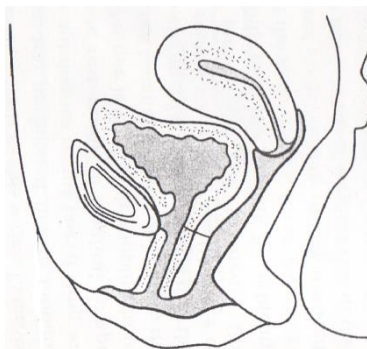


Fig. 6.8: Shows a case where the fistula has been closed but the anterior urethral wall remains continuous with the pubic symphysis.

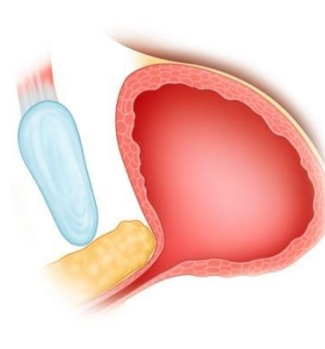


Fig. 6.9: Shows a Martius graft in yellow inserted between the urethra and the pubic symphysis. The procedure is performed via a supra-meatal incision.

(3) To increase the effectiveness of the sling: Mobilizing the urethra

Pubo-vaginal slings normally work by dynamic compression (such movement is usually rotational) and therefore need a mobile urethra. In fistula patients, the anterior urethra is often fixed to the back of the pubic symphysis, especially after a circumferential repair (see Fig. 6.8). Therefore, some have tried to mobilize the urethra first before performing a sling. To mobilize the urethra, either one of the following procedures can be performed:

- Retropubic dissection is performed to mobilize the urethra and an omental graft is placed in the retropubic space to reduce the risk of re-adherence of the urethra to the pubic symphysis. This is then followed by placement of the sling. In such circumferential cases, there is a high risk of making a cysto-urethrotomy although closing the defect, placing omentum or fascia, and leaving a catheter in for 10 days should lead to healing.
- A similar procedure can be attempted vaginally through a supra-meatal incision and using a Martius graft (see Fig. 6.9).

Reference: Stress urinary incontinence after delayed primary closure of genitourinary fistula: A technique for surgical management. Carey MP et al. Am J Obstet Gynecol 2002 May; 186 (5): 948-53. In this study, the sling was applied without tension and continence rates of around 68% were achieved at 14 months follow up. However, technically it is a difficult procedure and cannot be recommended at present.

- (4) Synthetic slings:** These are designed for those with urethral mobility i.e. the urethra descends to hit the mesh sling and then closes. If the urethra is not mobile, you need to bring the sling up to the urethra and provide some degree of compression e.g. fascial slings. It is not a good idea to place mesh in a scarred anterior vaginal wall that is not mobile. Mesh placed under tension may erode into the urethra with subsequent fistula formation. When first used in fistula patients, synthetic slings were quickly abandoned due to these problems. They could only be considered if placed over a layer which protects the urethra e.g. previous Martius flap or Singapore flap. However, even in this situation, it is difficult to make recommendations as the experience is limited.

(6.6) URETHRAL STRICTURE

Urethral strictures due to non-obstetric trauma: see section 4.5. This section should be read in conjunction with the following as many of the points overlap.

Urethral strictures due to obstetric trauma: Stricture of the urethra may occur at the meatus, along the length of a new urethra or at the junction with the bladder. These are seen occasionally after fistula repair especially if: (a) A circumferential VVF was not managed correctly. (b) A neo-urethra was created. (c) A fistula at the bladder neck was closed longitudinally instead of transversely.

Diagnosis: In many cases, the patient presents with continuous leaking but the residual volumes are not usually high. In these cases, there is over-activity of the bladder in response to the stricture. In some cases, there will be a high residual urine volume. Diagnosis is usually made by failure or difficulty to pass a metal catheter into the bladder. *Management:* Strictures are difficult to manage and whatever you do, they commonly recur as they do not epithelialize.

OPTION 1: DILATION: Milder cases may be suitable for this. (See section 2.3 *If the urethra is stenosed* for different ways of dilating.) Once through the stricture, you should then dilate up to 16 to 18 F. There is no need to dilate further. Remember when dilating the urethra, use plenty of lubricant gel and stay close to the bone to avoid perforating through the (posterior) urethral wall. Always do a dye test after dilation to exclude a fistula. There are two problems with dilation: (a) The stricture often recurs quickly. (b) It is easy to make a false passage especially in the more severe strictures. This can be recognised by doing a gravity dye test after dilating i.e. if the dye does not flow in or does not flow back out freely, then it is likely that the catheter is not in the bladder.

CAUTION! If you have used a dilator to open the stricture and you think the dilator has gone in too far, there may be a perforation. In this case, it is best to check supra-pubically or with cystoscopy or cystogram if available. An intra-peritoneal leak towards the dome of the bladder may not heal with just a catheter. In this case, the patient will develop gradual abdominal distension after the catheter is removed. An open repair is best. In contrast, extra-peritoneal leaks heal well with a catheter because they have fat etc around them.

Longer term management: Strictures nearly always recur. Therefore after dilating or surgical treatment:

- *If the patient is dry:* she should do intermittent catheterization at least once a week. Use a short stiff catheter which she holds in place for a few minutes.
- *If the patient is wet:* do a stress procedure but also get the patient to do intermittent catheterization once daily in order to keep the urethral lumen patent. Another option is to use a urethral plug if available.

Some believe that strictures will recur even with dilation and the benefit of dilation is that you will know when they recur, as the patient can no longer catheterize herself.

OPTION 2: SURGICAL TREATMENT

If the stricture is completely solid and there is difficulty inserting a small dilator safely, then it is better to incise through the stricture. Via a transverse incision in the vagina, make a longitudinal incision through the stricture (Fig. 6.10a). Use a metal catheter, guide wire or dilator to locate the site of the stricture. Then cut down just proximal to this for a distance so that the dilator can pass easily. Remember that when trying to pass the dilator past the stricture site, the urethra normally curves posteriorly so make sure you are pushing in the correct direction, otherwise you may make the incision too long.

!Tip! Try to get a small dilator or guide wire through the stricture as this makes it much easier to see the lumen and length of the strictured area.

(A) **Incision and anastomosis:** Excise the stenotic area, mobilize and close transversely (Fig. 6.10a). However, this may not be so easy to do in practice as the female urethra is already short in length. There is still a risk of re-stenosis. Some believe that a buccal mucosa graft is a better option in all cases even if the stricture is only 1 cm in length.

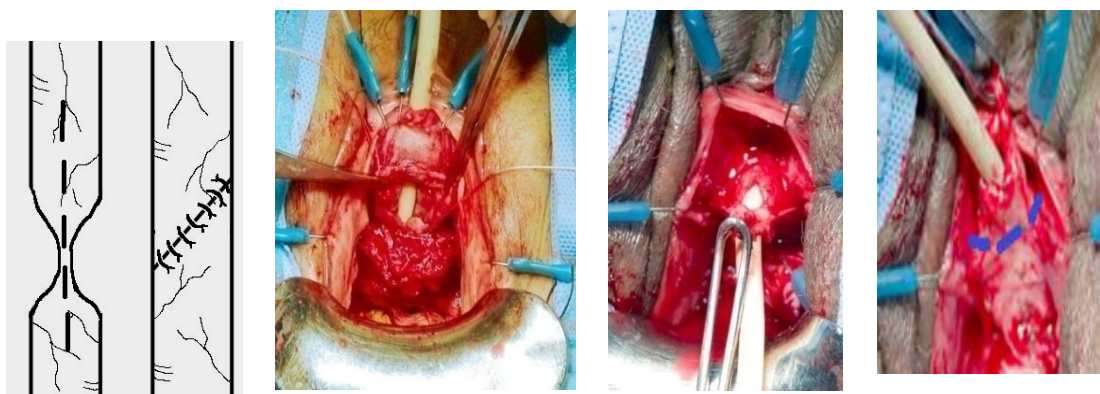


Fig 6.10a: A longitudinal incision is made through the stricture. The closure is done obliquely widening the stricture area. Oblique closure is less likely to re-stricture than transverse closure.

Fig. 6.10b: Shows a longitudinal incision made through the urethral wall for a proximal urethral stricture.

Fig. 6.10c: Shows a distal stricture after a suprameatal incision has been made. The distal anterior urethra is incised through the strictured area.

Fig. 6.10d: Shows the distal posterior urethral wall exposed, and a circular incision (in blue) will be performed to complete the excision of the distal urethra with the stricture (see section 4.5 page 74).

(B) **Buccal mucosa graft:** If the stricture is long and there is loss of tissue, another option is to use a buccal mucosa graft. This procedure may carry a risk of urinary incontinence post-operatively. An incision is made in either the anterior or posterior aspect of the urethra which is incised longitudinally to divide the stricture.

- Anterior (termed dorsal) approach is preferable as there is little risk of causing a fistula. A supra-meatal incision is made (see Fig. 4.12b) to expose the anterior aspect of the urethra. The urethra is freed up to the bladder neck (using the Foley catheter as your guide) and then opened anteriorly.
- Posterior (termed ventral) approach is made through the vagina (Fig. 6.12). This should be a more familiar approach.

Method: A buccal mucosa graft from the mouth is applied to fill the resulting defect. A length 4-6 cm and width 2-3 cm can be taken (see Fig. 6.11). However, you can make a smaller size graft i.e. even 1-1.5 cm length if necessary. The opening in the urethra/ bladder can be enlarged if necessary to fit the graft.

- Three stay sutures are placed through the lip in one corner of the mouth to provide traction. One at the angle of the mouth, one just below the angle and one above it (see Fig. 6.11a). If necessary, an assistant can retract by placing his thumbs inside the mouth. A self-retaining retractor is not essential.
- The endotracheal tube is turned to the left side if you are taking the graft from the right. If the patient is already under spinal anaesthesia then an induction dose of ketamine or another suitable general anaesthetic needs to be given. The increased salivation due to ketamine makes it easier to see Stensen's duct. Place a gauze swab between the lower teeth and the cheek to absorb any blood. Suction is needed too. Infiltrate with diluted adrenaline 1:200,000. Inject plenty all around with a small needle so there is less bleeding.
- First outline (with a superficial cut) the graft area by using a knife (Fig. 6.11) to cut through the mucosa. Go from deep inside the mouth towards the angle of the mouth separately on each side. Go 1 cm below Stensen's duct opening which is close to the last two molar (upper) teeth (Fig. 6.11b).

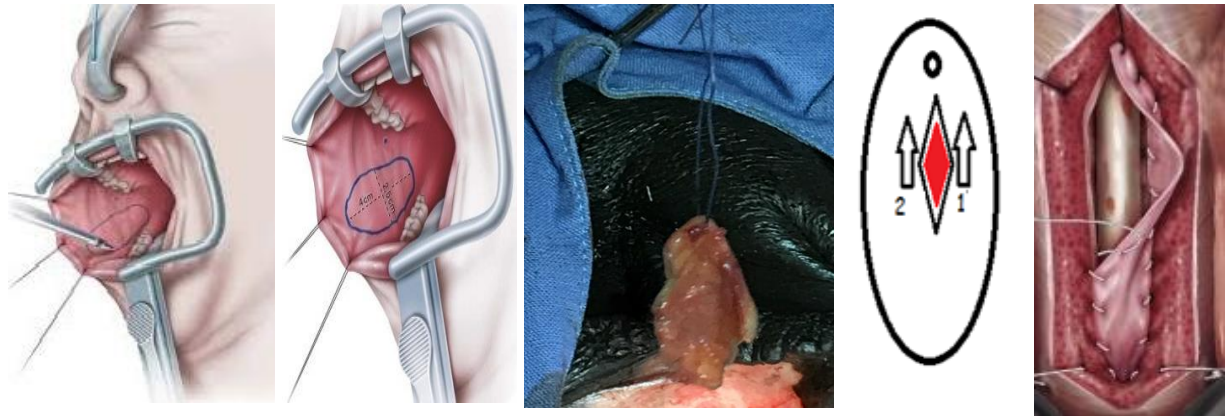


Fig. 6.11a: Shows the graft area being outlined with a scalpel.

Fig. 6.11b: Shows the dimensions of the graft. Note the position of Stensen's duct opening marked by a dot near the upper teeth.

Fig. 6.12: Shows a stay stitch on the apex of the graft (urethral meatus end) to help keep it in place as it is sutured in place.

Fig. 6.13: This is an example of a buccal graft applied on the posterior urethra with the catheter in place. The two arrows show the direction of the sutures.

Tip! To protect the parotid duct, initially make a small incision 1 cm inferior to the duct (which is part of the full incision) before any other cutting. This marks the safe limit very clearly at a time when there is no bleeding.

- To remove the graft work from out to in. Use scissors and dissecting forceps/ pickups to cut out the graft. You can see the underlying muscle as you cut out the mucosa but do not include this in the graft.

Tip! After you have dissected the outer part of the graft, place a stay stitch on it to lift it up as you mobilize it as this makes it easier to see the inner dissection which is more difficult.

- The donor site is closed with a continuous catgut or Vicryl suture.
- The graft is prepared by removing any excess fat and muscle, using scissors to do this. The graft is stretched out either with pins/ needles or wrapped over your index finger. There should be no muscle and only a little fat remaining on it. However, be careful not to cut through the graft as you do this.
- It is then kept in saline until ready to use.

Applying the graft to the urethra: The buccal mucosa graft is sutured to the margins of the opened urethra (see Fig. 6.12) with the mucosal side facing the lumen of the urethra.

- The bites on the graft side have to be close to the edge and the bites of the urethra have to mainly include the mucosa.
- It is best to do this with the Foley catheter in place. If the catheter is in the way while inserting the sutures, either you or your assistant pushes it medially with the tip of artery forceps or use fine dissecting forceps.
- To fix the graft in place (Fig. 6.12), two separate continuous sutures of a 4/0 or 5/0 PDS or Vicryl are started at the apex of the graft (red area) and run distally on each side. The initial bite is from out to in on the graft and then in to out on the urethra so the knot ends up on the outside.
- Before trimming any excess graft tissue as you reach the distal end, allow for 20% more tissue than you think you will need as there will be 20% shrinkage in the graft size with time.
- Get a layer of tissue such as a Singapore or Gracilis flap over the buccal mucosa as it relies on the surrounding tissues for its blood supply. A Gracilis is more reliable than a Singapore for blood supply.

Post-operative: Liquids are allowed anytime after surgery, soft diet Day 1 and regular diet Day 2.

Case History: A patient who had a VVF repair performed one year previously (no notes available) presented with urinary incontinence. On examination she was found to have a full bladder which failed to empty after voiding. There was a tight urethral stricture. At operation, a transverse incision was made in the vagina. A vertical incision was made through the stricture. A buccal mucosa graft was applied and sutured in place with 4/0 Vicryl as in Fig. 6.13. This was covered with the surrounding tissues as a second layer. A Singapore flap was placed over the repair. Her dye test on Day 18 was negative. She voided well after the catheter was removed with only mild stress incontinence.

COMBINATION OF STRICTURE AND STRESS: This is not uncommon and there are no hard rules about how to manage these cases. Either: (a) Dilate the stricture first and then see how much the patient improves before considering surgery for stress incontinence. (b) Treat both at the same session: this would apply especially for the more severe strictures.

CHAPTER 7

RECTO-VAGINAL FISTULAS AND SPHINCTER TEARS

Section 7.1A: RVF: Trans-vaginal repair
Section 7.1B: RVF: Trans-perineal repair
Section 7.2: RVF: Trans-vaginal repair: circumferential defects
Section 7.3: RVF: Trans-abdominal repair
Section 7.4: RVF: Trans-abdominal repair: circumferential defects
Section 7.5: Anal sphincter tear repair
Section 7.6: RVF with anal sphincter tear repair

DIAGNOSIS OF RECTO-VAGINAL FISTULAS (RVF)

In most cases, the diagnosis of an RVF is made on digital rectal and vaginal examination. Occasionally if a patient complains of passing flatus or stool per vagina but no fistula is evident, a dye test is necessary. This is more likely if there is dense scarring with posterior bands (see Fig. 1.4) so that the RVF is hidden in the scar.

- Inject 200 ml of dye through a naso-gastric tube or a Foley catheter passed 10 cm into the rectum. If necessary a swab is used to compress the anus so that the dye does not leak out. Another option is to inflate the Foley balloon to keep the dye in.
- Not uncommonly, the diagnosis is only made when flatus is seen coming as bubbles through the blood/urine in the posterior vagina when operating for a VVF.
- A probe can be passed vaginally into the fistula and palpated rectally. Alternatively, you can pass the probe rectally and palpate vaginally. With large fistulas, the red rectal mucosa is distinguished from the paler pink vaginal skin on speculum examination.

CAUSES OF RVF

There are two main groups:

- RVF combined with VVF:* these are due to prolonged obstructed labour and are usually at least 3 cm above the dentate line. The repair technique is similar to VVFs. The following (section 7.1 to 7.4) refers mainly to this type of RVF which represents a more severe injury process than does an isolated VVF. The accompanying VVF is usually large and more commonly circumferential, and there is more vaginal scarring.
- Isolated RVF:*
 - RVFs due to incomplete healing of a 4th degree perineal tear (see section 7.5).
 - RVF due to sexual or other trauma.
 - RVFs due to obstructed labour only occur on rare occasions without a VVF.
 - RVF related to infections, especially associated with HIV.
 - Iatrogenic: e.g. following posterior colporrhaphy.

Faecal fistulas in children present with the child leaking stool in the vagina. There are two main causes:

- Fistulas associated with HIV originate from anorectal abscesses. Usually these are low and are often ano-vaginal fistulas. It is better to avoid surgery initially and treat with anti-retrovirals as some may heal without surgery. If they fail to heal, surgical management may be necessary.
- Check for an undiagnosed imperforate or ectopic anus with a RVF.

APPROACH TO REPAIR/ STAGED REPAIR OF VVF + RVF

The VVF and RVF can be repaired at the same time or a staged repair can be considered.


- RVF first:* A staged repair usually means doing the RVF repair first. The advantages of staged repair are:
 - It will prevent fecal contamination especially when no colostomy is present. If the RVF repair breaks down, it will not negatively impact the healing of the VVF (such as if they were repaired at the same time). For these reasons the staged repair helps avoid a colostomy (see below).
 - It means you can focus fully on one fistula without thinking about the other one and so do a better repair.
 - Blood loss should be less. When doing a combined repair, blood loss can be considerable.
 - It avoids putting tension on the tissues used for the VVF repair.

A staged repair is especially important for the larger (RVF) cases. If the RVF is small, some surgeons feel happy to do them in the same surgery although a staged repair is still a safer option.

- VVF first or repair both at the same time:*

- In case of a circumferential RVF where a colostomy will be required (see below), you can first do a colostomy, then deal with the VVF and later do a (vaginal or abdominal or a combined) repair of the RVF.

- If there is rupture of the anal sphincter then the VVF may be done first for access reasons. However, it is a good idea to close the rectum at the same time to avoid stool entering the vagina after the surgery.
- If the RVF is only diagnosed while you are doing a VVF repair, then it makes sense to repair both during the same surgery.

	Irrespective of which approach is used, combined VVF and RVF are often difficult operations and are best left for an experienced surgeon.
---	---



TIMING OF REPAIR

Similar principles apply to RVFs as with VVFs. They can be repaired when they are clean. However, very small RVFs (<1cm) often close spontaneously so it is worth waiting 3-4 months post-injury.

WHEN IS A COLOSTOMY ADVISABLE FOR RVF REPAIR?

There are two main reasons why a colostomy may be performed:

- I. To protect from fecal peritonitis, pelvic abscess and sepsis if an anastomotic leak occurs.
- II. To decrease the incidence of anastomotic leakage. The consensus is that colostomies do help in the healing of RVFs. However, most RVFs can be repaired without colostomies. There are times that they should be considered although there are no hard rules for this. Much depends on the experience of the surgeon and the type of RVF. It is more common to regret not doing a colostomy than doing one unnecessarily.

<i>Absolute</i>	The RVF is due to radiotherapy which results in poor healing (see section 3.9).
<i>Most surgeons would do:</i>	For all circumferential rectal repairs irrespective of whether it is performed abdominally or vaginally (see section 7.2 below). This applies especially if the anastomosis is within the peritoneal cavity because if it breaks down it is likely to leak into the peritoneal cavity.
<i>Relative indications:</i>	<p>A colostomy may be required if (it is often a combination of factors rather than one alone):</p> <ul style="list-style-type: none"> • <i>Surgery</i> in the past i.e. previous failed repair especially if multiple failed repairs. • <i>Scarring</i>: Usually difficult cases have a lot of scarring around them with poor mobility. • <i>Size</i>: A large RVF especially it required extensive dissection as these are more likely to leak. • <i>Site</i>: If the fistula is to be repaired abdominally: some surgeons feel happy to repair these without a colostomy if there is good bowel preparation, and it can be closed without tension. • Poor general condition of the patient. • If the RVF is present with a difficult VVF (see <i>Approach to repair</i> above): <ul style="list-style-type: none"> ➢ A bladder fistula often breaks down if covered with stool during recovery. ➢ If the VVF or RVF requires a large skin flap or a Gracilis flap, you do not want to risk a breakdown.
<i>Decision made at surgery</i>	<p>If the bowel has been well prepared pre-operatively, you can leave the decision to do a colostomy until the time of the repair. If you can get a good two-layer closure, then a colostomy is not usually needed. Consider a colostomy if:</p> <ul style="list-style-type: none"> • You find the tissues are not of good quality (e.g. friable or scarred) or there have been technical problems during the surgery and you are worried it may not heal if tested with stool passing through. The main problem with waiting to do the colostomy at the time of surgery is the tendency to avoid doing another procedure at the end of what may have been a long operation. • If there is a leak of air when the anastomosis is tested (see section 7.4).
<i>Decision made later</i>	If the repair leaks, it is often a good idea to do a colostomy for two reasons: (a) It may still help the RVF to heal. (b) It is likely that a colostomy will be needed for any further repairs. However, see below "Post-operative Care after RVF repair".
 Tip!	To avoid a colostomy: (a) Do a staged repair. (b) Ensure good (oral) bowel preparation. (c) Aim for a two-layer closure.
	It is important to consider how easy it will be for the patient to get the colostomy closed later so that the patient is not left with a colostomy for a long time.

MAKING A COLOSTOMY:

If a colostomy is performed before the repair, it is best to do it at least three days before any RVF repair so that the patient has recovered from the surgery.

Sigmoid loop colostomy: In most cases, it can be done through a small incision midway between the umbilicus and the anterior superior iliac spine.

- The sigmoid colon is brought out through this incision and fixed. Make sure you can see the taenia coli. The only disadvantage of doing it this way is that you cannot be certain which is the proximal and which is the distal end.
- The stoma site should be as wide as necessary to deliver the bowel loop extra-abdominally without force (3-4 cm).
- To help prevent prolapse of the colostomy: fix the serosa of the bowel to the fascia with two sutures on each side of the fascial incision.
- After performing the colostomy, it is a good idea to wash out the distal end of the sigmoid and rectum through the colostomy. This can be done using a large Foley catheter or suction tubing. If the saline does not appear through the rectum after several syringes of saline, you may be irrigating the proximal end. Also, irrigate from the anus and vagina so that both the rectum and vagina are clean.


Transverse colostomy: has the advantage of not interfering with the recto-sigmoid thus facilitating the dissection and closure of a high RVF via the abdominal route. The site is approximately midway between the umbilicus and the costal margin so should be 2-4 finger-breadths below the costal margin.


Before closing a colostomy: It frequently happens that colostomies are closed even though the RVF has not healed. After repair of the RVF, complete healing should be shown by a combination of (a) injecting dye down the distal loop of the loop colostomy with a clean swab in the vagina (b) a rectal examination. Do not rely on dye injected through the anus as this can give a false negative test especially with high RVFs. A good option is to do all this under anaesthesia, with the patient prepared for closure of colostomy at the same time provided that the dye test is negative. However, make sure it was a loop-colostomy that was performed and not an end-colostomy before doing the dye test and before any surgery. Also, exclude any stenosis in the rectum by performing a rectal examination and palpating high up.

BOWEL PREPARATION FOR RVF REPAIR

There is no perfect way of ensuring the bowel is clean for surgery. The oral regimes are the best. With enemas, there may be problems passing a tube due to rectal stenosis, or the fistula could allow the tube to enter the vagina. A combination of the following is used:

- Diet:* For 3 days pre-operatively a fluid diet (e.g. soup for 1-3 days followed by clear fluids the next day e.g. tea, juices) is given.
- Oral preparation* works well to ensure more complete emptying of the bowel. If preparations such as Picolax are not available, then oral normal saline can be given by mixing 9 grams of salt in a litre of water. This can be made approximately by adding six level tablespoons of salt in 10.5 litres of water at room temperature. The patient takes this solution the day before surgery until the fluid coming out rectally is clear. Ideally, she should take it all but at least 6 litres should be taken. The fluid intake should be completed by 1400 hours the day prior to surgery and no enemas are required.
- Enemas* should be given daily for 3 days with the last one at least 12 hours before surgery, otherwise the enema will work during the operation. An easily available option is a saline enema: one teaspoon or 5 ml of salt is dissolved in 1 litre of water. Initially, use 100 ml of warm water to dissolve the salt and then add the rest so the water is close to body temperature. The patient holds the enema as long as she can. Another option is a phosphate enema.
- May give an oral laxative such as Bisacodyl for 3-4 days.

 **Tip!** If necessary during surgery, formed stool can be blocked by placing a pack high up the rectum. Attach a string on it for easy recovery at the end of the procedure.

	<ul style="list-style-type: none"> • Make sure the patient does not become dehydrated during the bowel preparation so hydrate well to avoid this. This is especially important when spinal anaesthesia is used during surgery. • It is the surgeon's responsibility to ensure the bowel preparation is performed properly. Therefore check the patient the day before surgery to ensure the preparation is being performed properly. If in the theatre it is obvious that preparation was not adequate, it is better to postpone.
---	---

It is useful to make a distinction between:

- *3- stage RVF repair* i.e. (1) defunctioning colostomy (2) RVF repair (3) closure of the colostomy.
- *2- stage RVF repair:* this is a better option provided that full bowel preparation is given first. (1) RVF repair and protective colostomy performed in the same session (2) closure of the colostomy.
- *1- stage RVF repair* i.e. primary closure of RVF after adequate bowel preparation i.e. no colostomy.

(7.1A) RVF: TRANS-VAGINAL REPAIR

The trans-vaginal approach is preferred for those fistulas proximal to the anal sphincter. This is the case with most obstetric RVFs.

(1) EXPOSURE

Table: With a high fistula, head down tilt may be needed. With a low fistula, a head-up tilt is needed. In between, the table should be horizontal.

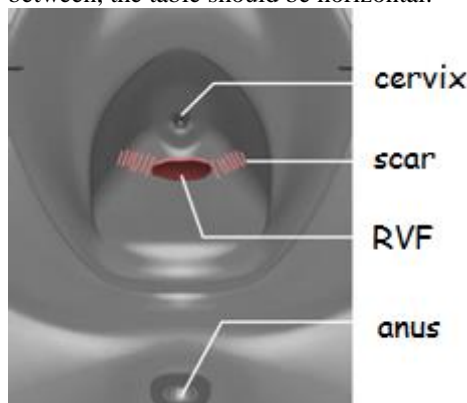


Fig. 7.1a: RVF with surrounding scar.

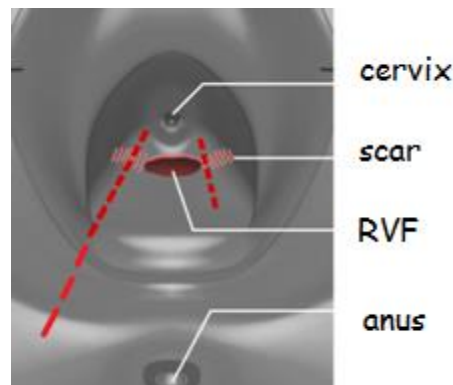


Fig. 7.1b: The line on the patient's right is the episiotomy. The line on the left is the incision for the scar only. Note that both pass along the edge of RVF.

Incisions to improve exposure:

- (a) *Scar incision (confined within vagina):* Very often the RVF is in the centre of a band of scar (Fig. 7.1a) which has to be cut laterally on both sides to allow visualization of the RVF. If no episiotomy has been done and there is a lot of scar tissue in the vagina, cut this laterally at 5 and 7 o' clock which is usually just lateral to the fistula. It is a good idea to use cautery to make these incisions to minimize bleeding. A small retractor on the anterior vagina helps visualization. Beware of creating another rectal injury when taking down these scar bands laterally.
- (b) *Episiotomy (extends onto perineum):* It may be helpful to do an episiotomy extending to the edge of the RVF to improve access. This can come as a distal extension of the incision you made to cut the scar bands. Decide which side is best depending on the position of the RVF. Occasionally you may need to do bilateral episiotomies for an RVF repair.

! Tip! The important point when cutting scar or doing an episiotomy is to aim the incision just along the lateral edge of the RVF as shown in Fig. 7.1b.

! Tip! Occasionally converting an RVF to a 4th degree tear can be useful if access is very difficult due to vaginal scarring. This should really only be done if the sphincter is also torn. If the sphincter is intact, you should repair these fistulas without converting to a 4th degree tear to avoid any further compromise to the sphincter.

! Tip! Some surgeons operate by keeping a left index finger in the rectum for most of the operation to help exposure of the fistula by bringing the anterior rectal wall forward (Fig. 7.1d +e). This is more useful for low fistulas. Your assistant would have to tie the knots for you. There are two cautions with this technique:

- Beware of needle stick injury when doing this.
- Try not to touch the open wound with your contaminated finger.

! Tip! Some surgeons use a Foley catheter to apply traction to the fistula which helps with dissection (see Fig. 7.1f). It is unusual to be able to do this for most obstetric RVFs.

Speculum:

- It may help to hold a Sims speculum or a small retractor against the anterior vaginal wall for visualization (Fig. 7.1c).
- A Sims speculum on the posterior wall is useful for high fistulas. It may be possible to use a weighted speculum.
- The position of the speculum can be varied during the operation to give the best exposure; initially it may be held against the anterior wall and later against the posterior wall. Manipulate it to see which

position gives the best exposure. It may be necessary to use one anteriorly and another one posteriorly (without obscuring the RVF).

- In some cases, it may not be possible to insert any specula; there will only be enough room to apply Allis forceps to the edges of the vagina (Fig. 7.1c + d). Pulling down on these helps expose the fistula.
- A side-wall retractor can also be useful laterally especially when stitching the lateral angles.

Tip! The suction tip is often the best retractor as it is long and takes up little room when you are trying to expose the apex of the RVF.

Tip! For high fistulas, firm tubing (e.g. endotracheal tube) or a large dilator can be placed up the anus or through the fistula into the rectum to help in identifying the lumen during dissection.

Tip! With high fistulas, holding the cervix with a long Allis forceps, and pulling it up is very useful.

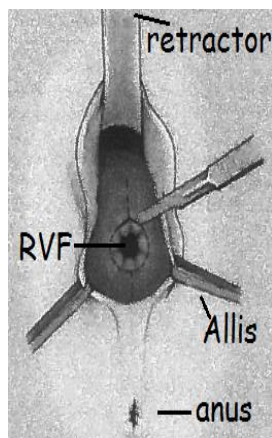


Fig. 7.1c: For a low fistula, place two Allis forceps at 5 and 7 o'clock at the entrance to the vagina.

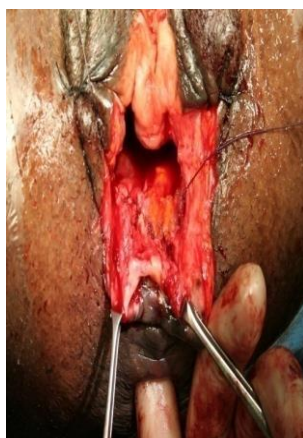

Fig. 7.1d: Shows the use of two Allis forceps, and surgeon keeping a finger in the rectum during repair for exposure.

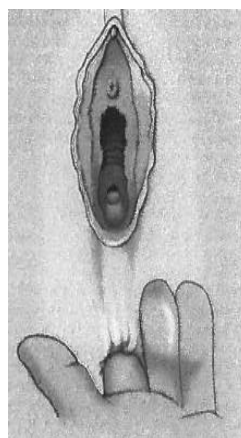


Fig. 7.1e: Shows the left index finger inserted into rectum to expose the fistula.

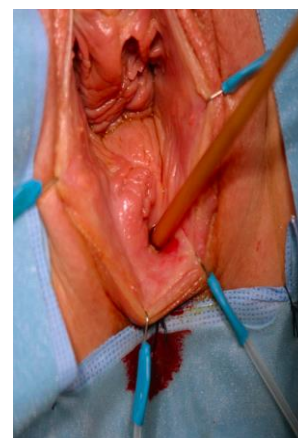

Fig. 7.1f: Shows the use of a Foley catheter to apply gentle traction to the fistula tract which helps in exposure.

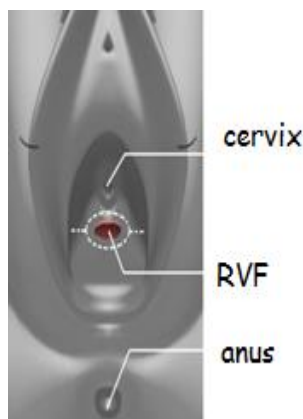


Fig. 7.2 a +b: Shows the incision to make around the fistula. (Courtesy of Grace Chen).

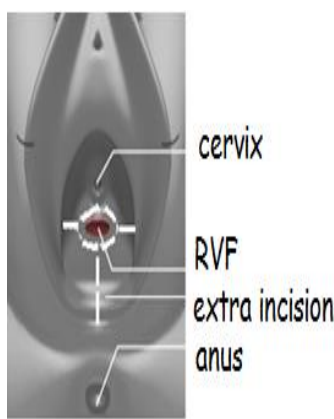
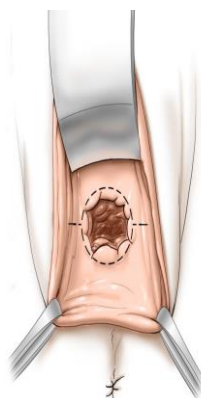


Fig. 7.2c: In a high or mid-vaginal RVF, an extra incision can be made distally to aid distal dissection.

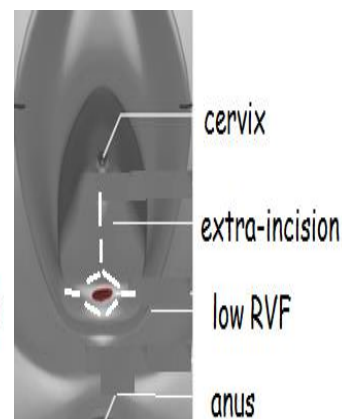


Fig. 7.2d: In a low RVF, an extra incision can be made proximally.

(2) INITIAL INCISION

- Infiltrate diluted adrenaline solution as for VVF repair (see chapter 1).
- The incision is similar to that used for a VVF with a lateral extension on either side (see Fig 7.2a + b). It may also help to make a midline extension as shown in Fig. 7.2 c + d. In this case, two flaps are formed and these can be retracted back with sutures.

Tip! Occasionally the rectal mucosa will prolapse down through the fistula which makes exposure difficult. A useful tip is to put a small swab up the rectum to push the mucosa up.

(3) DISSECTION

- (a) Proximal:** Start dissection proximally (at the top), where there is more mobility. Grasp the edge of the rectum (or vagina in difficult cases) with an Allis. Then with a knife incise the vagina proximal to this (Fig. 7.3). Once the incision is made, grasp the vaginal edge with a second Allis forceps. Dissect the vagina off the rectum, staying close to the vaginal skin as you do so. Use scissors for this.

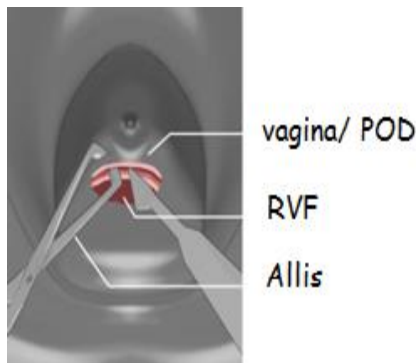


Fig. 7.3: To start the proximal incision hold the rectum or the vagina with an Allis forceps to provide tension as you make the initial incision. POD = Pouch of Douglas

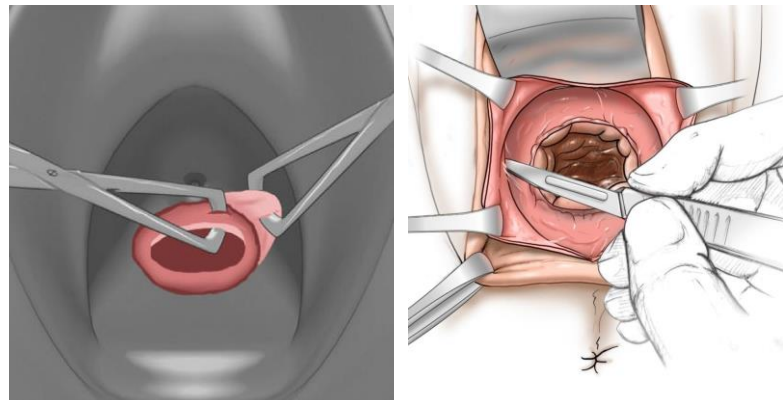


Fig. 7.4: Diagram on left shows the use of Allis forceps to develop tension to help find the tissue plane. The diagram on the right shows the lateral dissection being performed while this tension is maintained.

If the pouch of Douglas opens: As you mobilize the vagina proximally, the pouch of Douglas often opens. This does not matter and it will help with mobilization. In fact, with more proximal fistulas, it is a good idea to deliberately open the pouch. Often there is a small amount of fluid in the pouch, which helps identify it.

- If only a small opening is made, it is worthwhile opening it fully to visualize the proximal rectum better.
- If the small bowel prolapses, obscuring the field of view, put a (vaginal) pack in to keep the bowel out of the way and clip the end of it to the drapes. The pack will be in the peritoneal cavity. Also, increase the head-down tilt of the table if possible.
- You can put a Sims speculum into the pouch to retract anteriorly as this will give a good view.
- If there is faecal spillage from a poorly prepared bowel it might contaminate the peritoneal cavity.

! Tip! If it is difficult to close the peritoneum, leaving it open will not usually cause any problems provided there is no spillage of faeces i.e. the peritoneum opening is incorporated into the vaginal closure.

- (b) Lateral:** Once the proximal dissection is done, dissect laterally on each side while pulling the rectum medially. Grasp the vaginal skin on one side and the rectum on the other side with Allis forceps and cut between them (as shown in Fig. 7.4). Work proximally and distally on the lateral side to separate the vagina and rectum. The angles of the fistula may have to be freed from the pelvic side-wall where there is often a lot of scarring. **CAUTION!** Be careful of bleeding here (see below).

- (c) Distal:** The distal flap is usually more fixed and therefore more difficult to mobilize. There are two tips to help with this:

- Make an extra incision in the midline from the fistula distally (Fig.7.2c) and then separate the vagina off the rectum.
- Put your finger or a dilator in the rectum for exposure.
- Once dissected, the distal vaginal flap(s) can be stitched back to the skin for exposure.

! Tip! In difficult cases, it may help to do dissection at the distal end first for exposure, before doing the proximal and lateral dissections. In this way, you can follow the rectal edge around and proximally.

! Top Tip! When it is difficult to see the outline of the rectal defect, place Allis forceps all around the rectal edges. The sidewall retractor placed laterally can also help in exposure.

! Tip! A large Hegar dilator (inserted through the anus) is a very useful instrument to check that the lumen of the rectum is patent (proximal and distal to the fistula site) and confirms that the tissues you are holding are the fistula edges.

(4) CLOSURE OF RECTUM

Trim the fistula edges until they are soft. It may help to hold the proximal and distal edges of the rectum with Allis forceps. Normally the fistula is closed in a transverse direction (Fig. 7.5). This is less likely to cause narrowing and usually creates the least tension, as there is less mobility laterally due to scarring. However, it may be necessary to close it longitudinally or obliquely.

- Use interrupted absorbable sutures. Always start the repair at each angle, avoiding the mucosa. It is more important to get the mucosa to invert rather than trying to pick up the mucosa. This is done by picking up a sero-muscular layer with the needle and starting 2-3 mm from the edge (Fig. 7.5).

!Tip! Leave the angle sutures (short-end) on an artery forceps and leave them extra-long or on a straight forceps so they are easily identified later.

- The red rectal edges are inverted by pushing the Allis or pickups/ dissecting forceps towards the rectal lumen as you tie the knot (Fig. 7.5). There should be no visible red mucosa if the first layer is closed properly.
- It may help to place a finger or a dilator into the rectum to push the distal edges forward as you place the sutures.
- It is often technically easier to place the proximal bites transversely (Fig. 7.6).
- As you suture towards the midline, it is often better to place the final three sutures but do not tie them until they are all in place.
- The main use of a backhand grip in RVF repairs is shown in Fig. 7.7a.
- If there is a discrepancy in size between the proximal and distal parts of the rectum, either:
 - Place the stitches closer together in the narrower part and
 - Place the stitches transversely in the wider end and vertically in the narrow end.
 - In these cases, check for strictures during the repair. If a stricture is developing, consider incising the narrow (usually distal) end similar to Fig. 7.11c.

➤ A rectal examination is done after placement of all stitches to test that the repair is complete.

One versus two-layer closure: Most fistula surgeons aim for a two-layer with interrupted sutures (Fig. 7.7b) closure. The second layer is made from: (a) Proximally: Rectum or peritoneum. (b) Distally: Rectum or any distal tissues. Occasionally the second layer can be difficult and one good layer without tension has to be accepted. In this situation, consider an intermediate layer. If there is a colostomy, then there is no point in doing a second layer.

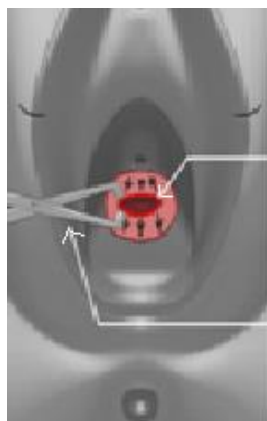


Fig. 7.5: Closure of the rectum. Sometimes it helps to hold the edges with Allis (arrow) or dissecting forceps to help invert the rectal mucosa (arrow).

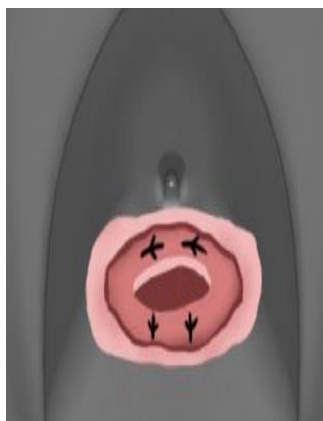

Fig. 7.6: It is often technically easier to place the proximal bites transversely.

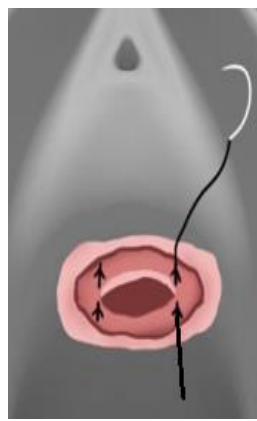


Fig. 7.7a: In this case, the sutures are placed in the distal end first with a backhand grip.

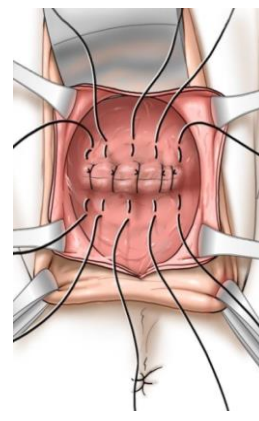


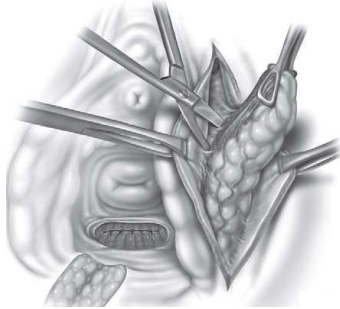
Fig. 7.7b: Shows a second layer of sutures inserted for rectum but not yet tied.

(5) INTERMEDIATE LAYER

While not commonly used in most RVF repairs, this can be considered especially in recurrent, very scarred or post-radiotherapy RVFs. (This is independent of any decision to do a colostomy.) It may also be considered in cases where only a one-layer closure of the rectum is possible. The options are:

- For mid and distal vagina fistulas: suture a sheet of levator ani (pubo-coccygeus) muscle in front of the rectal repair (see Fig. 7.8b). This can be mobilized on one or both sides as in VVF repair and applied as a sling (bilateral) or a patch (unilateral). The muscle is found laterally on each side under the vaginal skin.

- Martius flap (see Fig. 7.8a): It is important not to divide the pedicle graft until it has been determined that the length that has been developed is adequate so measure using a piece of drain or gauze.



- Gracilis flap (see section 8.4): I have used this on several occasions for obstetric RVFs where it was unlikely that they would have healed otherwise. The important tip is to leave the angle sutures (both ends of each) long to be used to fix the graft in place. Fix the muscle on the side closest to the graft first over the fistula. Then fix the far side.
- Use a Singapore flap (see section 8.1) or only the fat/ fascia of a Singapore flap.
- Human Amniotic Membrane is also used as an intermediate layer.

Fig. 7.8a: Shows a Martius graft being used as an intermediate layer in a low RVF.

(6) CLOSURE OF THE VAGINAL WALL

There is usually a significant gap between the proximal and distal edges of the vagina. However, the vaginal edges are already mobilized from the initial dissection and can usually be brought together easily.

- Hold the proximal and distal edges with Allis forceps.
- Use a horizontal mattress suture (Fig. 7.9a). Take the first bite proximally (1), then down to the distal edge (2 and 3) and go back proximally (4) and tie.
- Start at the angles first and do the central part last. Using this method, often large defects can be closed.
- If closing the vagina is likely to result in stenosis, there are two options:
 - i. *Kees neovagina* (see chapter 8): For high and mid-vaginal RVFs with the pouch of Douglas open, the peritoneum is used to form the new vagina. It is much safer to do this at the same time as the RVF repair rather than later as there is little or no risk of rectal injury.
 - ii. Do a skin flap (section 8.1).

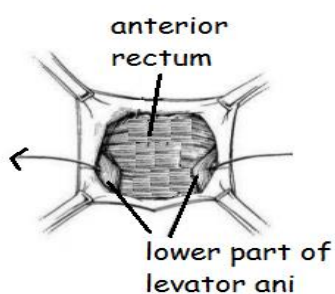


Fig. 7.8b: Shows the levator ani about to be approximated.

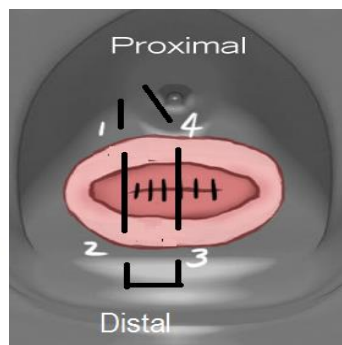


Fig. 7.9a: Vaginal closure with mattress suture.

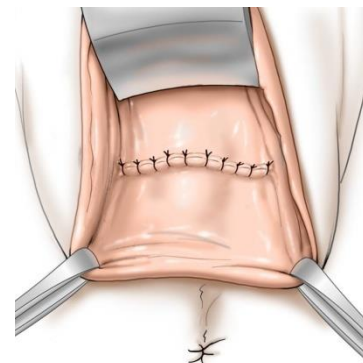


Fig. 7.9b: Shows the vagina now closed. (Courtesy G Chen)

PROBLEMS DURING TRANS-VAGINAL REPAIR

(1) The difficult RVF

- If the fistula appears to be going around to the lateral rectum, place Allis forceps all around to see the limits of the defect.
- The sidewall retractor can be useful laterally especially when stitching the angles.
- If the defect appears to only come together longitudinally, try to close it more obliquely to avoid narrowing the bowel.

(2) **If the RVF is very lateral:** a large episiotomy on the affected side can help greatly. Then, similar to a lateral recurrent VVF, the trick is to free the lateral border of the fistula so that it is mobilized medially.

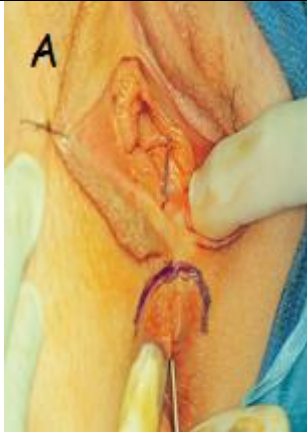


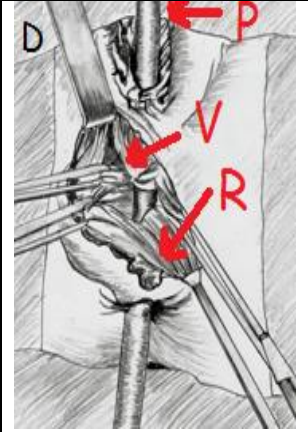


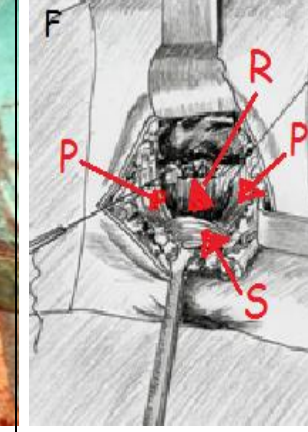

(3) **If heavy bleeding occurs** (see also page 34: Bleeding during fistula surgery):

This may occur when the fistula is stuck laterally and you have to dissect it free. You may hit a large vessel which is the terminal branch of the middle rectal artery.

- Apply a clamp and suture the vessel, or cauterize using low voltage e.g. 20 watts. If you use high voltage, it only cauterizes the superficial tissue, as it carbonizes the superficial layer which then can no longer conduct the voltage. It means that you have to press for longer for the voltage to go deeper.
- If you fail to stop the bleeding:
 - Pack (may soak in diluted adrenaline 1:250,000) and apply pressure for 5 minutes.

- Leave the clamp on for 30 minutes. The operation can usually proceed with the clamp on.
- If available, haemostatic agents e.g. Surgicel or Floseal can be applied to stop oozing.
- On one occasion during vaginal repair when it was difficult to stop lateral bleeding, I packed the bleeding area laterally, repaired the RVF and took the pack out vaginally the next day. Part of the vagina was left open to allow this.
- If heavy bleeding occurs posteriorly over the sacrum, a few stitches with a strong needle may work. If not, abdominal control of the sacral veins (often only by packing or the use of thumb-nails as it can be difficult to see anything) may become necessary and the repair may have to be completed from above.
- (4) **If a second hole develops during dissection:** this is more likely to be proximal than distal to the fistula. It is usually easiest to close this hole together with the fistula (similar to Fig. 3.13b) although separate closure (similar to Fig. 3.13c) is an option if the distance between the two holes is far.

(7.1B) RVF: TRANS-PERINEAL APPROACH

			
<p><i>Probe and index finger helps delineate the fistula and its tract. Fig. 7.10a: Incision is outlined. Fig. 7.10b: Perineal incision made. Fig. 7.10c: Shows the posterior vaginal wall mobilized from the anterior rectal wall. Fig. 7.10d: Shows the same as 7.10c diagrammatically. V = vaginal wall R = rectum P = probe</i></p>			
			
<p><i>Fig. 7.10e: The surgeon's index finger elevates the anterior rectal wall during closure.</i></p>	<p><i>Fig. 7.10f: The rectal defect is closed R = rectum; P= Pubo-coccygeus muscles; S = sphincter</i></p>	<p><i>Fig. 7.10g: Shows the skin incision closed. The vaginal part of the defect is left open.</i></p>	

In addition to the vaginal and abdominal approach, RVFs can be repaired through a trans-perineal approach. The location of the fistula is the main determinant. The trans-vaginal approach is good for those fistulas more proximal from the anal sphincters. For more distal fistulas, the trans-perineal approach allows better access. The trans-perineal approach is most often used in partial breakdown of 4th degree tears and non-obstetric fistulas. The advantages are: (a) It avoids cutting the sphincter for access and so preserves any intact internal and external anal sphincter. (b) If the sphincter is torn, it allows good access to repair it. Note: In the case of a very

small and distal RVF which only causes occasional flatus per vagina, there is the option not to operate at all, as perineal surgery might cause iatrogenic anal sphincter or pudendal nerve damage. *Method:*

- Pass a probe through the fistula. Make an incision in the vagina around the RVF if possible.
- Make a transverse or inverted U incision across the perineal body above the anal sphincter as shown in Fig. 7.10 a + b. This incision can be made at the level of the posterior fourchette i.e. junction of the vagina and the perineal body, or lower.
- The incision is deepened until you reach the probe. Then pull the probe back so that it is only just coming through the rectum.
- Separate the vagina from the anus and rectum proximal to the RVF which is now exposed.
- Dissection is extended laterally and proximally around the fistula between the anterior rectal wall and posterior vaginal wall. Stitch the vaginal wall back with two sutures.
- Excise any scar tissue from the fistulous opening at the rectal end and repair the rectal wall transversely with interrupted sutures to invert the rectal mucosa. It is easiest to do this initially while the probe is still in the rectal opening. A second layer may be placed.
- Approximate any recto-vaginal fascia. Approximate the pubo-coccygeus muscles across the midline.

(7.2) RVF: TRANS-VAGINAL REPAIR: CIRCUMFERENTIAL DEFECTS

Circumferential defects occur in the rectum but are not as obvious as in the bladder. There are two clues:

- Often the lateral angles of the fistula seem to go very far around posteriorly and there is usually a lot of scar tissue in this area.
- When there is marked stenosis, suspect that the defect is circumferential.

The main reasons for doing circumferential dissection is either to help mobilization of the two ends or to resect the stenotic area. The stenotic area is the scarred tissue that bridges the gap between the two parts of the rectum.

- If you cut across the narrow bridge of tissue posteriorly (Fig. 7.11 a) and dissect under the proximal rectum, this allows you to bring the proximal rectum down. The distal part of the rectum also has to be mobilized to a more limited degree.
- After dissection, close the posterior layer, followed by the anterior layer as in any bowel anastomosis. It is better to use interrupted sutures which are mainly placed in the seromuscular layer. The sutures are tied as they are placed.

Posterior wall: Start with a suture posteriorly in the midline placed from inside the lumen of the rectum (Fig. 7.11b) so the knots end up inside the lumen. For exposure, it is easier to work either first to the left and then to the right or the other way around. As you reach the lateral edges, the sutures are placed from outside the rectal wall.

Anterior wall: As you approach the midline anteriorly, it may be better to place several sutures but only tie them once all are placed.

- If not done previously, perform a colostomy.

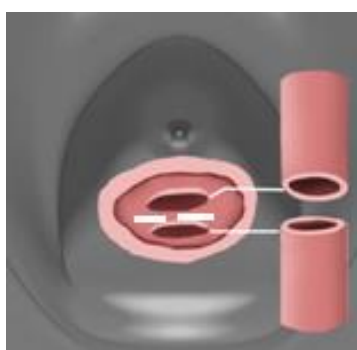


Fig. 7.11a: The white line represents the incision to be made between the proximal and distal ends of a circumferential defect.

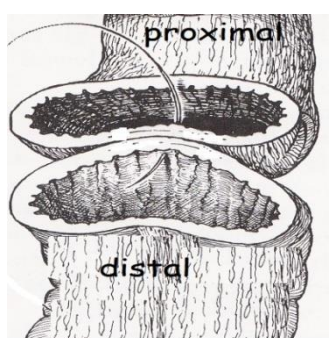


Fig. 7.11b: Closure after circumferential dissection begins in the midline posteriorly as shown.

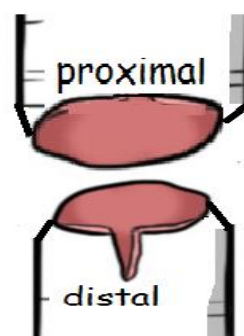


Fig. 7.11c: If there is a large discrepancy in the two ends, the narrower end (distal here) can be incised to enlarge it as shown.

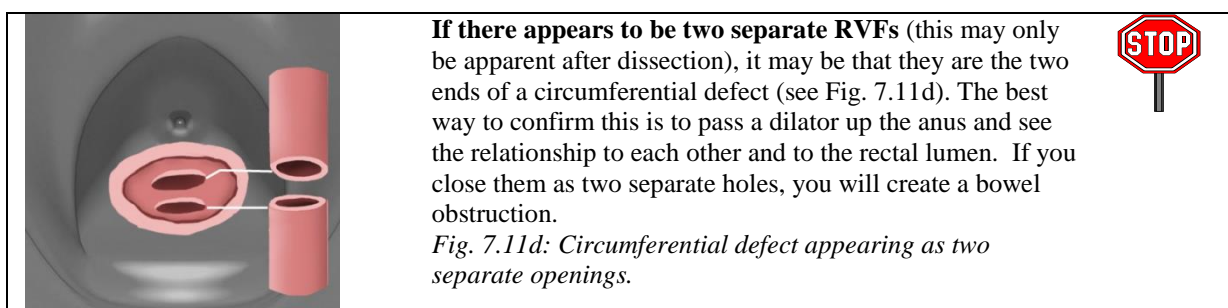
⚠ Top Tip! If there is a discrepancy in the size of the two ends with the distal end narrower, take the bites wider apart or take more horizontal bites on the wider end. If there is still a discrepancy and there is a tendency to stenosis as you close the defect, then an incision on the anterior wall of the narrow end (Fig. 7.11c) will help overcome both of these problems.

Tip! On the right anterior wall, you may find it easier to suture from the distal end to the proximal with the needle as a backhand.

RECTAL STRICTURE: It is important to look for the presence of a rectal stricture due to scarred tissue surrounding the defect. Over 50% of high RVFs have strictures and if you do not do something about the stricture, the RVF will not heal. Mid-vaginal RVFs do not usually have a stricture. The general rule when dealing with strictures is that if you can pass your finger through the stricture, stool will get through. There are two ways of dealing with strictures:

- (i) As they usually occur with circumferential defects, dissecting circumferentially will excise the stricture.
- (ii) If a stricture is found later or you are not doing circumferential dissection, disrupt the stricture digitally or with a Hegar dilator. Aim to get two fingers through the stricture to disrupt the scar as you need to get the diameter of the rectum to about 2.5 cm.

In the past, cutting scar tissue posteriorly at the site of the stricture (less likely to enter the peritoneal cavity than cutting anteriorly) has been advocated. However, it is not advised as there is still a risk of peritoneal entry especially if the stricture is high, and subsequent peritonitis may result which can be difficult to recognize.



(7.3) RVF: ABDOMINAL REPAIR

Indications:

- If the fistula is not visible vaginally.
- If the distal end is visible vaginally but the proximal end can only be accessed abdominally. In this case, start the dissection of the distal end vaginally and then complete it abdominally.

Tip! If the proximal end of a circumferential defect is not easy to see, it is often found in scar tissue in the midline. It is therefore worth doing some dissection vaginally as this may avoid a laparotomy if you find the proximal end.

Positioning for abdominal repair: Place the patient in low-lithotomy so you may access the perineum/ rectum from below as well as from above. This position also allows a second assistant to stand between the legs. Irrigate the rectum with Betadine solution to allow access to the rectum during the operation e.g. to do rectal examinations or pass a large Hegar dilator in difficult cases.

Tip! It helps to place a tube (e.g. large suction tube or a Foley catheter with the balloon inflated) into the rectum as this will help you identify when you enter the rectum during dissection. The Foley catheter can also be used to do an air insufflation test later (see below).

Exposure: Pull up on the uterus with a fundal suture as shown in Fig. 7.12A. A good headlight for visualization is very useful in this space.

Top Tip! A useful trick to keep traction on the uterus is to place the artery forceps holding the fundal suture under traction and then place a towel clip through this to attach it to the drapes.

Dissection: The rectum is sharply dissected off the posterior vaginal wall.

- Start dissection on either side of the rectum by opening the visceral peritoneum. Identify the ureters and work down on either side to below the level of the fistula.
- Next cut across the recto-vaginal/ uterine fold of peritoneum.
- It may help to mobilize behind the rectum to free it to some degree although more full mobilization is only possible after it is freed from the vagina anteriorly (distally).
- The rectum is then opened with scissors where it is stuck to the vagina i.e. at the fistula site. Initially, your left hand stretches the rectum proximally while your right hand cuts. Then your left index finger can be used to feel the remaining tissue to be cut (Fig. 7.12B).

- Mobilize and trim the edges. Check with your finger in order to ensure that there is only one hole.

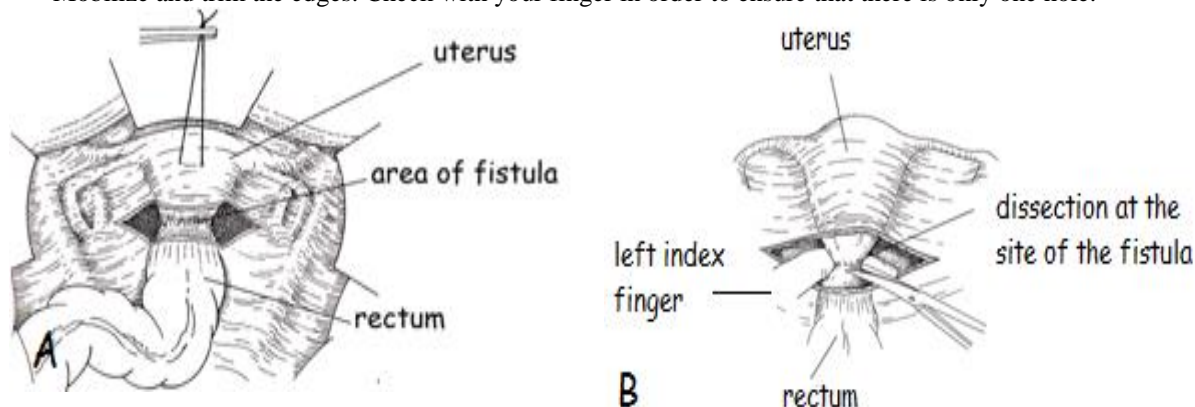


Fig. 7.12: This is the view looking down into the pelvis from above at laparotomy. (A) Fundal suture on uterus for traction, and visceral peritoneum open (B) dissection of the fistula from the vagina. (From Camey M)

Repair of rectum: The proximal and distal edges are held with Allis forceps. Suture the edges together with interrupted stitches (Fig. 7.13a).

- Start at each angle laterally and work towards the centre. Often one edge is wider so watch as you suture in case you need to take bites further apart or place them horizontally on the wider edge.
- Take full thickness or only sero-mucular bites
- One layer is sufficient as the aim is to approximate the edges rather than water-tight closure.
- A colostomy should be performed if not done previously. Some surgeons would be happy not to do a colostomy if they have achieved tension free closure, there is no stool contamination during the operation and the air insufflation test is negative (see below).

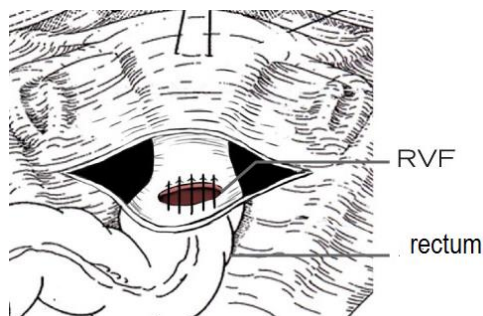


Fig 7.13a: Shows the fistula being closed with a single layer of interrupted sutures. (Adapted from *les Fistules Obstetricales* by Camey M.)

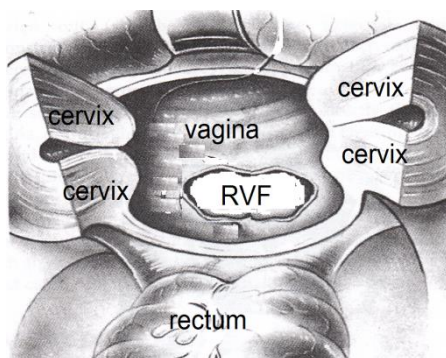


Fig. 7.13b: Shows access to the fistula by splitting the cervix. The fistula is approached anteriorly through the vaginal vault.

If access is difficult due to extreme fibrosis and scarring so that the cervix and vaginal vault are fixed to the sacral promontory, then the usual posterior approach via the pouch of Douglas between the rectum and the vagina is not possible. Instead, an anterior approach is used. First, perform a sub-total hysterectomy and then bisect the cervical stump (in an Anterior-Posterior direction). The two halves of the cervix are retracted to either side, exposing the fistula in the posterior fornix (Fig. 7.13b). This approach can also be used if the RVF seems to be very low abdominally so that you cannot access it even though you have failed to access it vaginally. It is an approach that I have found useful on several occasions. *Reference: Recto-vaginal fistulae following difficult labour. Lawson; JProc R Soc Med. 1972 Mar; 65(3):283-6.*

(7.4) CIRCUMFERENTIAL RVF DURING ABDOMINAL REPAIR

These cases usually have stenosis of the rectum at the fistula site. After dissection and mobilization of the fistula (and excising any remaining stenosed area), you are left with two ends of the rectum to join together. The technique of low rectal anastomosis is used:

! Tip! The distal end of the rectum may retract downwards. Grasp the edges all around with Allis or Babcock forceps to pull it up. If you fail to secure the distal end, you would have to do a pull-through procedure (see below).

! Tip! It is vital to ensure that both ends of the bowel are well vascularised and mobile. You may need to mobilize the proximal end, going behind the mesentery and also up to the sigmoid to achieve this.

! Tip! If there is already a sigmoid colostomy present, it may be necessary to take it down to allow the proximal end of the bowel to come down into the pelvis. After the repair, it is often easier to place a loop ileostomy in the same site or to do a transverse colostomy.

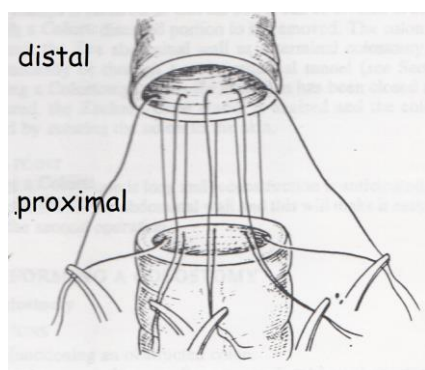


Fig. 7.14a: Closure of a low circumferential defect by abdominal approach. This shows the posterior wall being closed with all the sutures placed but not tied (view from above).

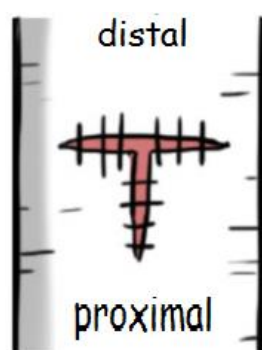


Fig. 7.14b: If the proximal edge is wider, closure of the anterior layer may result in a T-line of closure.

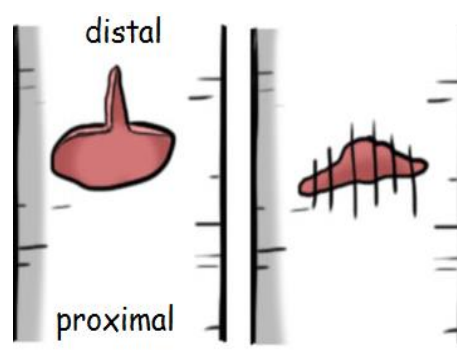


Fig. 7.14c: If the proximal edge is wider, a better option is to widen the distal end by incising the anterior wall as shown on the left.

- (1) Place a **lateral stitch** on each side (3 and 9 o'clock). This is done from out to in and in to out so the knots are outside. These are placed but not tied until you have placed and tied the posterior row.
- (2) **Posterior row:**
 - Usually, start on the right side just medial to the lateral stitch (Fig. 7.14a) and work towards the left side.
 - Place (but do not tie) all the posterior interrupted sutures going through all layers (may avoid the mucosa if you wish). This is done from inside the lumen so the knots end up inside the lumen. Bite first the proximal and then the distal rectum.
 - Retraction on the previous stitch can help place the next stitch.
 - About 9-10 such sutures are placed. Each bite is about 3 mm apart, taking 1 cm of good tissue on each side. Once all these sutures are placed, tie them one by one (starting with the last one inserted) leaving the knots on the mucosal side.


! Tip! It is very important to keep the order of the artery forceps correct to avoid sutures becoming tangled. There are 4 ways of doing this:

- (a) The simplest is to place a square of gauze over each artery forceps as it is placed. Then when tying, just remove one gauze at a time to expose the correct artery forceps as you tie each suture.
- (b) Place the rings of the artery forceps into a closed long clamp e.g. Kochers. One assistant is given the job of holding this to make sure the artery forceps do not fall off the clamp. Alternatively, attach the tip of the clamp to the drapes.
- (c) Use clamps in a specific order that you use every time you need to hold sutures before tying e.g. use curved artery, straight artery, large artery, Kocher's etc.
- (d) If available, a Lone Star retractor can be used.


(3) **Anterior row:** First tie the initial lateral stitch on each side.

Place the anterior layer of sutures (interrupted) but tie as you place each one. Work from lateral to medial on each side so that you finish in the midline.

- If standing on the left side, place the sutures from proximal to distal.
- If you (or your assistant) are standing on the right side, it is easier to insert the sutures from distal to proximal.
- As you get towards the centre, it is better to place but do not tie the last 3-4 sutures until all are placed.

 **Tip!** Placing the tip of a right-angled clamp into the rectal lumen is a useful way of displaying the anterior rectum (especially for the distal edge) as you are closing the anterior row.

It is important to work from lateral to medial on each side so that you end up in the centre. Otherwise, you will have trouble lining up the edges. The proximal end is often much wider than the distal. This becomes apparent when closing the anterior layer. To overcome this, use the next top tip.

 **Top Tip!** The colon is usually wider than the rectum. Spacing the proximal bites wider apart will overcome most discrepancy. However, you should start doing this on the posterior row as otherwise there will be a large discrepancy when you get to the anterior row. If you have managed the discrepancy poorly, you may have to stitch the proximal end to itself in a T (Fig. 7.14b). A better alternative is to make a vertical incision in the midline of the anterior part of the distal rectal end to make it wider (Fig. 7.14c). When closed, this will stretch into a linear incision and avoids a T-junction so it should heal better. However, as the distal end may already be short, it may not be possible to do this. Note: Both of these options should rarely be necessary.

Test: During abdominal repair, the anastomosis can be tested by injecting air via a Foley catheter (balloon inflated 50 ml) in the lower rectum while clamping the sigmoid colon with your hand. The pelvis is first filled with saline and 60 ml of air is injected with a bladder syringe up the Foley catheter in the rectum which should be seen to distend. If there is a leak of air, it would be safer to do a colostomy in addition to inserting more sutures in the leaking area. The converse is also true. If there is no air leak on testing, this would indicate that you have achieved a good repair and a colostomy may be avoided.

COMBINED ABDOMINO-PERINEAL (PULL-THROUGH) PROCEDURE FOR CIRCUMFERENTIAL DEFECTS

Situation 1 (Fig. 7.15a): The distal rectum can be visualized vaginally: Sometimes there will be a large gap between the proximal and distal end of the rectum. The distal end may be just a few centimetres above the external sphincter. In this case, the proximal end may have to be mobilized abdominally and then pulled through into the vagina. It can then be anastomosed (end-to-end) with the distal end (ano-rectum). This is relatively easy to do provided there is plenty of length on the rectum. Ensure the proximal end reaches beyond the pubic symphysis from the abdomen before you pull it through the pelvic floor.

If the anterior wall of the distal rectum is involved by a tear and a fistula, it may appear that it is almost completely absent. However, usually the anterior wall is partly retracted rather than absent. You have to anastomose the proximal end (anterior and posterior walls) to this (“posterior” wall). Just start posteriorly in the midline and work around on both sides. You have to gain more distance on the proximal edge by spacing the sutures further apart. If stenosis is developing, see Fig. 7.11c.

Situation 2 (Fig. 7.15b): The distal rectum cannot be approached vaginally i.e. the fistula is too high to approach vaginally and too low to anastomose abdominally i.e. there is not enough length of distal rectum to work with from above. A colo-anal anastomosis is performed. This method can be used for:

- (a) Post-radiotherapy fistulas
- (b) Obstetric fistulas: When doing an abdominal repair of a circumferential RVF, if you find that the distal end is too short or tears distally as you try to anastomose, then it is better to do a pull-through.

Method:

- The left colon is mobilized to include the splenic flexure. If there is already a sigmoid colostomy, this has to be taken down and closed.
- Incise the peritoneum to the right and then to the left of the rectum. Identify the left ureter.
- To separate the rectum from the vagina, first divide the peritoneum. Then pull up on the vagina/ uterus, while pushing down on the rectum.
- It is often easiest to transect the rectum at the site of the RVF and then mobilize the rectum proximally.
- Once the rectum is mobilized, place two strong sutures on either side of the rectum laterally which are used to pull it through to the anus. Do not twist the rectum. Use the two stay sutures to check for this.
- As the rectum will have been cut (from above) 4-8 cm above the dentate line, you need to excise distal rectal mucosa from below to leave a short ano-rectal ring for joining to the pulled through rectum; otherwise you cannot access from below to do the anastomosis. The mucosa is excised by injecting saline with diluted adrenaline under it and dividing it into 4-6 strips of 3-4 cm width. Starting posteriorly, make two longitudinal incisions into the rectal mucosa, and then a transverse incision 2-4 cm above the dentate line. Then with scissors undermine and excise the mucosa. This is repeated all around the rectum. Some mucosa will occasionally be left and this can lead to mucus and abscess formation. Some surgeons use the cautery to excise the mucosa.

- The anastomosis is performed trans-anally 2-4 cm above the dentate line. Use approximately 12 stitches of interrupted 2/0 Vicryl. Place sutures at 12, 3, 6 and 9 o'clock but do not tie. Then place sutures in between these but tie as you go. In this way, you have sutured the rectal ring to the anal ring all the way around, with the knots facing the lumen (Fig. 7.15b).
- Always do a defunctioning (transverse) colostomy or loop ileostomy.

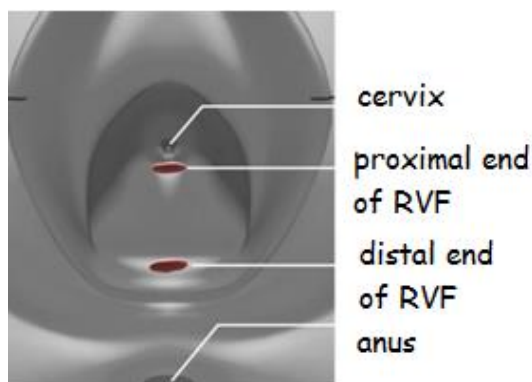


Fig. 7.15a: The type of defect that may require a pull-through procedure performed by a vaginal/perineal approach (Situation 1).

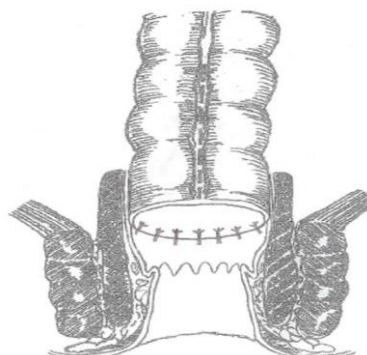


Fig. 7.15b: A colo-anal anastomosis which is performed 2-4 cm above the dentate line (Situation 2).

Post-operative care: if she develops a fever, you need to do a rectal examination and drain anything via anastomosis. If an abscess develops it is best to drain it proactively rather than to wait for it to drain spontaneously.

The following applies mainly to post-radiotherapy fistulas where it is often possible to divide the rectum at a lower level as the RVF is lower:

- Get into the plane behind (posterior and lateral to) the rectum to mobilize completely down to the pelvic floor. The plane separates the rectum from the sacrum and lies between:
 - The mesentery at the back and sides (posterior and lateral) of the rectum which is largely fatty tissue and blood vessels which is known as the mesorectum. It has a smooth bilobed surface.
 - The pre-sacral fascia. Cutting this layer exposes the sacral veins so if you see the blood vessels of the sacrum, it means you are in the wrong plane.
- By getting into this plane (known as the Holy Plane), there should be no bleeding whereas if you dissect too close to the rectum or sacrum, bleeding will occur. If in doubt, stay closer to the “serosa” of the rectum than the sacrum.
- In circumferential RVFs, you may hit the area where the RVF is stuck posteriorly as you go down this plane. It is then necessary to use sharp dissection to mobilize the rectum.
- Place one clamp transversely across the rectum as low as you can. Then by placing your fingers over the clamp, pull up on the rectum.



Tip! An assistant can place his finger in the rectum to help you identify the lower rectum from above.


- Transect the rectum as low as you can, ideally about 2-4 cm above the dentate line.
- You may have to then trim proximally to excise the fistula.
- If you are able to transect low, you do not then have to excise any rectum or rectal mucosa from below.

LATE STENOSIS

In some cases, there is marked stenosis at the fistula site before any repair. If a colostomy is performed, the stenosis can become complete as stool is no longer dilating the site. I have seen several cases where a colostomy was performed for an RVF and eventually the rectum became completely stenosed. The RVF appeared to have “healed” and the dye test was negative. Only by doing a rectal examination could the stenosis be felt high up. The stenosis involves both the rectum and the surrounding tissues in the pelvis, at the level of the pelvic brim/sacral promontory. Resection of the involved stenosed area of the rectum with anastomosis has to be performed abdominally similar to circumferential RVF repair.



Tip! If there is uncertainty about stenosis, an examination under anaesthesia is indicated. Almost always you can feel the stenosis from below, especially in an anaesthetized patient.

 **Tip!** When an RVF has been repaired and there is stenosis at the site of repair, if you can pass your finger through the stenosed area, the colostomy should be closed after 6 weeks, provided a dye test (done via the colostomy) shows no leak.

POST-OPERATIVE CARE AFTER RVF REPAIR:

- (a) *If vaginal approach:* Intravenous fluids only until flatus passed. This should be followed by oral fluids/light diet (e.g. soup, yoghurt) only until day 7. An alternative regime that is used is to allow the patient to drink the same day, thick fluids on day 1, light diet day 2 and normal diet with laxatives from day 3.
- (b) *If abdominal approach:* Start oral fluids when the stoma is working and start solid food once fluids are tolerated. The stoma is closed after 6 weeks. If you wait too long, the fistula site can become narrow, as it is not being dilated by faeces.

If stool leaks from the RVF repair site:

- Irrigate the vagina with a syringe to keep it clean after any bowel motion. Get all the stool out. It is still possible that the RVF may heal. This can even be done by the patient herself after proper instruction. Combined with a low residue diet, irrigation may protect any VVF repair from breaking down and also increases the chances of RVF healing
- Consider doing a colostomy especially if you think the repeat repair will be difficult. With a colostomy, there is even a chance that the fistula may heal without further surgery.

Case History: A primiparous patient had a Caesarean section for obstructed labour with a dead baby. She developed a VVF and an RVF. Stool was also coming through the abdominal wound. At laparotomy, there was just a narrow rim of tissue joining the proximal and distal rectum at the site of the RVF. This was divided and the proximal end brought out as an end colostomy. After 5 months, the VVF was closed vaginally. At the same time, the rectum was re-anastomosed abdominally. At laparotomy, it was difficult to locate the proximal part of the distal rectum. A large Hegar dilator was passed up the anus into the rectum and this made it easy to find the rectum. After re-opening the distal rectum, an anastomosis was performed with interrupted sutures as described above.

(7.5) ANAL SPHINCTER TEAR (SECONDARY) REPAIR

The internal anal sphincter is responsible for the resting tone of the anal canal. This smooth muscle group has the major responsibility for continence of liquid stool and flatus. It relaxes in response to filling of the rectum. Tears of the internal sphincter lead to passive soiling and flatus incontinence.

- The internal sphincter is in the distal 2.5 - 4 cm of the ano-rectal wall.
- In fresh tears, you can identify the internal sphincter just above the ano-rectal mucosa/serosa and it has a white, or pale and fish like appearance. It often retracts laterally and superiorly but can be identified most easily at the apex of the tear. i.e. the ends of a torn internal anal sphincter are often located lateral to the ano-rectal mucosa. It should be included in the second layer after the mucosal repair. Allis clamps can be placed on the ends of the retracted internal anal sphincter to facilitate repair.
- In old tears, it is difficult to identify the internal sphincter. If you close the ano-rectal wall in two layers, this may approximate the internal sphincter.

The external anal sphincter and the medial part of the levator ani (pubo-rectalis), both striated muscle groups, are mainly responsible for continence of solid stool. The external sphincter responds to the sudden filling of the rectum secondary to the peristalsis of the bowel.

- The external sphincter is red and meat-like and is 2.5 cm long. It is covered by a capsule and laterally is the ischio-anal fat.
- The length of the sphincter is the best predictor of continence as it is a high-pressure zone.
- Contraction of pubo-rectalis can compensate for a torn external sphincter for a while.

Patients who have tears to both the internal and external sphincters have more symptoms compared to those with tears of the external sphincter alone.

Diagnosis: If you are not sure if the sphincter is torn or not

Inspect: With a partial tear of the external sphincter, look for absence of the skin folds anterior to the anus.

Palpate: Place the index finger in the rectum, and the thumb in the vagina. This will enable you to detect any loss of sphincter bulk, suggesting an underlying third or fourth degree tear.

Move: Ask the woman to contract her anal sphincter while performing a gentle rectal examination and any loss of tone will suggest an underlying sphincter defect.

If the patient presents with an infected tear, you have to wait until it is clean before you can repair. It is best to debride aggressively, treat with antibiotics if indicated and give sitz baths 2-4 times daily. Adding detergent to

the water such as Omo is strongly recommended. The repair can be performed when the tissues look healthy. It is not necessary to wait 6 weeks or longer before repairing.

Reference: *Obstetric Trauma Surgery: sphincter ani rupture. Kees Waaldijk January 2016.*

Pre-operative preparation

- Keep on fluids only for 1 to 2 days pre-operatively.
- Give an enema the day before to ensure the lower colon is empty. An enema given the morning of surgery often only provokes continuous passage of liquid stool during the operation. Alternatively, full oral bowel preparation may be used as described for RVF.
- A colostomy is usually only considered if there have been two failed repairs previously i.e. on the third attempt.
- Give intra-operative prophylactic antibiotics as the risk of infection is higher with secondary compared to primary repairs. Metronidazole alone or combined with gentamycin or a cephalosporin are the common ones used.

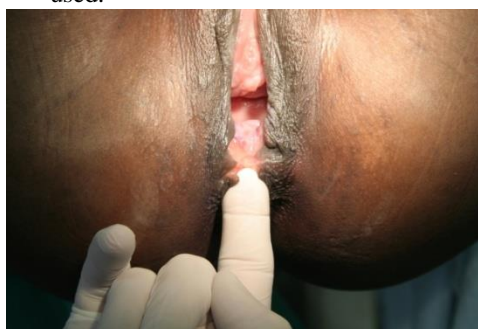


Fig. 7.16 a: Example of 4th degree tear.

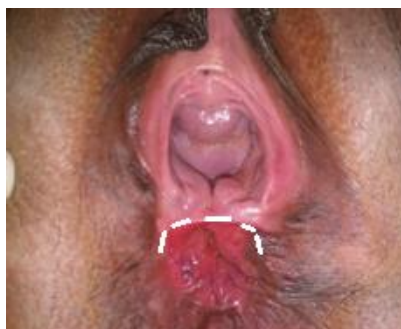
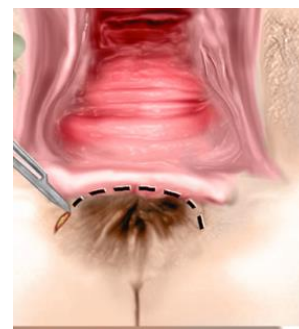
Fig. 7.16b: Shows the initial incision made to separate the vagina from the rectum.



There are 3 techniques in repairing these injuries:

- Do a limited dissection enough to just approximate the sphincters end-to-end: commonest method.
- Do a major dissection to allow overlapping of the sphincters.
- Approximate the sphincters with sutures without dissecting them out i.e. omit step 3 below.

(STEP 1) INCISION

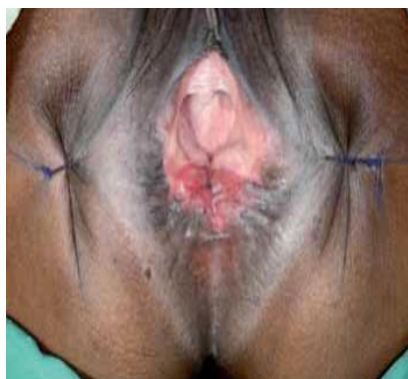

Fig. 7.17a: Shows a stay suture inserted on both sides. (K Waaldijk)

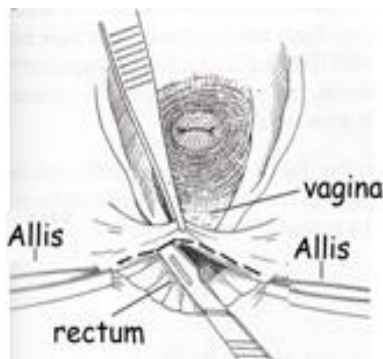
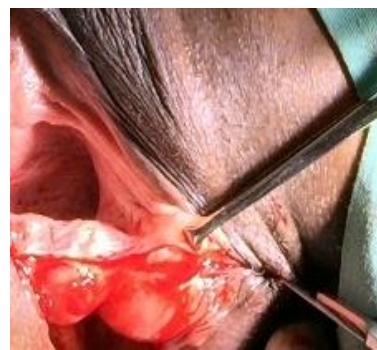

Fig. 7.17b + c: The incision is made at the junction of the vagina (pink) and the rectum/ anus (red).



- Infiltrate with a vasoconstrictor i.e. diluted adrenaline solution.
- Stretch the skin at the junction of the rectum and vagina between two Allis forceps as shown in Fig. 7.17b. Alternatively, place a stay stitch on each side from just lateral to the anterior rectal edge (at the level of the retracted sphincter ends) to the skin laterally. This stretches the anterior border of the anus (see Fig. 7.17a).
- With your left hand holding a toothed forceps, place these just inside the vagina to pull it up (7.17b).
- Make a transverse horizontal incision with a knife at the junction of the rectum and vagina – shown by the interrupted line or the red - pink junction (Fig. 7.17c). The options are:
 - (a) Extend the incision about 1 cm laterally onto the skin on each side (Fig. 7.17c) or
 - (b) Do not extend the incision onto the skin. Instead, go around postero-medially onto the rectum-skin junction for 1-2 cm (see Fig 7.16b). However, if you extend this too far posteriorly, it may compromise the blood supply to the anus. This method is easier to close and gives a better cosmetic result.
- You may need to excise a narrow strip of scarred rectal and vaginal mucosa that has healed together.

(STEP 2) SEPARATE VAGINA FROM THE RECTUM

Separate the vagina from the rectum for about 4 cm proximally, using a knife to cut the tissue off close to the vagina (Fig. 7.18c).

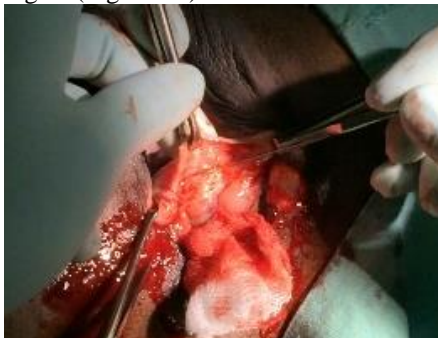

Fig. 7.18a: The vagina is being separated from the anus/ rectum with a knife. Finger is in the vagina.

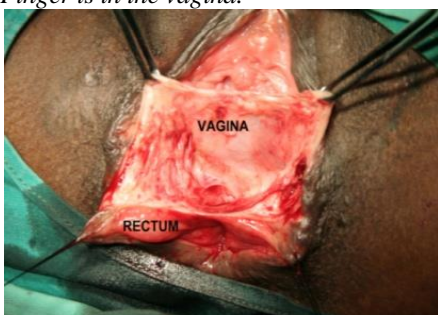

Fig. 7.18c: Aim to separate the vagina for 4-5 cm proximally.

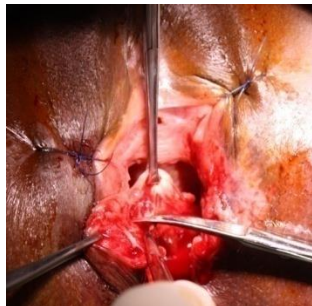


Fig. 7.18b: In this case, the vagina is being separated with scissors in the right hand and pickups in the left hand.

⚠ Tip! Keep your finger in the vagina and dissect close to this to avoid opening the rectum. Have Allis forceps on both the rectal and vaginal edges to help develop the plane of dissection.

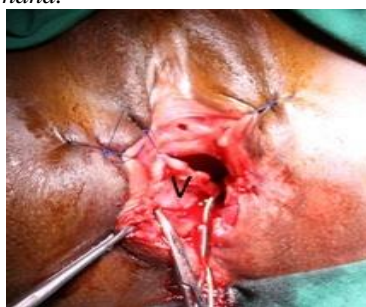

Fig. 7.18d: Once the vagina (marked V) is separated, place a stay suture on each side (right shown here) to retract the vagina for exposure.

Tips to identify the external sphincter: (this has to be read along with step 3)

The difficult part of the operation is to identify the two ends of the anal sphincter. Defining the boundaries of the anal sphincter is easier in fresh tears as opposed to old tears. There are two ways that help to define the sphincter:

- (1) Remember that the sphincter goes around the anus. The sphincter should appear as red/ purple muscle fibers coming from the postero- lateral direction. Using an Allis clamp, grasp where you think the sphincter should be i.e. just lateral to the rectum/ anus. It helps to direct the Allis clamp from medial to lateral (at a 45-degree angle) pushing the Allis head into the tissue where the end of the sphincter may be and then opening and grasping. Then pull this tissue medially. The tissue feels substantial and you can see the outer skin wrinkle as you grasp. Then with your finger in the anus (Fig. 7.20c), feel for the sphincter posteriorly and then at the sides. As you pull on the Allis (which is grasping the sphincter), feel if this tightens the posterior and lateral parts of the rectal/ anal wall. This is the most useful way to confirm you have identified the sphincter.
- (2) The fat of the ischio-rectal fossa lies lateral to the sphincter so if fat is seen, the sphincter should be medial. The sphincter lies between the anal mucosa and the fat.

(STEP 3) DISSECT OUT THE SPHINCTER

(a) *Limited dissection:* Most surgeons now do a more limited dissection of the sphincter i.e. pass an Allis forceps down on either side of the rectum, grasp the sphincter (confirmed on rectal examination as in Fig. 7.20c), and mobilize it just enough to approximate it.

(b) *More extensive dissection of sphincter:* Only performed if overlapping of the sphincter is planned.

- Holding the lateral edges of the initial incision above and below with Allis forceps, push scissors into the incision and open them in an anterior-posterior direction (Fig. 7.20a). Now you should see the fat which is lateral to the sphincter (Fig. 7.20b).
- With an Allis forceps go posteriorly just lateral to the rectum/ anus to pull up the sphincter.

Once identified and grasped, mobilize the sphincter circumferentially:

- (a) Posteriorly from the skin and anal mucosa: With an Allis on the anal edge, keep your index finger in the rectum to avoid button-holing the rectum as you dissect. Either use a knife or a partially opened scissors to free the tissues.

(b) Medially, laterally and anteriorly.

Stay close to the vagina and rectum all around as you mobilize the sphincter.

- The sphincter edges should be freed so that they come together in the midline without tension.

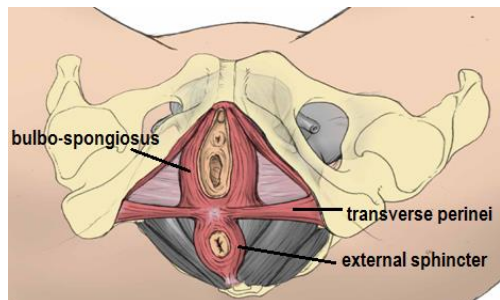


Fig. 7.19: Shows the normal anatomy.

The main structures that can be confused with the sphincter are the transverse perinei muscles. These come into the perineal body laterally whereas the sphincter approaches posteriorly. If you pull on the transverse perinei, you will stretch the lateral tissues and not feel traction with your finger in the rectum.

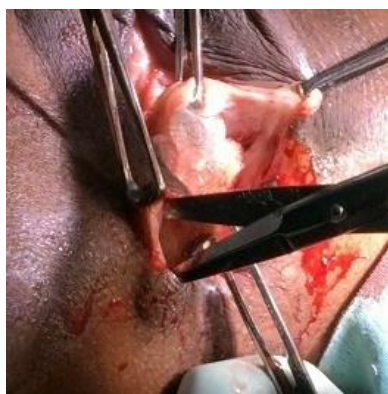

Fig. 7.20a: Scissors are inserted into the lateral part of the incision and opened longitudinally.

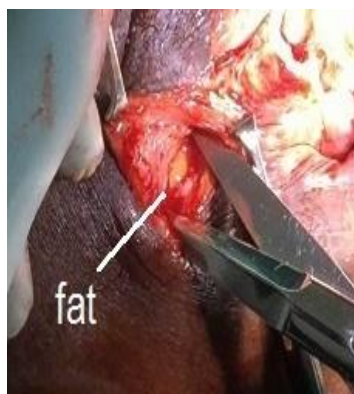

Fig. 7.20b: Lateral to the sphincter is ischio-rectal fat as seen here.

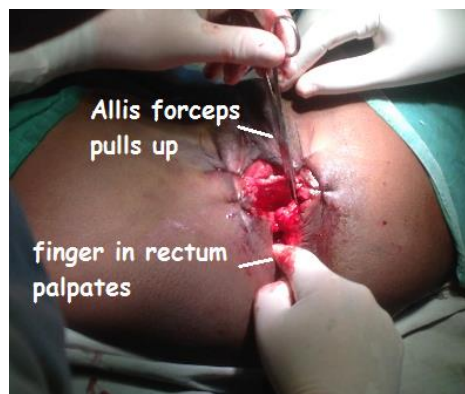


Fig. 7.20c: With your right index finger in the anus, palpate posteriorly as you pull up on the Allis forceps (holds the external sphincter) with your left hand.

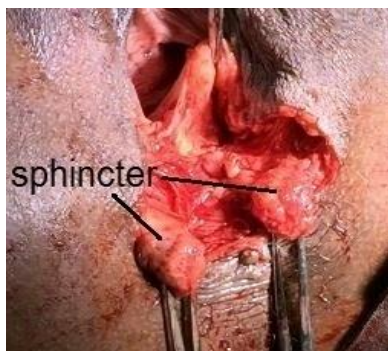
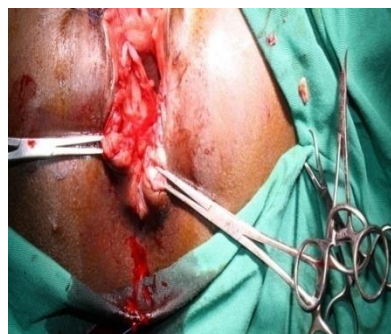

Fig. 7.21a+ b: The sphincter is mobilized and ready for approximation. A useful tip to keep the sphincter out of the way while closing the rectum is to retract the sphincter by placing it under tension. Insert artery forceps or a towel clip through one ring of the Allis forceps holding the sphincter and attach the artery or towel clip to the drapes out laterally as in the photograph on the right.



Tip! The levator muscle is seen proximal to the external sphincter. You can place several sutures to approximate the levator muscle across the midline before approximating the external sphincter.

(STEP 4) CLOSE THE RECTUM/ ANAL CANAL

This is done in two layers to reduce the risk of flatus leaking through the suture line with a one-layer closure.

First layer: Insert 2/0 or 3/0 Vicryl interrupted sutures every 3-4 mm with knots outside the lumen.

- The key is to suture in such a way that there is no mucosa protruding on the vaginal side i.e. invert the mucosa. Aim to get good bites mainly of pre-rectal fascia which provides strength and avoids the mucosa. The internal sphincter is often included in the first layer closure.
- Keep the short ends of the first layer of sutures on artery forceps to be used later.

- Start at the apex and work distally. It is important to keep suturing the rectum distal to the ano-cutaneous border (pink/ brown) so that you see the complete anal ring re-formed. If you stop prematurely, it will be very difficult to get sutures into this area later.
- If necessary, you can do the last stitch from the outside i.e. go in through the skin (1 cm bite) on one side and back out to the skin on the other side. This stitch is mattressed so go back to the initial side and tie.

Second layer of the ano-rectum is now placed as:

- A continuous or interrupted stitch(es) which is inserted parallel to the edges and quite lateral. This layer is placed from proximal to distal.
 - Tie the second layer sutures to the short ends of the first layer (interrupted continuous) if a continuous suture is used.
- Sometimes only one layer is possible and this is acceptable.
- Remove the stay suture on the skin now to remove any stretch on the sphincter.

(STEP 5) APPROXIMATE THE EXTERNAL SPHINCTER: there are three methods used:

- (a) **Simple end to end anastomosis** (non-overlapping): This is the commonest method used. In this case, after dissecting the sphincter, either place 2-3 interrupted mattress sutures (PDS 2/0 or 0 is preferable to Vicryl) to join the ends of the sphincter together or insert several interrupted sutures as in Fig, 7.21c.

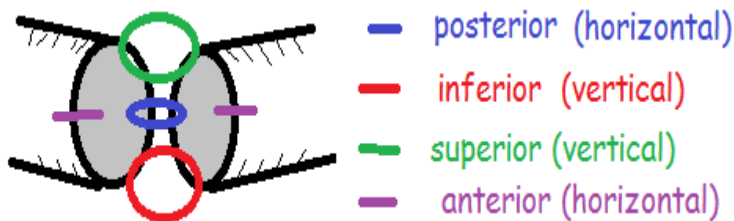
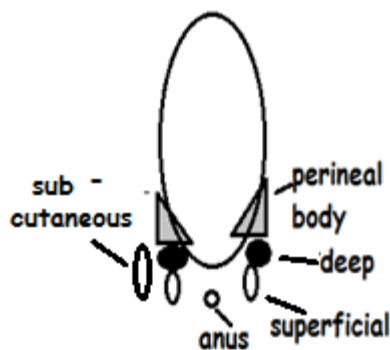


Fig. 7.21c: The sphincter is approximated with figure of 8 sutures x 4 placed in a specific order - PISA. (P) Posterior stitch joins the posterior part together. (I) Inferior suture (S) Superior suture (A) Anterior suture. Extra sutures may be placed if there is a lot of tissue.

- (b) **Technique for approximating sphincter without dissecting it out:** The tissue is approximated by passing the needle into the area that you know the sphincter will be. Three separate sutures are inserted to approximate the external sphincter:



- *The superficial part* of the external sphincter is the part closest to the anal canal and just under the skin. This is inserted deep and parallel to the lowest skin beside the ano-cutaneous junction. When this is tied, you can see the anal ring re-formed fully. Leave the short end of the suture long on an artery forceps. Light traction on this helps place the next suture.
- *The deep part* is more proximal to (or above) the superficial part. Traction on the superficial sphincter suture makes it easier to place the deep one. This is also inserted deep and parallel to the skin but just above the superficial part.
- *The subcutaneous part:* The needle is inserted just above the deep part. The bite is taken by going out more laterally and downwards. You should be able to see the needle scraping just under the skin.

Fig 7.22a: The perineal body is more anterior than the external sphincter.

(c) **Overlapping technique:**

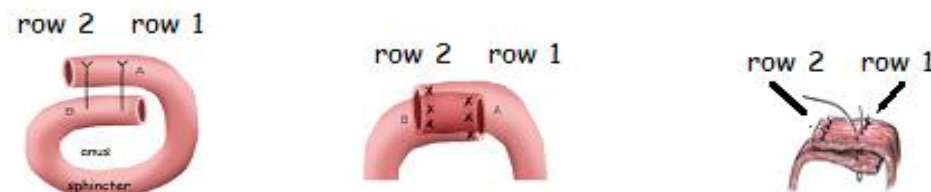
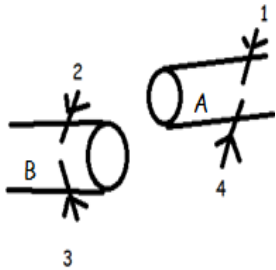



Fig. 7.22b: Shows how the sphincter is overlapped. The left side of the sphincter (A) being pulled over the right side (B). Fig. 7.22c + d: is a view from above to show where the 3 sutures (marked x) are placed for each row.

 <p>Fig. 7.22e: Shows the suture for the first overlapping row.</p>	<p>For the first row, 2 - 3 sutures are inserted, one proximal (posterior) and one distal (anterior) and one in between (Fig. 7.22d). Place and clip all 3 before tying. Do not tie too tight to avoid excessive tension on the sphincter. This should overlap the sphincter.</p> <p>To get the sphincter to overlap, each of these is placed in a specific way taking four bites (Fig. 7.22e):</p> <ul style="list-style-type: none"> Bite 1 = on side A from top down at least 1.5-2 cm back or as far as it allows you to. Bite 2 = on side B from top down about 1 cm from the edge. Bite 3 = on side B go from bottom to top about 1 cm from the edge. Bite 4 = on side A, go from bottom to top at least 1.5 cm back or as far as it allows you to. <p>The second row needs to be medial to the first row (Fig. 7.22b, c, d). Just place two simple sutures to tie down the overlapping part. Tie each as you place them.</p>
--	---

(STEP 6) APPROXIMATE THE PERINEAL MUSCLES FROM SIDE TO SIDE.

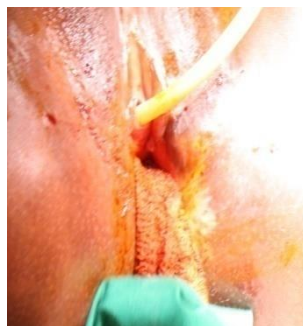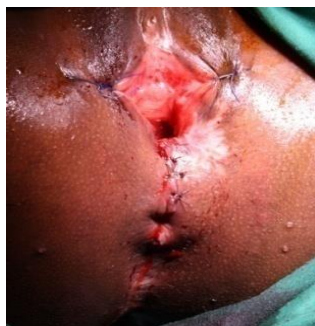Aim for three sutures in the perineal body which may include levator ani.

- The first is inserted just above (i.e. superficial to) the external sphincter.
- The next is inserted proximal/ above this one. However, if you insert too many sutures proximally, it will narrow the vagina. Use a 36 mm needle to get good bites. The sutures are inserted horizontally taking a bite on each side.

	<ul style="list-style-type: none"> • If you build up the perineum with too many sutures before you start closing the vagina, you can have difficulty getting access to close the vagina. If necessary, start closing the vagina before you place too many sutures in the perineum. • The anal opening should not be too tight and should admit one finger easily. Therefore, narrowing should be avoided when approximating the anal canal and the sphincter. You need to assess this early when closing the ano- rectal mucosa and then at each subsequent step in the closure. If the opening is too narrow, this may cause faeces to leak through the repair above the anus and disrupt the closure.
--	---

(STEP 7) REPAIR THE VAGINA AND PERINEAL SKIN

Close the vagina longitudinally, even though the initial opening was transverse. The vaginal opening should be able to admit at least two fingers. Avoid closing the vagina too tightly to allow for drainage and reduce the risk of sepsis. You only need to achieve haemostasis. Also, the perineal skin is closed loosely. Consider inserting a drain under the skin.



! Tip! Avoid closing the vagina or the perineal skin fully as this will often lead to sepsis. It makes sense to leave part of the vaginal aspect open for drainage provided you have secured haemostasis. Place a stitch at the apex of the vagina. Then leave a gap of 1-2 cm. Alternatively, place a drain under the skin.

Fig. 7.22f: Shows the perineal skin approximated. Fig. 7.22g: Gauze soaked in Betadine over the wound.

<p>Summary of 4th degree tear repair</p>	
(a) Rectum/ anal canal:	two layers – first interrupted; second interrupted or continuous 2/0 or 3/0 Vicryl.
(b) Sphincter:	approximate with 2/0 or 0 PDS interrupted sutures for end to end closure.
(c) Perineal muscles:	interrupted 0 or 1 Vicryl.
(d) Vagina and perineal skin:	approximate as loosely as possible.

Postoperative Care

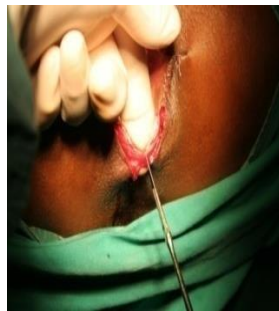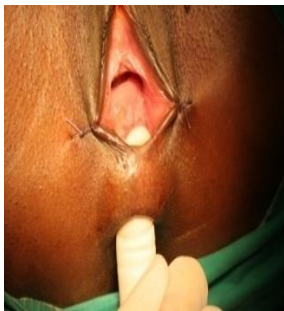- (a) Diet: A balance should be found, avoiding constipation which is painful, and diarrhea which is difficult to clean. There are two approaches but no clear evidence for either:

- Commence normal diet on day 1-2.
 - Keep on fluids only for 3-5 days. This avoids stress on the repair with the passage of stool. Soup or yoghurt is allowed. This allows the wound to be healing well before any stool is passed.
- (b) *Hygiene:* Wash with water after each bowel motion to avoid faecal matter on the wound and then dry. Avoid prolonged soaking as this will encourage suture breakdown. Sitz baths are only used for infected cases.
- (c) *Avoid constipation:* A stool softener (e.g. lactulose 30 ml 3 times/ day or bisacodyl/ Dulcolax 2 x 5 mg tablets daily) can be started once the patient is on a full diet and continued for a week. Keep her in hospital until she has passed 2 bowel motions.
- (d) *Avoid urine retention:* this is a common problem after this operation so keep the catheter in for two days although some units remove it on the first day.

Complications:

- You may see superficial skin separation in the first 2 weeks post-operatively. Do not confuse this with total breakdown, as the sphincter is usually intact. Maintaining hygiene is all that is necessary and reassure the patient.
- If the wound becomes infected, remove the skin sutures and prescribe frequent sitz baths.

(7.6) ANAL SPHINCTER TEAR REPAIR WITH RVF OR POSTERIOR DEFECTS



- (1) If the RVF is really the unhealed apex of a 4th degree tear which has partially healed i.e. there is almost no sphincter tissue intact: Convert RVF into a 4th degree tear by incising the bridge of tissue (Fig. 7.23) and carry out the repair as in section 7.5. This approach (fistulotomy = cutting the entire bridge of perineal tissue superficial to the fistula) can also be used for any fistula that is very distal and superficial.

Fig. 7.23a +b: Show a low RVF which is converted to a 4th degree tear. A trans-perineal approach would have been a better option here as the bridge of tissue is large and the sphincter is probably intact at least partially.

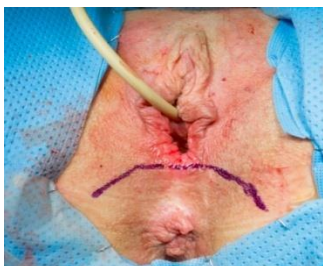

Fig. 7.24: Shows the incision for repairing a sphincter tear alone.

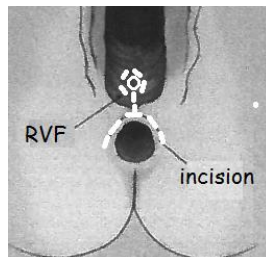


Fig. 7.25: Approach to separate RVF and sphincter repair.

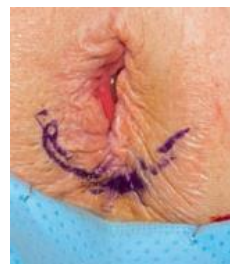

Fig. 7.26: Shows the incision for repair of a posterior defect of the sphincter in addition to an anterior defect.

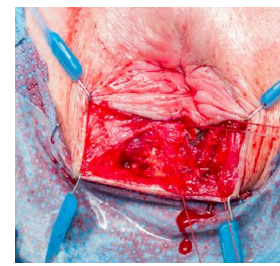


Fig. 7.27: Shows the incision made and the sphincter being re-approximated.

- (2) If there is a mid-vaginal RVF with a very deficient sphincter. In this situation, an incision is made as shown in Fig. 7.25. Then repair the RVF and the sphincter separately with good exposure of both. This is a variation of the trans-perineal approach described in section 7.1B.
- (3) If there is a sphincter tear alone (3rd degree), this can be approached as in Fig. 7.24.
- (4) **Combined Anterior and Posterior Anal Sphincter Repair:** If after repair of the anterior part of the sphincter, the posterior anus is gaping (see Fig. 7.26), then there is probably a defect of the posterior sphincter. Sutures are placed to approximate the posterior fibres of the anal sphincter (see Fig. 7.27). Keep a finger in the rectum to avoid penetrating the rectal wall. Also, approximate the puborectalis and pubococcygeus muscles posteriorly.

CHAPTER 8

PROBLEMS WITH VAGINAL CLOSURE AND FLAPS IN FISTULA SURGERY

Section 8.1: Flaps to close the vagina during fistula repair
Section 8.2: Managing vaginal stenosis
Section 8.3: To improve healing of the fistula: Martius flap
Section 8.4: To improve healing of the fistula: Gracilis flap

(8.1) FLAPS TO CLOSE THE VAGINA DURING FISTULA REPAIR

Not uncommonly, there is a problem obtaining sufficient vaginal skin to reform the vaginal wall if the fistula is large (> 3 cm) or there is a lot of scarring. There are a number of ways to overcome this problem:

- For large defects > 2 cm size: the Singapore flap is the best.
- For smaller defects < 2 cm size: the Labial flap is useful.

SINGAPORE FLAP

The Singapore flap has the great advantage of causing minimal or no disfiguration. It can be used for cover of the anterior, lateral or posterior vagina, or for all if necessary, by taking a flap from each side.

The blood supply is based on the posterior labial artery as it branches from the internal pudendal artery. To maintain the blood supply, the flap is based inferiorly just medial to the ischial tuberosity. To preserve the blood supply:

- (1) Cut down directly through the fascia at a width that corresponds to the maximum skin width. This width has to be maintained at the base of the flap. It is important not to undermine the skin. Elevate the flap in the subfascial plane since the blood supply runs just above the fascia.
- (2) The fascia and deep fat are left intact at the base of the flap (level with the posterior introitus) with the skin and superficial fat cut only to a depth of 1 cm.
- (3) You can cut laterally at the base of the flap to free the fascia as long as you do not go centrally and disturb the blood supply.

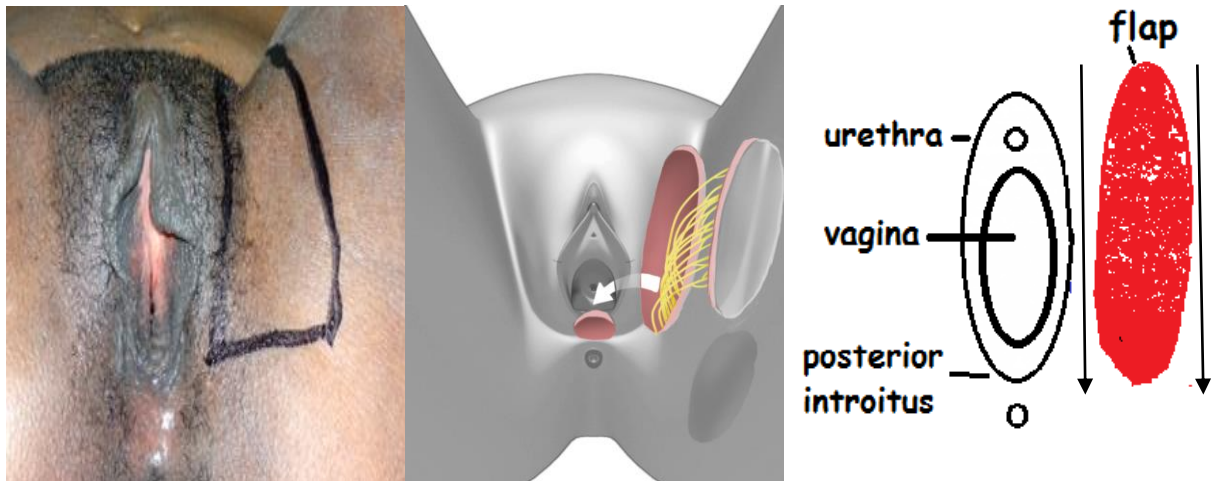


Fig. 8.1a1: Shows the flap area outline before the procedure.


Fig. 8.1a2: Shows how the flap will be swung (white arrow) into the vagina under the skin bridge of the labia.

Fig. 8.1a3: The incisions through the fat and fascia (arrows) come all the way down to the level of the posterior introitus without undermining the skin.

Dimensions: The size will vary according to the size of the defect.

- The *width* can vary depending on the size of the defect e.g. 3-6 cm.
- Adequate *length* is critical to pass through the tunnel and reach the other side. It is better to have the flap too long than too short. The typical *length* is 10-15 cm. One way of estimating the length of the graft is to measure from the base of the graft site (just medial to ischial tuberosity) to the most distal place in the vagina where the graft will have to reach. This can be done using a piece of gauze. Then add 1-2 cm to this estimate.

Diluted adrenaline can be injected along the line of the intended incision if cautery is not available.

	<p>It is better not to have too much flexion of the hip with the patient in the lithotomy position while marking out the flap area as otherwise the landmarks may be distorted and it is more difficult to extend the flap above the level of the adductor longus tendon.</p>
---	---

(1) **INCISION FOR THE FLAP:** Outline the area to be cut with a pen or dye.

- **Medial border** is just lateral to the labia majora at the labio-crural fold to avoid the hair-bearing skin. However, some hair is usually included.
- **Lateral border** will vary depending on the width taken.
- **Upper margin** should extend to 2-3 cm above the adductor longus tendon. A good rule would be to keep the flap wide until you reach the adductor longus tendon and then taper the incision to an oval near the apex.
- **Lower margin** (base) is usually in line with the posterior introitus. Do not cut below this to avoid disturbing the blood supply.

Cut the skin, fat and then continue down to include the deep fascia of the underlying muscle. To complete the incision (see Fig. 8.1a2), the lower (inferior) skin margin is cut but only to a depth of 1 cm into the fat. This is to preserve the blood supply entering the deep surface of the flap. In cases where there is an episiotomy, the lower skin margin may be left intact (see Fig. 8.2c + d).

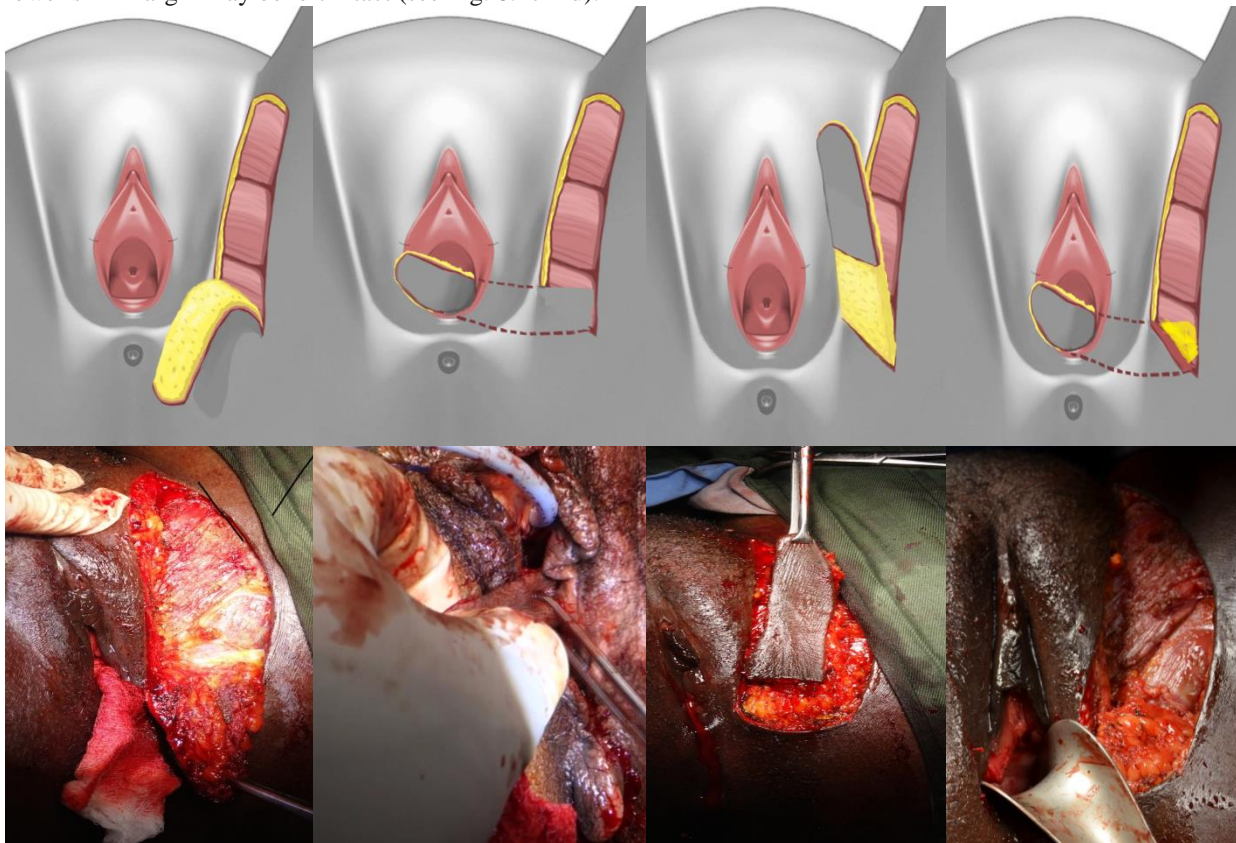


Fig. 8.1b: Shows the flap taken with the underlying fascia. You must see the underlying muscle exposed.

Fig. 8.1c: The flap is swung into the vagina. The point where it enters the vagina is marked on the skin with the Allis forceps.

Fig. 8.1d: Shows the flap with the lower skin excised.

Fig. 8.1e: The flap has been swung back into the vagina so that only the fat and pedicle are visible in the lower end of the donor site.

(2) **MOBILIZATION OF THE FLAP:** (Fig. 8.1b)

- Starting proximally, deepen the skin incision and cut the deep fascia so that you can see the underlying muscle. Cut down perpendicular on either side and avoid undermining the skin (see Fig. 8.1a3) to avoid

cutting the blood supply. Continue until the lower end is reached on both sides. Both the skin and the deep fascia are cut to the base of the flap on both sides.

- The skin at the base (inferior) of the flap is then undermined for several centimetres to improve mobilization and allow for donor site closure. Do this inferiorly and a bit at the sides as well.

Optional: To keep the skin and the fascia together, either apply a single absorbable stitch to the apex of the flap between the skin and the fascia or place an Allis forceps on the apex of both the subcutaneous tissue and the fascia.

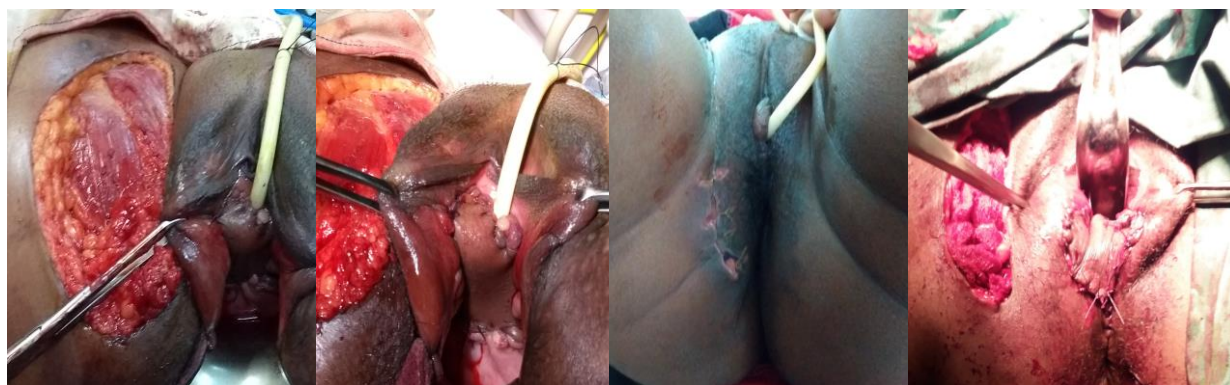

Fig. 8.1f: Shows the donor site with the muscle exposed in the upper 2/3rds while the pedicle (fat and fascia) is seen in the lower 1/3rd.

Fig 8.1g: Shows the flap covering a defect in the vagina over the urethra and distal bladder.

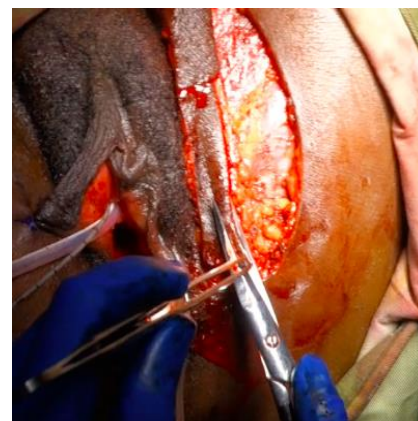
Fig. 8.1h: This is the same case as in Fig. 8.1f+g one week post-operatively showing a good cosmetic result.

Fig. 8.1i: In this case, the flap is used to cover a posterior defect in the vagina and perineum in a patient with a very stenosed vagina following the repair of a 4th degree perineal tear.

(3) TUNNEL FOR FLAP INTO VAGINA: (Fig. 8.1a2 and Fig. 8.1c) After mobilization, pull the flap into the vagina through a tunnel in the same way as the Martius flap. Make a tunnel subcutaneously under the labia majora and above the inferior pubic ramus initially with scissors or cautery. By staying close to the bone, you usually get less bleeding. Dissect the tunnel from both the vaginal and labial aspects. The size of the tunnel will vary with the size of the flap but a good rule is that the tunnel should allow the passage of two fingers. You may stretch the tunnel so there is no tension on the flap although it is better to sharply dissect the tunnel so that the flap goes through easily. There should be room for one finger to be inserted alongside the flap to allow for any swelling which will take place. There should be no tension either pulling the flap in or when suturing it in place.

Any excess skin is removed from either the vaginal or perineal side. With the flap pulled into the tunnel/ vagina, from the vaginal aspect mark on the skin where the flap exits the tunnel. Then pull the flap back into the groin and make a transverse incision at this mark. Then excise the skin superficially below this mark to remove the epidermis in the area that will be buried in the tunnel. This can be done using a knife or scissors as in Fig. 8.2a.

Fig. 8.2a: Shows the skin at the lower end of the flap being excised with scissors. The left hand is holding pickups/ dissecting forceps to steady the skin which is excised in strips longitudinally. Then any bleeders on the bare surface are cauterized.



! Top Tip! The flap should swing in easily. It should be more of a pushing motion from the outside rather than a pulling one from the inside to avoid injury to the flap. If the flap fails to come in easily, either (a) cut the fascia more on the lateral edge of the donor site or (b) undermine the skin more at the lower end.

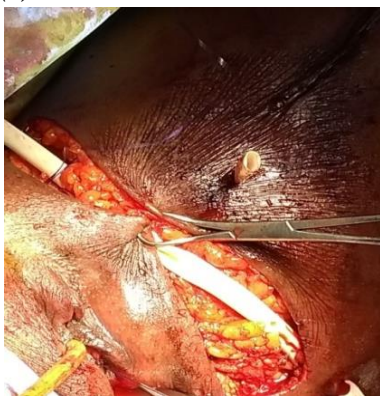! Tip! It is a good idea to inject adrenaline in the tunnel area to avoid bleeding which can be a problem in this vascular area.

Note: It is not usually necessary or a good idea to trim the fat of the flap as this could interfere with the blood supply. The only fat that could be trimmed would be the apical 2-3 cm as this would not interfere with the blood supply.

(4) **FIXATION OF THE FLAP IN VAGINA:** (Fig. 8.1g)

- Before the flap is pulled into the vagina, it is a good idea to place four separate sutures in the proximal and distal corners. These will be used to fix the flap.
- After being pulled through the tunnel, the flap must rotate sideways to reach the opposite side. By keeping the flap attached to its base, it can be rotated 90 degrees without compromising the blood supply.
- Fix the flap on the far side first. Pass the four sutures through the flap. Then fill in the gaps in between.
- A combination of continuous and interrupted sutures is used.

(5) **CLOSURE OF FLAP DONOR SITE:**



Because the defect is often large, taking the leg out of the stirrups and adducting the hip allows the skin edges to come together more easily. This makes closure much easier.

Overcoming discrepancy: The lateral edge of the wound is longer than the medial side. If you do not take this into consideration during closure, you will end up with too much skin (“dog’s ear”) on the lateral side. To overcome this problem, align the centre of each side of the wound by marking with a towel clamp (Fig. 8.2b). Then remove the towel clamp and place the first few deep sutures in the middle of the wound as previously marked. This is to align the middle of the lateral incision with the middle of the medial one. Then work from each end allowing the discrepancy to be distributed along the way and worked toward the middle.

Fig. 8.2b: Shows a towel clip being used to help align the closure. Note the presence of a drain.

The donor site is closed in three layers ie. fascia, deep dermis, subcuticular. Even in the thin patients, aim for this.

(a) *the fascial layer:* Close the deep fascia on the medial side to the superficial (Scarpa’s) fascia laterally. This places all the tension of the closure on the deep pelvic fascia which is very strong. At the lower end of the wound, it is not possible to access the deep fascia on the medial side, so suture the superficial fascia to the superficial fascia with interrupted sutures. Note: It is not possible to close the deep fascia to the deep fascia as the defect is too large.

(b) *Superficial layers:*

- a deep dermal layer: placing the sutures in the deep portion of the dermis will hold the tension and approximate the skin edges better. Aim to include some of the white layer of the dermis.
- a skin or subcuticular layer. However, if the closure seems tight (usually after taking a wide flap) or there is amononical dermatitis present, it may be wise to use interrupted external sutures with permanent 3-0 nylon or prolene, which can be removed after 2 weeks. This should give a stronger closure.

Drain: As there is a high risk of haematoma or seroma, a drain is inserted just above the muscle layer. It exits through the upper or lower end of the incision. It may be brought out either at one end of the wound or (preferably) through a separate stab incision. If standard drains are not available, a drain can be made from the sterile tubing of a urine bag. Another option is to use a straight plastic catheter as used for intermittent catheterization.

POST-OPERATIVE CARE:

Make sure to have the patient keep her legs in adduction to minimize tension on the closure during the healing period. Keep her on bed rest until Day 2 to avoid any pulling on the flap site. Ambulation is then allowed. She should not sit for 5 days to avoid any pressure on the blood supply which is close to the ischial tuberosity.

- *If the flap necroses or breaks down:* This may be due to (a) Poor blood supply (b) Tension (c) Infection. It can be partial or total. The treatment is to debride any dead tissue and irrigate the vagina with saline twice daily as there is often a profuse discharge.
- *If the flap retracts:* If you notice post-operatively that flaps are retracting back to the vaginal side-wall on the side from which they were taken, this indicates some tension. Make the flaps longer so they reach further and do not have to be pulled too much i.e. the tip should go 2-3 cm above the adductor longus tendon. When you harvest a flap with the fascia it should survive all the way to the tip.
- If utilizing a previous flap in a repeat operation, as long as you keep about 50% of it attached, the flap can be mobilized and brought back in over the repair.

If a flap is performed in the presence of an episiotomy:




Fig. 8.2c: Shows the flap in relation to the episiotomy.

There are two important points in this situation:

- (i) The episiotomy should form the lower medial border of the flap.
- (ii) Do not make the transverse incision across the lower end of the flap i.e. keep the lower end intact. Swing the flap directly into the vagina without tunneling it. Cosmetically this is not as neat compared to the tunneled flap but it is more practical in this situation.

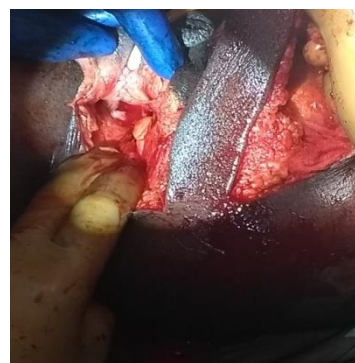
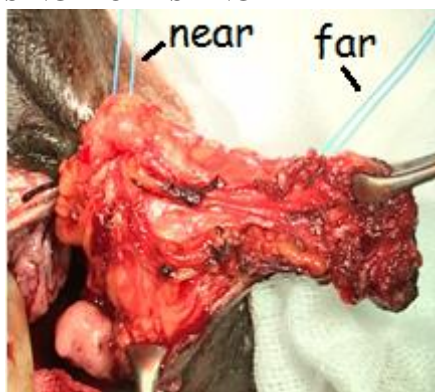
Fig. 8.2d: Shows the flap mobilized with the lower end intact and about to be swung into the vagina through the gap created by the episiotomy.

SINGAPORE SLING



This is utilizing the fascia of the flap as a sling for stress incontinence. The Singapore flap is taken in the usual way with the skin, fat and fascia. Two sutures are applied to the fascia (Fig. 8.2e) and these are then fixed to the rectus sheath suprapubically on one or both sides.

- *Far suture:* This is placed near the apex of the flap which will reach to the opposite side.
- *Near suture:* A second (optional) suture is placed on the near side.

Fig. 8.2e: Shows two Prolene sutures inserted through the fascia of the flap. The far suture is on the right side of the photograph.

The far suture is the most important for adjusting the tension. In fact, the sling probably works just as well with this suture alone. The bladder may be filled with 100 ml of fluid and the suture is tied tight enough to stop any leakage. Both of these sutures are then pulled up with a Stamey needle through the rectus sheath on either side of the midline in the same way as for a rectus sling. They are not tied yet. The skin of the flap is first sutured to the vagina before the sling sutures are tied.

Note: While it is possible to take a skin flap (previously known as an Island flap) without including the deep fascia, it is better to take this for two reasons: (1) It is easier to get the graft to swing into the vagina. (2) Necrosis of the graft is less likely as the axial blood supply is better preserved for the entire length of the flap.

LABIAL FLAP

This flap is used to cover the anterior vagina but is only suitable for small defects (up to 2 cm). Two incisions are required (Fig. 8.2f):

- A horizontal incision is made either as an extension of one of the lateral incisions (made during dissection of the fistula) or of any episiotomy.
- A vertical incision is made in the groove just lateral to the labia majora (labia-crural fold) from the level of the urethral opening and continued down to meet the horizontal incision.

The grey area (the antero-lateral skin of the vagina and labia) shown between these incisions is then undermined and mobilized so that it can be swung medially to cover the anterior vagina. This results in:

- The pink vaginal skin (b in Fig. 8.2f) being rotated to end at point b'. This is sutured in place first.
- The pigmented labial skin (a in Fig. 8.2f) being rotated medially to end up at point a' on the left side of the vagina.

The incisions are closed usually without any difficulty or need for any further undermining at this stage.

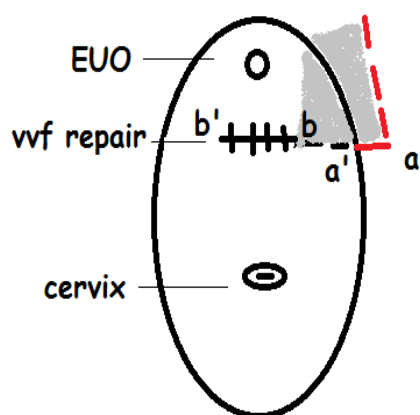


Fig. 8.2f: Labial Flap: This shows the two incisions with the grey area which will be mobilized.

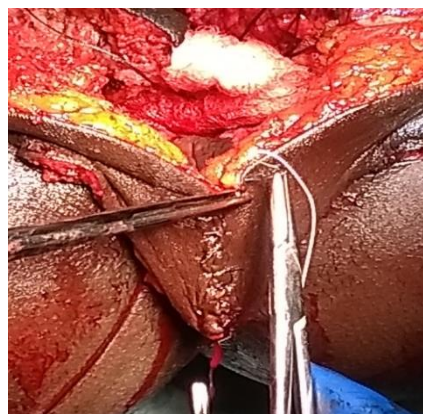

Fig. 8.2g: Shows a vagina being re-formed with bilateral Singapore flaps which are being joined in the midline. The initial suturing is performed outside the vagina as in this photograph.

(8.2) MANAGING VAGINAL STENOSIS

During or following a VVF repair, the vagina may be so scarred that it is very short and narrow or almost closed. Usually, length is the main problem limiting coitus.

Open the vagina: Irrespective of which method is used, the vagina has to be opened up first. Make a transverse incision (3-4 cm wide) into the scar at the vault/proximal vagina, after identifying the urethra/bladder with a metal catheter in place, and the rectum with a dilator or your finger in the rectum. Dissect up high and remove as much scar at the vault as possible. Identify any cervix.

To keep the vagina open: there are several options:

- (1) **Bilateral Singapore flaps:** Two large Singapore flaps can be sutured together to create a complete neovagina. The flaps are sutured to each other along an anterior and a posterior suture line while still outside (Fig. 8.2g). Once the neovagina has been mostly created externally, then it is turned in on itself (inverted) and secured to the apex of the vagina.
- (2) **Bowel:** Use large bowel (sigmoid) as a neo-vagina. The danger of any surgery involving the lower colon is a 10-20% risk of a leak from the anastomosis.
- (3) **Kees Neovagina:** Dr Kees has described a novel technique where the vagina is enlarged by opening the pelvic peritoneum. If this is kept open, the peritoneal lining forming the upper neovagina is transformed into normal vaginal skin within three months. The following is based on his description of the operation.

KEES NEOVAGINA METHOD

(A) **Incision:** Bilateral episiotomies; transverse incision in 'vaginal vault'. If the cervix is present, this will be a posterior colpotomy. Then by sharp and blunt dissection, tunnel up to the parietal peritoneum. The bladder

or rectum may be injured during this step. Widen the colpotomy out to the ischial spines in order to prevent stricture of the neovagina. *Complications:* If the bladder or the rectum are traumatized, they are repaired immediately and then covered by the thick posterior colpotomy peritoneum.

- (B) **To form the lower part of the neovagina:** Join the vagina to the peritoneum: (Interrupted Vicryl sutures are preferably used for all suturing.)
- *Anterior:* If the cervix is present, suture the anterior peritoneum from the cervix onto what is left of the anterior vaginal wall. (With repositioning of the cervix into the neovagina, patients can become pregnant.)
 - *Posterior:* The posterior peritoneum is sutured onto the posterior vaginal wall.
 - *Lateral:* Suture peritoneum into the deepest point of bilateral episiotomy/ widened colpotomy to prevent re-stenosis and for a broad neovagina.
- (C) **To form the vault of the neovagina:** Either with interrupted sutures or a separate continuous suture started laterally on each side, work from laterally to apically:
- *Laterally:* Identify the uterus and suture from:
 - (a) the posterolateral uterine peritoneum (serosa) 1-2 cm above the lower part of the uterus onto
 - (b) the posterolateral pelvis wall peritoneum about 2-3 cm from the cervix. If the uterosacral ligament is clearly identifiable, it can be stitched onto this although often it is not so clear.
 This closes the space between the uterus (up to) and the lateral pelvic wall. The ureter should not be at risk here since it is at a superior level within the parametrium above the ischial spine.
 - *Apically:* Suture the posterior uterine peritoneum (serosa) at 1-2 cm proximally from isthmus (inferior part of the uterus just above where it joins the cervix) onto anterior rectum serosa at 12-14 cm from anus.

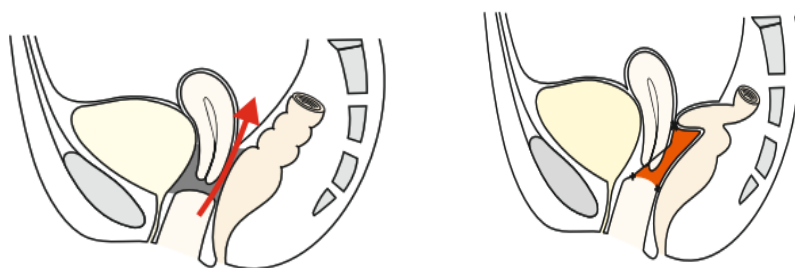



Fig. 8.3: Shows where the colpotomy is made and the plane of dissection. Fig. 8.4: Shows the completed neovagina. Diagrams courtesy of Kees Waaldijk from obstetric trauma surgery art and science: Kees neovagina reconstruction (2017).

Tip! It is a good idea to use this method at the time of (mid and high) RVF repair as there is no danger of creating a new fistula.

Post-operatively: The vagina is packed deeply with a Vaseline pack for 4-5 days. Leave in Foley catheter for 2 days. The vagina is re-packed every 4-5 days up to day 25 to keep it open during the healing process. From then, vaginal dilators can be used to keep the vagina open until intercourse starts 5-6 weeks after surgery. A dilator is passed twice a day and left in for ten minutes. Compliance is very important especially during the initial 5 weeks.

In congenital Mayer-Rokitansky-Küster-Hauser (MRKH) syndrome (where there is usually a very short vagina and absent cervix/ uterus), a similar procedure can be performed. In this case, to form the apex, the posterior bladder peritoneum is used instead of the uterine peritoneum. No episiotomies are required. It works well in this condition because there is no scarring.

	Vaginal stenosis is a difficult problem to solve and none of the surgeries is easy. It is much easier to deal with it at the initial fistula repair. If managed later, there is a high risk of opening the bladder or the rectum.
---	---

Acquired stenosis (non-fistula): In some cases after childbirth or other trauma, the vagina has become hidden but can be opened up easily once you find it. These patients are usually menstruating normally. Look carefully before making any incision. It often helps to do a rectal examination and look for any air, blood or mucus coming out from the vagina. Once found, it is easy to pass a probe into the area and dilate it up. Remember that the vagina is closer to the urethral opening than to the rectum. In some patients, the stenosis recurs and it may be easier to place a Singapore flap laterally after incising the vagina.

(8.3) TO IMPROVE HEALING OF THE FISTULA: MARTIUS FLAP

This is a fibro-fatty flap (5-6 cm long and 2-3 cm wide) which is normally taken from the labia majora on one side. The flap is performed after the fistula repair and before closing the vagina. The purpose of a Martius flap is:

- To plug minor defects in the suture line and bring fresh blood supply to the area.
- To keep the healing bladder and vaginal walls apart.
- To fill any dead space lateral to the repair in the hope of stopping lateral scarring out towards the bones thereby reducing the risk of stress incontinence.

This procedure was commonly performed for most fistula repairs in the past i.e. those that were within reach of the graft. However, it is now only performed where the tissues are poor or there has been a failed repair before. It is especially used for fistulas involving the urethra (urethro-vaginal) and in these cases may be combined with a pubo-coccygeal sling.

Preparation for the flap

- Check that there are no bleeding areas in the vagina before performing the flap.
- Insert 2-3 stay sutures (mainly on the side opposite the graft) that will be used to hold the flap in place later (Fig 8.6). These are inserted but the ends are left long on a clip. These are inserted into the fascia between the bladder and cervix/ vagina. Hold the fascia that you want with an Allis forceps as you insert the stitch.

CAUTION! Make sure you identify the cervix before you pull the Martius flap through as the flap may cover over it later. It is a good idea to put a stay suture just above the cervix.

(Step 1) Incision: The operating table can be made level and the Auvard speculum is removed to avoid stretching the area of the flap site.

- Incise the medial aspect of the labia majora for 6 cm between two Allis forceps from above the level of the clitoris to mid-vagina (dotted line in Fig. 8.4). A longer graft can be made with an 8–10 cm long vertical incision from the level of the mons pubis to the level of the fourchette.
- The incision should be made in the bulk of the labia majora. The initial incision is deepened so that you go through Scarpa's fascia. Dissect between Scarpa's fascia and the fat pad to create a flap. Once the incision is made, move the Allis forceps to either side of the incision (Fig. 8.5 and 8.6).

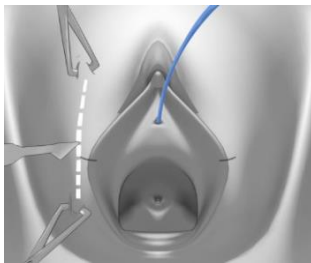


Fig. 8.4: Shows the line of incision for the Martius flap.

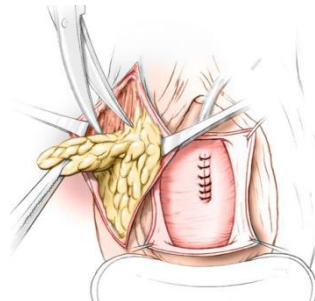


Fig. 8.5: Shows the flap being dissected out.

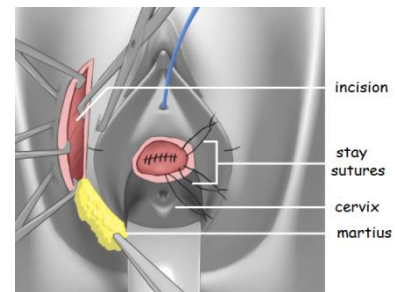


Fig. 8.6: Shows the stay sutures inserted to fix the Martius flap in the fascia on the opposite side.

(Step 2) Dissecting out the flap: The aim is to obtain a 2 cm wide fat flap. With scissors, separate the underlying fat from the skin taking care not to button-hole the skin. Place your finger behind the skin so that you can feel how close you are to the skin. Avoid being too close to the skin. The fibro-fatty tissue of the labia is dissected free from the underlying adductor fascia.

- It is important not to divide the graft until it has been determined that the length that has been developed is adequate. Measure using a piece of drain or gauze to see that it will reach from the upper graft to the vagina.
- The upper part of the flap is freed by cutting between two artery forceps and tying. Then hold the upper part of the flap with forceps (as shown in Fig. 8.6) to make the dissection easier. Dissect around the flap so that a pedicle is formed at the lower end. Alternatively, the pedicle can be formed at the upper end as in Fig. 8.7 b+c.
- Most bleeding occurs on the medial side as you dissect. Avoid cutting the lower medial part, as this will cause unnecessary bleeding. This part will be pulled through into the vagina anyway so dissection is unnecessary and contains the blood supply to the flap that you want to remain intact.

- Before pulling the flap through into the vagina, check that all bleeding is stopped from the flap donor site and the graft itself. Cautery can be used for haemostasis.

CAUTION! Good mobilization is important to prevent excessive tension and subsequent necrosis of the flap. Make sure the base of the flap is wide so that it retains a good blood supply (from the pudendal artery branches).

(Step 3) Pulling the flap through into the vagina: The flap is brought into the vagina via a tunnel under the labial and vaginal skin:

- Reinsert the Auvard speculum into the vagina.
- Using scissors or a curved artery forceps, make a tunnel from the donor site to the vagina. Keep the scissors closely against the bony surface of the inferior pubic ramus. However, stay lateral enough to avoid the bladder/ urethra repair.
- The tunnel is enlarged by opening and closing the scissors in several directions. The tunnel should be wide enough to eventually admit two fingers. Too narrow an opening may strangulate the flap.
- While the scissors are still open, pass an artery forceps from the vagina along the scissors and pull the flap through (Fig. 8.7a).

The flap is then fixed to the sutures previously inserted (Fig. 8.6). Use a free needle to pass both ends of the suture through the flap from posterior to anterior and tie the two ends together.

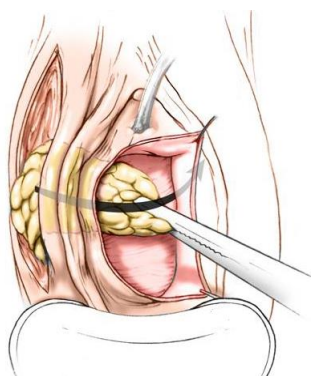


Fig. 8.7a: The flap is being pulled into the vagina to cover the repaired bladder. (Courtesy of Grace Chen)

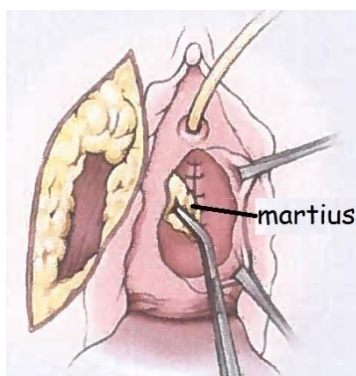


Fig. 8.7b: In this case, the flap with the pedicle is based superiorly/ anteriorly which gives a better approach for urethral fistulas.

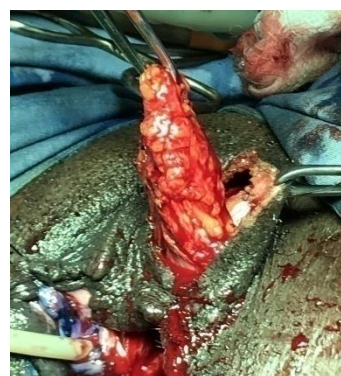

Fig. 8.7c: With adequate dissection, a large flap can be obtained in most cases.

(Step 4) Closure of the flap donor site: This is usually done after the vagina has been closed. Do a continuous suture to close the deep layer. Start at the top (leaving the short end on a clip) and continue down. Then going more superficially, go back up to the top and tie. The skin can be closed with simple interrupted stitches or a subcuticular stitch.

(8.4) TO IMPROVE HEALING OF THE FISTULA: GRACILIS FLAP


Because muscle is so vascular, it tends to become adherent to any surrounding tissues and supply all the factors necessary for good wound healing. It is this property that makes it such a good intermediate layer.

Indications for Gracilis flap

RVF: (a) RVF after radiotherapy. In post-radiation fistulas, wait one year before attempting repair. However, all fistulas post-radiation have a very high failure rate so it may be simpler to leave the patient with a colostomy rather than attempt repair. If you are repairing, then a Gracilis flap greatly increases the chance of healing. (b) On several occasions, I have used it successfully for obstetric RVFs which were very scarred due to multiple previous repairs, and I felt that this was the last chance for healing. In a review of the use of a Gracilis flap in RVFs (all etiologies including obstetrical), it is suggested that it be considered as one of the first-line treatment options for recurrent RVF.

Reference: *Gracilis muscle interposition for recto-vaginal and ano-vagina fistula repair: A systematic literature review: A. Hotouras et al; Colorectal disease Volume 17, Issue 2, 1 February 2015, Pages 104-110.*

VVF: (i) Post-radiotherapy causes. (ii) It can be used in any difficult (scarred) or recurrent cases of obstetric VVFs or to support a neo-urethra especially if you think the chances of healing are small. (iii) If during a VVF repair, there are repeated positive dye tests, then consider a Gracilis flap.

	Before performing the flap, there must be sutures placed to fix the flap. Either (a) During the fistula repair, make sure each angle suture is left long with both ends on an artery forceps. (b) If these have already been cut, place several stay stitches on both sides near the angles and in the midline. It is much more difficult to place sutures to fix the flap after harvesting the flap, as the position of the patient will often have changed.
---	---

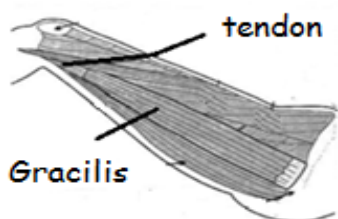


Fig. 8.8: The Gracilis muscle is long and thin. The Gracilis tendon is distinctively long and inserted on the medial tibial condyle.

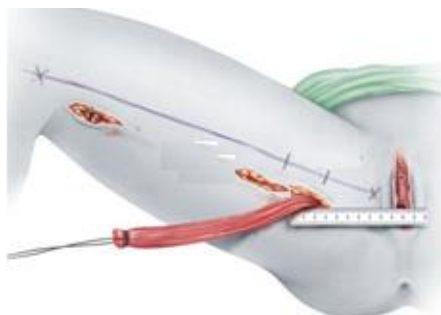


Fig. 8.9: Shows the line of incisions. In this case, traction with your fingers around the proximal muscle will help identify the more distal tendon before it is cut.

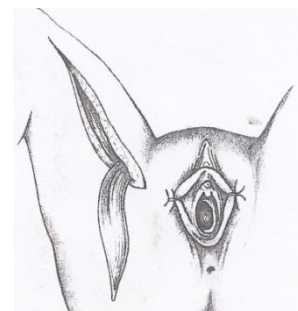


Fig. 8.10a: Alternatively, one long incision can be made. This is a simpler option but more morbid.

ANATOMY/ BLOOD SUPPLY

- The Gracilis muscle lies along the line between the pubic tubercle and the medial tibial condyle. It lies just posterior to the adductor longus muscle. An incision is made two finger-breadths posterior and parallel to the very palpable adductor longus tendon.
 - First mark out the line between the pubic tubercle and the medial tibial condyle which indicates the adductor longus muscle.
 - Then mark out a line made two finger-breadths posterior and parallel to this line (Fig. 8.9) which will be the line of the incision over the Gracilis muscle.



While the muscle can be harvested in the lithotomy position, you should reduce the flexion of the hip so the thigh is lower. This makes it easier to mark the muscle more accurately. Otherwise, you may end up too posteriorly.

- The main blood supply of the Gracilis enters the proximal third of the muscle from underneath the (antero-medial) adductor longus and then runs on its posterior aspect. This pedicle is about 8 to 10 cm from the pubic tubercle. The vessel is quite small although when clearly identified it can be seen pulsating. Bright yellow fat should alert you to the proximity of the vessels as you mobilize along the antero-medial border of the muscle. The obturator nerve to the muscle is also nearby so if this is stimulated by cautery (i.e. muscle contracts), this should also alert you to the proximity of the pedicle. Either:
 - (a) You can mobilize the muscle proximally until you identify the vessel. This has the advantage of allowing more mobilization of the muscle proximally. The fatty tissue is carefully teased apart by spreading with an artery forceps or scissors. If you do not find the vessels and you are already within 6-8 cm of the pubis, you can stop as you do not need more mobilization and the risk of injuring the vessels is high.
 - (b) You may avoid mobilizing the muscle (especially antero-medially) in the proximal 10 cm. This is safer if you are not confident in identifying the vessel.

(1) INCISIONS

Single-incision technique: This is much simpler to do but is not as good cosmetically. Make an incision in the lower two-thirds of the inner thigh starting 8 cm distal to the pubic tubercle (Fig. 8.10). The muscle is mobilized from distal to proximal after the tendon end is divided in the lower thigh. If you do not go sufficiently

distally, you may end up with a flap that is too short. However, there is no point mobilizing beyond where the muscle becomes a tendon. With the tendon transected, the muscle is freed up by blunt dissection.

Two-incision technique (see Fig. 8.9, 8.10b+c)

- *First (proximal) incision:* Incise 8 cm distal to the pubic bone for about 6 cm. This exposes the muscle. Mobilize the muscle all around by sharp and blunt dissection. Confirm that it is the Gracilis by the two tendon test:
 - Pulling up the muscle (Fig. 8.10b) and checking that the tendon of the adductor longus does not tighten.
 - Feel distally near the knee to see if the (distal) Gracilis tendon tightens. If it does not, you may have the adductor longus or another muscle.

Second (distal) incision: This is about 4 cm proximal to the knee. By pulling on the muscle proximally (Fig. 8.10b), feel distally for the tendon tightening. From the first incision, pass a long clamp on top of the muscle and make a small incision (about 4 cm) over the tendon. Find the tendon and place a drain around it. Free the tendon bluntly.

- From the distal part of the first incision, the muscle is freed up all around distally by a combination of blunt and sharp dissection. This requires the use of 1-2 retractors to lift the skin. Then look inside the incisions (headlight useful here) and cut any attachments. There are a few small pedicles which come from the adductor longus so look for these antero-medially. While a lot of mobilization can be performed bluntly, it is important not to rip or tear the tissues to avoid bleeding.
- Through the second incision, free the muscle proximally as much as you can. The muscle has to be completely free before you cut the tendon and pull the muscle through from the second to the first incision.
- By keeping some of the tendon on the lower end of the muscle, it is easier for the stitches to hold in tendon compared to muscle.

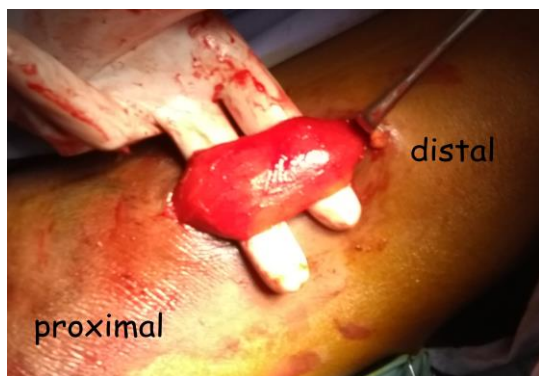


Fig. 8.10b: Shows the Gracilis muscle being pulled up through a proximal incision.

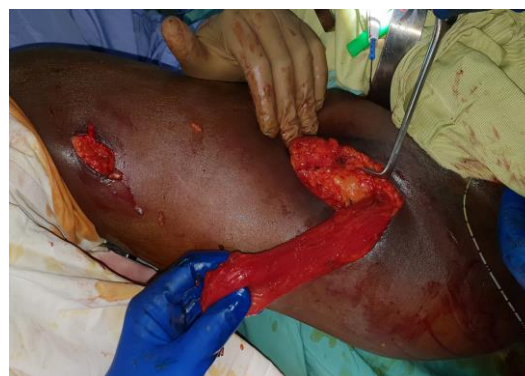

Fig. 8.10c: Shows the two incisions in the right thigh made to harvest the muscle flap.

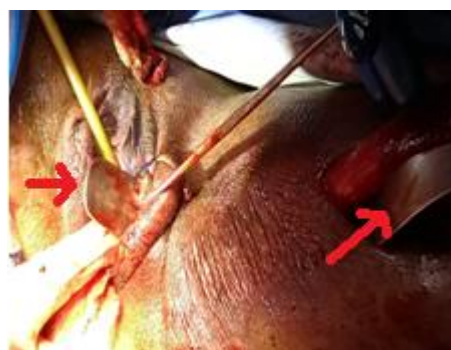

Fig. 8.11a: Shows a single Deaver retractor (arrows x 2) being used to form the tunnel.

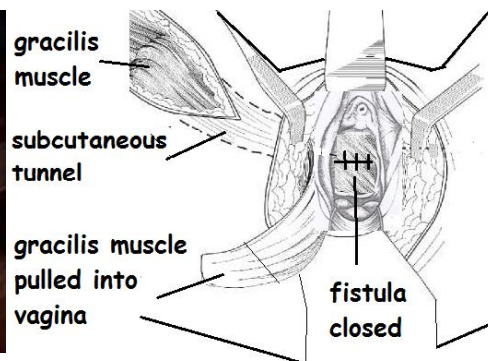
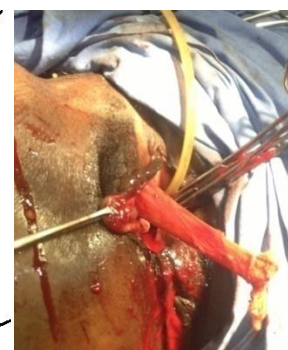

Fig. 8.11b: Shows the muscle being pulled through a subcutaneous tunnel and ready to be fixed into the vagina.



(2) TUNNEL FOR MUSCLE INTO THE VAGINA

- Make a subcutaneous tunnel from the medial end of the incision in the thigh to the vagina. You can start at either end and meet in the middle. Initially this is made by inserting a large clamp or a narrow Deaver retractor but eventually you should be able to get two fingers into the tunnel so there is no tension on the flap. You often have to cut bands of fascia with cautery to enlarge the tunnel.
- The muscle is pulled through this tunnel into the vagina (Fig. 8.11b). It should pass easily. If you find there is tension on the flap when it is in the vagina, the options are:
 - Mobilize the anterior border of the muscle proximally until you see the vascular pedicle. The (proximal) skin incision should be down to this level. Also mobilize the posterior border of the muscle.
 - Adduct the leg by removing it from the stirrups.

(3) FIXATION OF MUSCLE IN THE VAGINA

- Before pulling the muscle into the vagina, it is a good idea to place four stay sutures in the vagina i.e. in the four corners. These are usually placed in tissue between the bladder and the vagina.
- Fix the part of the graft closer to the thigh first (place two sutures first without tying and then tie both).
- Then fix the free end of the muscle to the opposite side of the vagina.
- If there is excess muscle, it can be cut off.

(4) CLOSURE OF INCISIONS: The thigh incision is closed:

- (a) A deep layer of deep fascia to deep fascia.
- (b) Deep dermis: this catches some of the white layer and holds the sutures (fat does not). It approximates the skin.
- (c) Skin layer.


- As it is a pretty dry dissection and you close all the layers, you could probably get away without a drain.
- Put a pressure bandage around the thigh, which can be removed the following day. The dressing should be changed on Day 1 if soaked. Otherwise, it can be kept on until Day 2.


Postoperative Care: The patient may have bed rest on Day 1 and be mobilized from Day 2.

Combined Gracilis and Singapore flap

- If a Gracilis and a Singapore flap are performed during the same operation, they should be done on the same side. This is because only one tunnel is required although it may have to be enlarged for the Singapore flap.
- It is a good idea to harvest the Singapore flap first as this is more difficult to do if you have already taken the Gracilis. It is important to leave at least a 3 cm bridge of skin between the Singapore donor site and the (proximal) Gracilis incision.
- It is time-consuming to do both flaps. If your main concern is the healing of the fistula, then do a Gracilis flap. If you do not get skin cover over the Gracilis flap, as long as you have good apposition of the muscle over the fistula repair site, this should not affect the fistula repair. Then cover the muscle with Vaseline gauze and pack the vagina.

Free skin graft: Another option would be to cover the exposed muscle with either a split (from the thigh) or full-thickness skin graft (from the lower abdomen). A split-thickness will take easier but has a little more risk of contracture. For full-thickness graft, the key is to get it thin enough so that all the fat is removed. Suture the graft to the muscle and then pack the vagina for five days. When you remove the pack, do it carefully under vision so as not to disrupt the graft.

 **Tip!** One option in cases where the fistula repair has already taken a long time or there has been significant blood loss is to stage the procedures over two days. The vagina can be packed at the end of the fistula repair. Blood can be transfused overnight if necessary. The patient is then returned to the operating room early the next day to place any flaps.

 **Tip!** If you have a lateral fistula which you need to cover with a Gracilis flap, it is a good idea to take it from the side opposite to the fistula. This is because it is easier to place the tendon end of the muscle over the fistula as it can be fitted in easily. If you take it from the same side as the fistula, it is difficult to get it into the corner.

 **Summary
of use of flaps in
fistula surgery**

- *Poor vagina + fistula* = Singapore flap. A Singapore flap should help with healing of the fistula as well as providing skin cover.
- *Good vagina + fistula with poor tissues* = Gracilis, Martius or Pubococcygeus flap. If you place a good size patch of muscle over any fistula repair, it will usually heal.
- *Poor vagina + poor fistula* = Do both Gracilis and Singapore flaps.

CHAPTER 9

URETERIC FISTULAS

Section 9.1: Re-implantation of the ureter abdominally

Section 9.2: Double and ectopic ureters and vaginal re-implantation of ureter

Ureteric fistulas occur following surgery with the exception of congenital ectopic ureters.

(a) *After obstetric procedures:* Caesarean section, repair of ruptured uterus and Caesarean hysterectomy.

(b) *After gynaecological procedures:* hysterectomy, VVF repair.

The left ureter is more commonly affected than the right although the exact reason for this is uncertain. The frequency of ureteric injuries seems to be increasing because more Caesarean sections are being done.

Reference: Diagnosis and management of 365 ureteric injuries following obstetric and gynecologic surgery in resource-limited settings. Raassen T, Ngongo CJ, Mahendeka MM: Int Urogynecol J; October 2017.

DIAGNOSIS (See also chapter 1A)

(a) *History:* Ureteric fistulas are often confused with VVFs as the presenting symptom is urinary leakage. The patient will both leak urine vaginally and pass urine per urethra normally (from the unaffected side) i.e. the patient is wet all the time but also voids. Also, ask about any previous surgery.

(b) *Examination:* A negative dye test with clear urine in the vagina makes this diagnosis likely. Remember to have the patient drink plenty before you examine her. Initially, it may appear like a vaginal discharge.

(c) *Investigation:* The diagnosis is made more likely by ultrasound or intravenous urogram which usually reveal varying degrees of hydronephrosis and hydroureter.

- Ultrasound will be sufficient in most (approximately 95%) cases to localise the affected side i.e. hydronephrosis. Hydronephrosis is more likely to be absent when there is still flow of urine into the bladder from the affected side as well as leaking into the vagina. Getting the patient to drink plenty before the ultrasound examination will often make the hydronephrosis more obvious.



If ultrasound shows no hydronephrosis in a suspected case of ureteric fistula, look again for a bladder fistula. Place a swab in the vagina and re-examine after several hours. Repeat the dye test in the operating room before any surgery and if necessary give frusemide intravenously.

- Intravenous urogram will typically show a dilated ureter and extravasation of dye. Occasionally it will show a silent kidney or persistent column of contrast.
- A double dye test: The patient takes oral phenazopyridine for 24 hours which stains the urine orange. Blue dye is injected via a catheter into the bladder and the patient wears a tampon. Orange staining on the tampon suggests a ureteric fistula.

Timing of surgery: In general surgery can be performed once the diagnosis is made. However, between 2-6 weeks post-injury, the tissues will be more friable so surgery is best delayed (especially if you are not so experienced) to avoid a difficult operation with tearing of the ureter etc. However, if there is hydronephrosis together with fever or renal failure it is better to operate early.

If she has fever: Give antibiotics and operate within 24-48 hours. Another option in this situation would be to do a nephrostomy to gain time before any surgery.

(9.1) RE-IMPLANTATION OF URETER ABDOMINALLY

It is not necessary to find the actual fistula site. The ureter is divided above the site of injury (which is usually in the lower end of the ureter near the level of the uterine vessels) and is re-implanted into the bladder.

Exposure: It is a good idea to have the patient's legs in low-lithotomy position with minimal flexion of the hips so that:

- You can access vaginally and abdominally without re-positioning.
- It allows a second assistant to participate more.

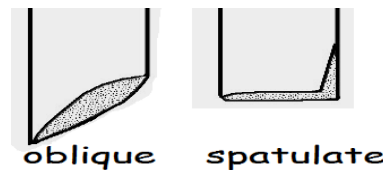
Once the patient is in position, you can prep the abdomen and vagina, and place a Foley catheter aseptically since the catheter will be drawn into the wound during the operation. If you are using the supine position, at least, keep the Foley catheter sterile and place it above the drapes so that you can access it during the operation. *Optional step:* Consider placing a ureteric catheter into the bladder (but not into the ureter) through the urethral meatus at the start of the operation so that it will be ready to be used once the bladder is opened. It can be fixed to the drapes with an artery forceps to prevent it being expelled. If difficulty inserting the ureteric catheter, push the balloon of the Foley well into the bladder or insert it before you insert the Foley.

Confirming the diagnosis: Expose both ureters. The side of the fistula will often have hydroureter and significant scarring. If still in doubt, open the bladder and:

- See if urine is coming from each ureteric orifice. The absence of urine from the injured side is a reliable way of confirming the diagnosis.
- To further confirm the diagnosis (especially if urine is seen coming from both ureteric orifices), catheterise both ureters. Usually, the ureteric catheter is not able to pass at the site of the injury which is most often 2-3 cm from the ureteric orifice. However, it is possible for the ureteric catheter to pass out via the fistula into the vagina. On one occasion, after repairing a VVF abdominally where both ureters were catheterized intra-operatively, the diagnosis of a left-sided ureteric fistula was only made when the upper part of a ureteric catheter was seen in the vagina when cleaning the patient at the end of the surgery. The left ureter was re-implanted immediately.
- Check for double ureters which are not uncommon. Think of this especially when a ureter has been re-implanted and the patient is still wet post-operatively.

! Tip! The urine from the normal side can make it difficult to see the other side. If you press the normal ureter from inside the bladder just above the meatus with a small piece of gauze (peanut) or the end of pickup/ dissecting forceps, this will stop the urine coming from the normal side. You can then observe the other side.

! Tip! The rules for re-implanting the ureter are:
(a) Avoid tension. (b) Minimize the risk of later stenosis i.e. when cutting the ureter, always cut it obliquely and spatulate it. If the ureter is of normal size, spatulate it for 2 cm.



(METHOD 1) INTRA-PERITONEAL (AND INTRA-VESICAL) APPROACH

This is described first as it is the route most familiar to most surgeons.

Incision: Make a midline sub-umbilical incision (may need to extend above umbilicus). It is important to extend the skin and sheath incision down to the pubic symphysis. Sometimes the bladder is high and attached to the abdominal wall, so feel for the Foley balloon if you suspect this. A Pfannenstiel incision is also an option although you may need to divide the recti muscles if access is inadequate.

! Tip! Often the uterus is high and stuck to the abdominal wall. It is easier to dissect down on either side of the uterus initially to get to the bladder. You may have to dissect the uterus off the abdominal wall.

Step 1: Mobilizing the ureter: this is performed in the retroperitoneal space.

- The ureter is located between the ovary (which can be held with a Babcock) and the sigmoid colon. On the right, it is also medial to the caecum.
- In difficult cases, where localisation is challenging, it is worth remembering that it crosses the pelvic brim at the sacro-iliac joint and runs over the bifurcation of the common iliac artery.
- In some cases, it may be very difficult to find the ureter due to inflammation caused by the urine leak. The ureter is covered by a thick false capsule. It is useful to remember that the ureter runs lateral to the common iliac artery before it crosses the bifurcation. Find the ureter higher up where it is healthy and follow it down.
- After cutting the peritoneum over the ureter, hold the two edges of the peritoneum with Allis forceps for exposure.
- When the ureter is covered by a false capsule, you have to cut onto the ureter until you get to the true ureter which is soft. If you make an accidental opening in the ureter, this is easy to repair and heals well if the ureter is kept decompressed. There is no need to excise the false capsule.
- The rule for dissection is to stay close to the ureter. Dissecting forceps stretch the tissues with your left hand while you cut close to the ureter with your right hand. Once you are in the correct plane close to the ureter, blunt dissection with your finger is safe.
- When dissecting the ureter, try to leave adventitia on it as the adventitia contains some of the ureteric blood supply. To preserve the blood supply to the ureter, do not cut too close to the ureter but leave a “mesentery” on it. This is because the blood supply to the ureter is mainly from surrounding structures. i.e. do not strip it bare/ white



The ovarian vein runs parallel to the ureter above the infundibulo-pelvic ligament for some distance and it is easy to mistake it for the ureter until you see it running into the infundibulo-pelvic ligament. It has been re-implanted into the bladder on more than one occasion!

The aim is to ligate the ureter as distally as possible to give a good length and avoid tension. Every millimeter counts. Cut the ureter just before it goes under the uterine artery (uterine artery tunnel). Two methods are used:

- (i) A right-angled forceps/ clamp is useful for dissecting and clamping the lower ureter. Then tie off the lower end.
- (ii) You can pass a tie around the lower ureter and then push it down with pickups. Then tie the suture and then cut the ureter.

Occasionally you may want to free the ureter as far down as possible by dividing the uterine artery.

Tip! You want to cut the ureter above the area of damage. A rule of thumb is to dissect until it is no longer fun to do so!! Also, the ureter should look viable and not ischaemic.

- Once the distal end is free, the ureter is mobilized upwards about half way up to the kidney. You have to be careful to avoid bleeding as you mobilize. The higher you go, the greater this risk is. Avoid pulling on the ovarian vein high up as this can tear it off the inferior vena cava (right) or renal vein (left) which can result in severe bleeding.

Step 2: Mobilizing the bladder

1. Open the utero-vesical fold before opening the bladder.
2. A lot of bladder mobility can be obtained by bluntly opening the retropubic space.
3. Mobilize the bladder especially the side opposite to where you are going to re-implant so that the bladder can come across the midline and then comes up to the ureter easily. If using sharp dissection, beware of cutting the normal ureter.
4. When opening the bladder, open it transversely (in contrast to VVF repair where it is a longitudinal incision) along its widest point (see Fig. 9.1a). Then if you close it longitudinally (Fig. 9.1b), this will gain a lot of distance by bringing the bladder up towards the ureter.
5. Check if the ureter comes to the bladder without tension. If not, mobilize the ureter and bladder more.

Tip! If the bladder is difficult to mobilize, sharp dissection close to the pubic bone will free it.

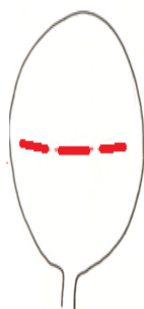

Fig. 9.1a: Bladder opened transversely.

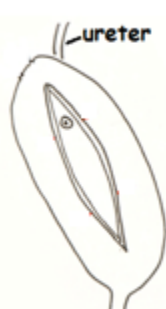

Fig. 9.1b: Shows the bladder about to be closed longitudinally.

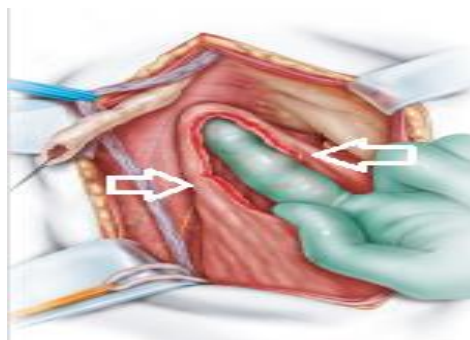


Fig. 9.1c: If there is still difficulty reaching the ureter, the bladder incision can be extended on each side (white arrows) to make the bladder flap a little longer.

Step 3: Re-implanting the ureter

- If the uterus is still present, a new tunnel has to be made in the broad ligament for the ureter to go through. This is important if the patient will become pregnant again to avoid displacement of the ureter by an enlarging uterus. Pick an avascular spot below the round ligament and pull the ureter through with an artery forceps via the stay suture.
- The ureter is re-implanted into the most accessible area of the bladder and pulled through with an artery forceps, which makes a small hole in the bladder. Leave a spout of 1-1.5 cm of the ureter protruding into the bladder lumen. This makes it easier to stitch the ureteric wall to the bladder mucosa rather than trying to stitch the ureteric mucosa to the bladder mucosa. It may also function as a valve because as the bladder fills the rising intravesical pressure will compress the ureter that is protruding.
- If the ureter is of normal size, spatulating the ends reduces the risk of stenosis (as shown in Fig. 9.4 for anastomosing two ends of one ureter). This can be for 2 cm in length. If the ureter is enlarged, then only a smaller spatulation is made i.e. ½-1 cm.
- Initially, three interrupted sutures are placed to form a triangle. The first suture is usually placed at the apex of the spatulation (Fig. 9.1d) and a good tip is to place this as a mattress suture. Then more sutures are inserted to close the gaps in between the initial 3 sutures to ensure a water-tight closure.
- If the ureter is small, a ureteric catheter should be placed early. Note: If the ureter is very dilated, you do not need a ureteric catheter (stent) although it is a good idea to routinely place one for all cases.

- The ureteric catheter must be fixed to the bladder mucosa with an absorbable suture (preferably plain catgut suture); otherwise it may be expelled into the bladder. Catgut makes it easier to remove the catheter later as it dissolves quickly. Vicryl rapide is a good alternative suture. To ensure good fixation:
 - Get your assistant to steady the ureteric catheter as you tie.
 - Take a bite of bladder mucosa near the ureteric orifice and tie a knot so that you leave the two suture ends equal in length.
 - Then wrap the suture around the catheter. First, bring the needle end of the suture around the catheter. Then bring the free end of the suture around the catheter using an artery forceps. Cross and tie the suture in front of the catheter.
 - Alternatively, the catheter can be transfixed with a fine needle to ensure it stays in.
- After the ureter is fixed inside the bladder, you may place 1-2 sutures at the junction of the outer bladder with the ureter i.e. ureteric muscle to bladder muscle. Apart from giving additional support, this also reduces tension on the anastomosis. However, this is not possible in all cases and may lead to holes and increase the risk of stenosis.
- Consider leaving an abdominal drain in case of a urine leak to prevent urine peritonitis.



When inserting sutures in the ureter, use a fine needle and fine suture (4/0 or 5/0). This is to avoid devascularising the ureter. It will also avoid creating stitch holes which will leak urine.

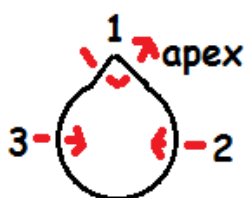


Fig. 9.1d: Shows the placement of the three initial sutures when reimplanting the ureter. The suture at the apex (1) is mattressed.

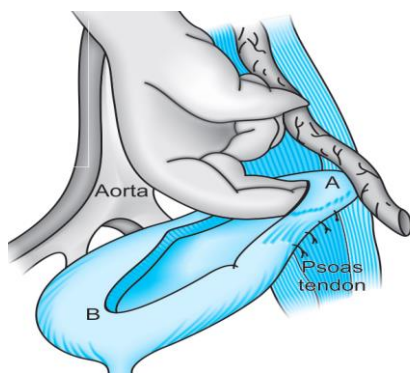


Fig. 9.2a: Shows the Psoas hitch. A strong index finger is used to pull the bladder up.

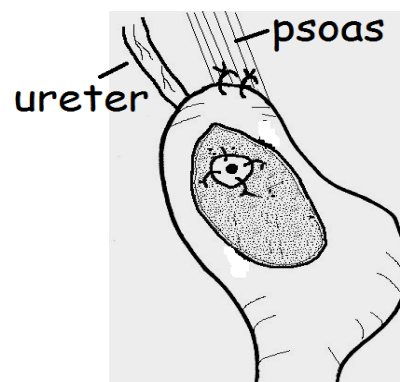


Fig. 9.2b: Shows the Psoas hitch with the ureter now re-implanted.

ADDITIONAL STEPS FOR REDUCING TENSION ON URETERIC RE-IMPLANTATION

(1) **Psoas hitch:** This is the only one of these steps that is required with any frequency. Ideally, the hitch stitch should be above the re-implantation site (Fig. 9.2b) to take the tension off the anastomosis. However, the stitch may then obscure the re-implant site so it is usually easier to place the stitch laterally first (Fig. 9.2a) and then re-implant the ureter. By pulling the bladder to the affected side, this takes the tension off the anastomosis. If the infundibulo-pelvic ligament is in the way, divide it.

- **Bladder stitch:** Place 1-2 stitches from the outside of the lateral bladder wall to the Psoas muscle 2-3 cm above the common iliac artery (Fig. 9.2 a + b). Use No. 0 or 1 Vicryl. You could also use PDS suture but there is a danger that you may have penetrated into the bladder lumen. As the bladder is weaker tissue, you need a good deep bite of at least 1cm in length
 - **Psoas stitch:** Ideally the bites are taken longitudinally through the Psoas fascia which is the upper layer covering the muscle. Try to under-run the fascia for about 1.5cm and while the needle is in this position pull up on the needle to ensure it will not pull out. There is no harm in taking a superficial bite of the muscle but do not go too deep because of the nerve plexus in the psoas muscle. In about 50% of patients, the white shiny tendon of the Psoas minor is seen where you want to place your stitch and this can be used instead.
 - Once the Psoas hitch is performed, re-implant the ureter and then close the bladder longitudinally. After re-implanting the ureter, feel behind the ureter for the amount of tension.
- (2) **End-to-side anastomosis:** If the bladder can be brought up to the ureter but not enough to pull the ureter into the bladder, you can do an end-to-side anastomosis of the ureter to the apex of the bladder incision. This is more likely if the ureter is large. Anastomosis is achieved either by:
- Using two separate sutures (3/0 Vicryl on a 17 mm needle) which both start in the midline posteriorly with the knot tied inside the lumen. One suture works towards the right side and the other to the left. The posterior wall is first approximated. When you reach the corners on each side, you come from in to out on the ureter and tie antero-laterally. The lower part of the bladder incision is now closed and the anterior ureter is then connected to the upper part of the bladder incision using interrupted sutures.
 - Using the technique described in Fig. 9.2c for the posterior wall.

- (3) **Ileal interposition:** use a length of ileum to bridge the distal ureter to the bladder. This is particularly useful in patients with a small bladder which is a common problem after VVF repair. The loop of bowel serves to enlarge the bladder as well. Alternatively, the bladder can be augmented with the loop of ileum and the ureter implanted into the new dome (bowel part) of the bladder as described in section 10.2.
- (4) **Boari flap:** This is not likely to get the bladder any higher than a Psoas hitch. It also requires planning before you open the bladder.
- (5) **Anastomose (end-to-side) to the opposite ureter:** This is easier to do if the recipient ureter is enlarged. The danger of this procedure is that it may compromise both ureters and kidneys so it would only be performed in special situations (see Fig. 9.5).
 - First, spatulate the injured ureter (see Fig. 9.4).
 - Make an incision of 1.5 cm in the recipient ureter between two stay stitches at a suitable level.
 - Use an interrupted technique as shown in Fig. 9.2c + d.
 - Stent the ureter being re-implanted.

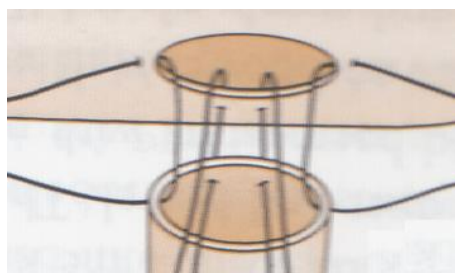


Fig. 9.2c: Shows anastomosis to the opposite ureter. The posterior edges are brought together with interrupted sutures- full thickness sutures.

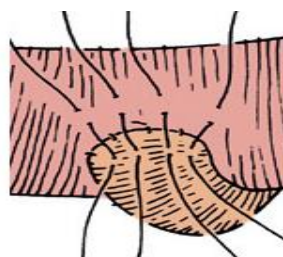


Fig. 9.2d: The anterior row is completed with interrupted sutures. Again it is often better to place all the sutures before you tie them.

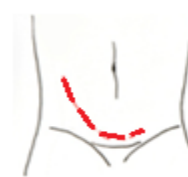

Fig. 9.2e: Shows the Gibson incision used for an extra-peritoneal approach.

(METHOD 2) EXTRA-PERITONEAL APPROACH TO RE-IMPLANTING URETER

This has the big advantage of avoiding the bowel and is a less morbid approach. However, it can only be used if you are certain which side the fistula is on. If everything is very stuck, you may have to switch to an intra-peritoneal approach, dividing the recti muscles if necessary or separating them from the pubic bones.

- Make a suprapubic transverse incision which can be curved upwards and laterally towards 2 cm medial to the anterior superior iliac spine on the affected side (see Fig. 9.2e).
- After incising the rectus sheath, oblique muscles and entering the extraperitoneal fat plane, dissect bluntly with your hand starting lateral to the rectus muscle. The ureter is found medial to the psoas muscle and mobilized. Remember that it will be close to the peritoneum. You have to watch out for the ovarian vein which can resemble the ureter.
- Mobilize and divide the ureter. Then open the bladder transversely, pull the ureter inside and then close the bladder longitudinally to get extra length so you can do a Psoas hitch if needed. While some urologists will re-implant extra-vesically (see below) through a small incision on the side or back of the bladder, vision is limited and it is much easier to see the ureter from inside the bladder (intra-vesical).

Close the fascia, muscles and sheath in one layer.

(METHOD 3) EXTRA-VESICAL APPROACH TO RE-IMPLANTING URETER

This involves re-implanting the ureter from outside the bladder rather than from inside. It can be particularly useful if the bladder is small and the ureter is large. It can be used with either the intra or extra-peritoneal approaches. An incision is made in the bladder posteriorly, large enough for the ureter to pass through.

- If the ureter is normal size or not very enlarged, spatulate it first posteriorly (Fig. 9.4).
- For splinting, a ureteric catheter is passed into the bladder through a separate stab incision in the bladder wall and then out through the initial bladder opening and into the ureter.
- It is simplest to place a row of interrupted sutures posteriorly followed by the anterior row (the same end-to-side anastomosis as in Fig. 9.2 c). It is often easier to place all the posterior sutures before you tie. Repeat the same for the anterior row.
- Start with the ureter (go from out to in: see Fig. 9.3), then to the bladder (go from in to out). When this is tied, the knot will be on the outside. However, it is not critical that the knots end up on the outside.

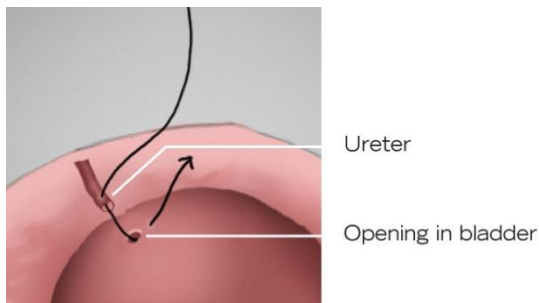


Fig. 9.3: Shows the technique of re-implanting the ureter from outside the bladder.

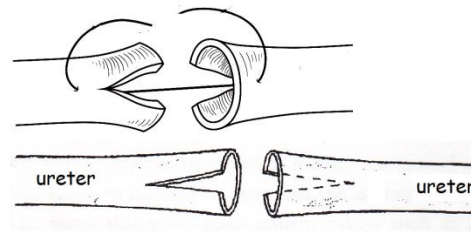


Fig. 9.4a and b: Spatulation: incision is made longitudinally on both sides.

Ureteric injuries above the level of the pelvic brim: In this case, an end-to-end anastomosis can be performed. First, spatulate both ends (Fig. 9.4a) to prevent stenosis. The spatulation should be about 3-5 mm on each side. Make sure both ends are healthy and tension free. The apex of one spatulated end is sutured to the base of the other spatulated end with interrupted sutures (Fig. 9.4b). Place but do not tie these two sutures first which become the stay sutures. Once placed, tie both. Then place sutures between the stay sutures. The repair should be stented for 2-3 weeks.

Stents for all approaches: The ureteric catheters (or infant feeding tube) can be brought out either:

- Suprapubically, via one angle of the bladder incision or through a separate stab incision.
- Through the urethra: thread the ureteric catheter into the Foley catheter and then deflate or burst the balloon of the Foley in the bladder. While you hold on to the ureteric catheter, your assistant pulls out the Foley from below and then puts in the (new) Foley from below.

Ureteric injury in a pelvic kidney: On two occasions, I have encountered a pelvic kidney in association with a ureteric fistula. It can be difficult to find the ureter in these cases. The options are:

- Do a nephrectomy especially if it is a small hydronephrotic kidney (see Appendix 5) but you would need to know the size and preferably the function of the other kidney first.
- If you think the kidney is worth preserving or there is no evidence of a contralateral ureter/ kidney, anastomose the renal pelvis directly onto the bladder.

(9.2) DOUBLE URETERS, ECTOPIC URETERS AND VAGINAL RE-IMPLANATION OF URETER

DOUBLE URETERS

The incidence of double ureters has been quoted as 1:125. The extra ureter(s) may be found opening into the bladder or vagina. When they occur, they can be difficult to diagnose as shown by the following case histories.

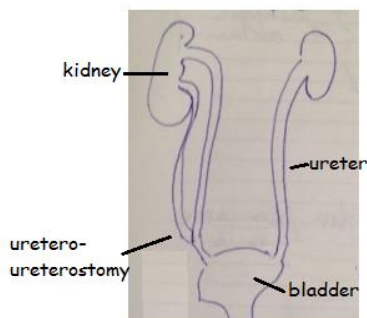


Fig. 9.5: This is a diagram from the operative notes in Case history 2. Courtesy of Andrew Browning.

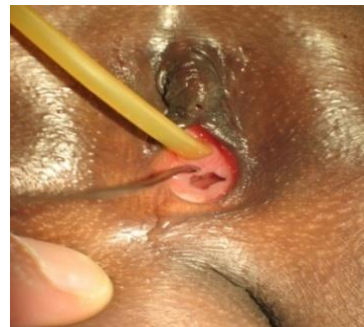

Fig 9.6a: Shows an ectopic ureter with a probe in it. In this case, it is helpful to pass a catheter, probe or a guide wire up the opening to see which side is affected.

Case history 1: A patient sustained a ureteric fistula following a Caesarean delivery. During abdominal fistula repair, the patient's right and left ureters were catheterized at surgery and found to be normal. A third (double) ureter was found on the right side which was dilated and obstructed 2.5 cm proximal to where it should have opened into the bladder. This ureter was mobilized and re-implanted into the bladder. All three ureteric catheters were draining at the end of the operation.

Case history 2: A patient presented with leaking urine for six years following Caesarean delivery. There was a history of two laparotomies following the Caesarean section for possible ureteric fistula. However, as the operations were performed in another hospital, there were no notes available. The patient continued to be wet following surgery. On admission, a dye test was negative at 240 ml. Clear urine was seen coming from the vagina. An intravenous urogram showed a double ureter on the right side. At laparotomy, both the right and left ureters had previously been re-implanted. There was a duplex system on the right side. The bladder was very

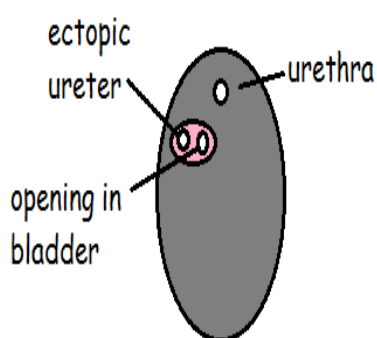
stuck with no mobility. A cystotomy was performed and a ureteric catheter was passed up on the right side to confirm the previous re-implantation. The double ureter on the right side which was not draining into the bladder was transected and spatulated. An end to side uretero-ureterostomy (see Fig. 9.5) was performed over a 5F ureteric catheter. The patient was discharged home dry.

ECTOPIC URETER

(Also see page 3 for diagnosis.)An ectopic ureter terminates in a site that is not in the urinary bladder and is usually part of a duplex ureter. It is often thin and dilated and found in the antero-lateral wall of the vagina proximal to the meatus.

! Top Tip! Under anaesthesia, after giving fluids and frusemide, examine carefully vaginally for the site of leakage and try to catheterize the ureteric opening. Allow up to 30 minutes for this step as otherwise it is easy to miss the diagnosis. The opening may be in the midline (Fig. 9.6a) or to one side. It is worth trying to pass a catheter or guide wire to see which direction it takes. It often only passes into the ureter a short distance but the direction it takes will guide you as to which side it is on. There are two options:

- (a) **Abdominal:** The usual approach is to re-implant it abdominally into the bladder. As the ureter is healthy and of good length, it is usually not difficult to re-implant. An extraperitoneal approach can be used. Via a low transverse incision, on one side, the ureter will be duplex e.g. on the right side. Then open the bladder and catheterize the right ureter draining into the bladder. Feel for the ureteric catheter in both ureters. The ureter without the catheter on the right side will be the ectopic one. In some cases, the ectopic ureter will be enlarged.
- (b) **Vaginal:** Occasionally, if the ureter is clearly visible vaginally and not too distal, it can be re-implanted trans-vaginally. If the ureter opens along the urethra or if the vagina is still small.it would be difficult to use this method.



- Make a circumferential incision (Fig. 9.6b) in the vagina around the ectopic ureter and just beside it where you will make the bladder opening.
- Pass a metal catheter (or a curved clamp) into the urethra/ bladder and then down to beside the ectopic ureter. Incise over the metal catheter. You do not need to mobilize the ureter.
- Insert a ureteric catheter into the ureter and then pass it into the metal catheter and then into the bladder and out the urethra.
- Close the bladder over the ureter/ ureteric catheter.
- The ureteric catheter can be left in for four weeks.

Fig. 9.6b: Vaginal re-implantation of ureter.

VAGINAL RE-IMPLANTATION OF URETERIC FISTULA

These fistulas are usually only seen following a previous VVF repair. The following diagram and photograph illustrate examples and how to manage them.

<p>Case 1: Fig. 9.7: Diagram of operative notes.</p> <p>This patient had a previous VVF repair. She was found to have a pinhole VVF on the right side and the right ureter was seen separately draining on the outside of the bladder wall (Fig. 9.7). The pinhole VVF was enlarged towards the ureter and the ureter was re-implanted into the bladder through the VVF after catheterizing the ureter.</p>	<p>Case 2: Fig. 9.8: Photo of a ureteric fistula.</p> <p>In this case, the ureter has retracted outside of the bladder after a VVF repair. If a ureteric catheter can be inserted into the ureter as shown, then the ureter can be re-implanted vaginally using the method shown in Fig. 9.6b (Photo Kees Waaldijk).</p>
--	---

Case 3: A patient was having a repeat VVF repair of a right lateral pinhole vault fistula. During mobilization of the vagina, the left ureter was injured away from the VVF. It was re-implanted into the bladder using the technique shown in Fig 9.6b with a metal catheter to pull the ureteric catheter back into the bladder.


CHAPTER 10

URINARY DIVERSION AND BLADDER AUGMENTATION PROCEDURES

Section 10.1: Mainz II pouch and ileal conduit

Section 10.2: Bladder augmentation

About 5% of all VVFs fall into the category of deemed incurable fistulas. However, there is no standard definition of what constitutes an incurable fistula and significant experience is necessary to make this decision. *Reference: Urinary diversion in the vesico-vaginal fistula patient: General considerations regarding feasibility, safety, and follow-up: S.D. Arrowsmith IJOG (2007) 99, S65–S68.*

RECOGNISING FISTULAS THAT CANNOT BE CLOSED OR WHERE DIVERSION IS REQUIRED i.e. where reconstructing normal anatomy or function is not possible.	
<i>Bladder destroyed</i>	<ul style="list-style-type: none"> • If there is total bladder destruction, she will need a diversion (see section 10.1). • If there is a small bladder but an intact urethra, you can augment the size of the bladder (see section 10.2).
<i>Urethra destroyed</i>	<p>There are two options:</p> <ul style="list-style-type: none"> ➤ If the bladder is intact but the urethra is absent, you can potentially construct a neourethra. ➤ The lower end of the bladder can be closed off: <ul style="list-style-type: none"> • Occasionally these cases are suitable for a Mitrofanoff procedure where the appendix is used to form a channel between the bladder and the abdominal wall. • A suprapubic catheter may be a simpler option.
<i>Combination</i>	A combination of factors is often present e.g. several failed repairs, a lot of scarring, sub-total bladder destruction, or a destroyed urethra.
	The decision that a fistula cannot be closed should only be made by an experienced fistula surgeon. If possible two experienced surgeons make this decision together.
<i>Summary</i>	<ul style="list-style-type: none"> • Good urethra + small bladder = augment bladder • Bad urethra + good bladder (> 100 ml) = Reconstruct the urethra or Mitrofanoff procedure or suprapubic catheterization • Bad urethra + small bladder = Diversion?

TREATMENT OPTIONS

If you decide that you cannot close the fistula, the options are:

(A) **Non-surgical:** There is a tendency with medical staff to want to do something to help the patient. However, there is no ideal method of diversion and complex procedures entail significant morbidity and mortality.

Doing nothing is not an option, but we should try to provide the patient with:

- Pads and barrier zinc oxide cream which is a safe alternative.
- Free visits at a clinic with free medications.
- Social and financial support.

These will make the life of the incurable patient substantially easier. These patients need lifelong care, with or without diversion.

(B) **Surgical:** There are no really good options.

- *Mainz II pouch:* This may be thought of as the ‘least worst’ option in low-resource settings because of the straightforward surgical approach and the socially acceptable resultant voiding function.
- *Ileal conduit:* This requires the patient to live near to a supply of stoma bags. So for many patients, this is not an option unless these can be provided.
- *Continent pouch* where the patient catheterizes herself e.g. Mitrofanoff appendico-vesicostomy procedure. However, it can be difficult to close off the lower bladder. This is usually best done by mobilizing first from below (vaginally) and then closing from above (abdominally). There is a risk of leakage vaginally if the lower bladder does not heal.
- *Suprapubic catheter/ diversion:* While not often mentioned, this is sometimes an option if the bladder neck has closed due to scarring. It is also possible to close the lower end of the bladder either suprapubically or

vaginally where it is not possible to have a functioning urethra e.g. in severe cases of stress incontinence that have failed other treatments. The bladder would have to be of adequate size to perform this. It may avoid doing a more formal diversion.

- The opening is normally placed two fingerbreadths (3-4 cm) above the pubic symphysis and if necessary, it can be lateral to the midline if you have just done a midline laparotomy. If done as an open procedure, stay extraperitoneal. If made too low down, it is more difficult and probably less comfortable. The catheter does not have to be stitched in and can be retained by the balloon.
- If the catheter falls out, it needs replacement within a few hours as the track closes off quickly, resulting in urinary retention. Therefore she ought to be able to get to hospital quickly to have it reinserted.
- The patients tend to do better with a catheter of reasonable diameter i.e. 16,18 or 20 F.
- The initial catheter should be changed after 5 weeks. Thereafter, if it is latex it should be changed monthly and if silicone, change three monthly.
- In the long-term, any indwelling catheter can be complicated by urinary infection, bleeding, bladder stones and rarely bladder cancer.
- Some patients leak around the catheter but this is from bladder spasms so oxybutynin may help. If the catheter blocks, they will also leak around the catheter.

Reference: The ethical and technical aspects of urinary diversions in low-resource settings: a commentary BJOG. 2016 Jul; 123(8):1273-7. Wilkinson J et al.

(10.1) MAINZ II POUCH AND ILEAL CONDUIT

MAINZ POUCH II

Before considering a Mainz II pouch, the following criteria should be met:

- (a) The patient should have normal or almost normal renal function. If renal function is impaired, the patient is more likely to become acidotic. Renal ultrasound should also be performed. If there is moderate or severe bilateral hydronephrosis, then a pouch is contraindicated.
- (b) HIV test: the procedure is best avoided if HIV positive with low CD4 counts or high viral loads.
- (c) The patient should have an intact anal sphincter. This can be tested by getting her to hold an enema of 250 ml for 60 minutes while walking around. A useful tip is to add dye to the enema so that you can distinguish anal leaking from the urine leak from the VVF. Wipe carefully after injecting the dye. She should wear a pad which should be unstained by dye after 60 minutes.
If she has a sphincter tear: This would have to be repaired first. Provided she can hold 250 ml of dye without leaking, she should then be suitable for a Mainz pouch. However, others would consider an anal sphincter injury to be a relative/absolute contraindication for diversion. We know that even after repair, sphincter function will be compromised and deteriorate in the majority of patients. That may lead to nightly soiling of the bed as the internal anal sphincter relaxes.
- (d) Make sure she does not have an RVF. There may be an unrecognized RVF in a tight band of scar as patients with bad VVFs often have an (unrecognized) RVF. Repeat a dye test immediately before surgery in the operating room.
- (e) Informed consent must be obtained. She should understand that:
 - Both urine and stool mixed will now pass via the anus.
 - Night soiling with incontinence of liquid stool may occur, probably worsening with age.
 - By obtaining continence, this could shorten her life-span due to long term complications such as acidosis, renal failure and colonic malignancy.

It often helps the patient to meet another patient who has had the procedure. It is not uncommon to find patients who want their Mainz pouch reversed after 5-10 years and who would not have chosen the procedure if they had fully understood what it involved. Many patients will prefer to stay incontinent rather than passing/ leaking urine with stool.

- (f) Ideally, she should live relatively near the centre as long-term follow up is essential.



If the patient has had a VVF or an RVF repaired, always check that there is no leak from the rectum regardless of what the patient says. Even a small leak will reveal itself once urine is in the colon.

In one study, the overall peri-operative mortality was 2.5 %. *Reference: Urinary diversion for patients with inoperable obstetric vesicovaginal fistula: the Jos, Nigeria experience: Kirschner C.V. Lengmang S.J. Karshima, J.A., Arrowsmith, S. Int Urogynecol J June 2016; 27(6):865-70.*

However, the five-year mortality may be a lot higher so it is not a procedure to undertake without careful discussion with the patient. She must be intelligent enough to understand all the possible problems.

The main advantage of this operation over simple ureteric implantation into the colon is that the patient is less likely to leak when asleep although it still happens. It creates a high volume but low-pressure pouch.

PRE-OPERATIVE

- Full bowel preparation may be undertaken, or alternatively the lower bowel should be washed out.
- Put in a wide rectal tube for drainage of urine (e.g. a size 7 or 8 endotracheal tube). If this is difficult to insert because of a rectal stricture, it can be passed from above during the operation i.e. pass a clamp from below and pull the tube down, or pass clamp from above and pull tube up.
- If there is still stool in the rectum, using a bladder tipped syringe, irrigate through the rectal tube with betadine/ saline solution until it runs free of debris.

OPERATION

There are two variations to the Mainz II pouch. The following description is that of a single loop pouch. The double loop pouch is described later.

- Make a midline abdominal incision. While holding the loop of sigmoid, put a pack up on each side to push the small bowel into the upper abdomen.
- On the left side, cut the peritoneum lateral to the sigmoid colon which will help mobilize the sigmoid and will also help find the ureter on the left.
- Divide the ureters before making the pouch as this would be difficult to do later. The exact level is not critical so anywhere convenient in the true pelvis is acceptable. When you hold the ureter up with Babcock's, cut underneath to free it. If there is bleeding as you dissect the ureter off, do not be afraid to use cautery cautiously.
- The pouch should measure 10 cm in length of sigmoid on each side and is formed by joining the two sides of the sigmoid together by a side-to-side anastomosis (Fig. 10.1).
- All the surgery is done from the anterior aspect (i.e. in front of the bowel).

(Step 1) Posterior outer layer: Suture the two intact sides together (see Fig. 10.1) continuously, starting superiorly and continue for approximately 12 cm. The important point is to make sure the sutures are in the bowel wall and to avoid the mesentery of the bowel. Try to bite into the muscle along the taenia coli. When correctly done, you should not see fat between sutures. This layer of sutures will become the posterior outer layer.

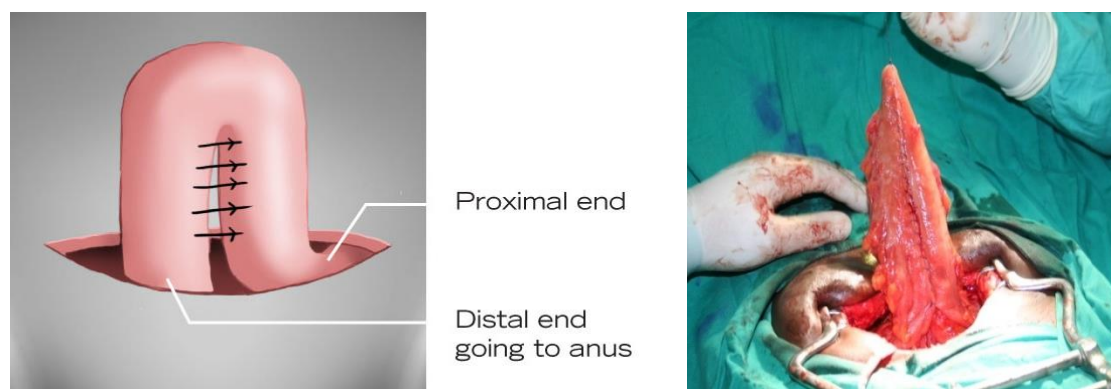


Fig. 10.1a and b: Show the initial joining of the two loops of sigmoid with the posterior outer layer stitched.

(Step 2) Incision: (see Fig. 10.2) Start at the top and work your way down on each side. If you cut along the taenia coli you get less bleeding and the edges will hold the sutures better. This incision is made 3 to 5 mm from the initial suture line. It is safer to open the bowel with scissors rather than cautery.

(Step 3) Stitch posterior inner layer: (Fig.10.3) Make sure you are getting full thickness of mucosa and muscle. With a continuous stitch, start proximally and when you reach the distal end, come out of the bowel

lumen with the stitch. Take one bite on the outside and lock (\pm tie) the stitch so that the tension is maintained on the suture. You can leave the suture attached to the needle holder and use it later for the anterior layer.

(Step 4) Ureters inserted into bowel: A site for ureteric insertion should be selected about half way along the posterior wall. If you place the opening too high up, there will be a gap under the ureters where bowel could potentially become trapped.

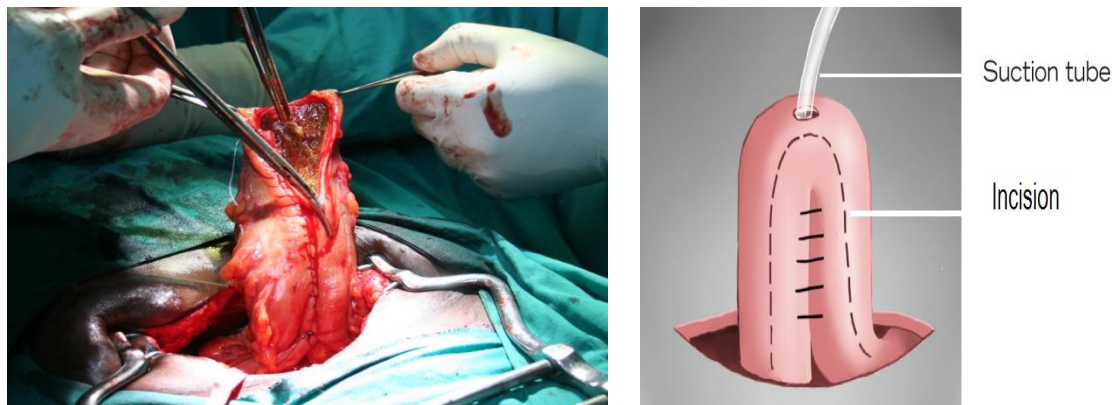
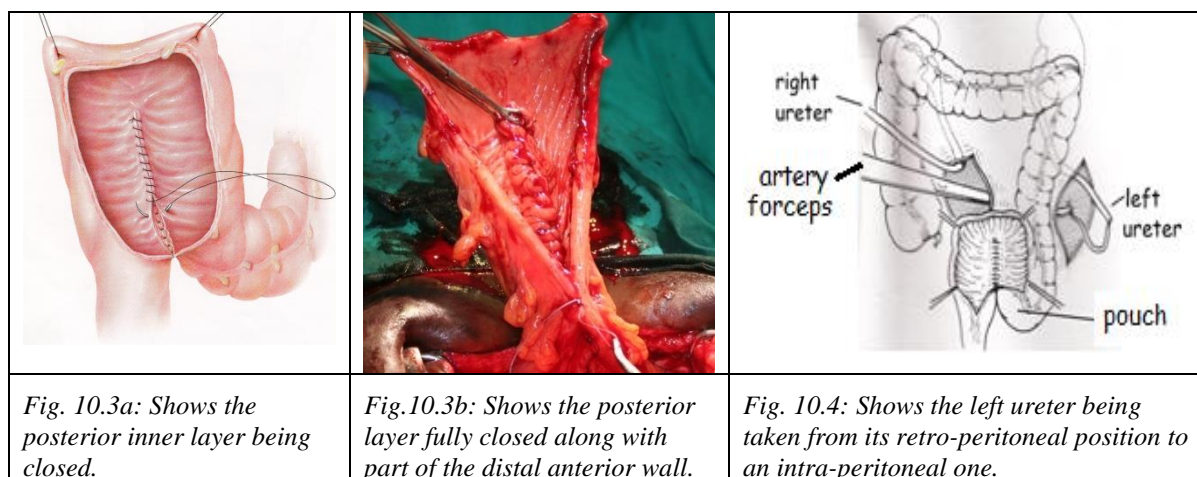


Fig. 10.2: a + b: Open the apex of the loop and incise the bowel on either side of the first layer of sutures.



- The right ureter is usually easy to insert as it sits beside the pouch. The left ureter is more difficult. Using a long artery forceps (Fig.10.4), bring the left ureter from its retroperitoneal site on the left (going through the mesentery of the sigmoid colon or behind the descending colon) to lie close to the right ureter. Make sure to pick a puncture site free of mesenteric vessels. If necessary, make a small opening in the peritoneum over the mesentery of the sigmoid with cautery so that you can see an avascular area.
 - Put a 3/0 stitch onto the end of the ureter to avoid pulling on the ureter directly with a forceps (see Fig. 9.1d).
 - Pull the ureter into the colon by making a stab incision with an artery forceps.
- Once the ureters are pulled into the colon, place a ureteric catheter in each. (If the ureter is not enlarged, spatulate the ends (see Fig. 9.4). Either:
- Attach the mucosa of the ureter to the bowel mucosa with several interrupted sutures (see Fig.10.5).
 - Pull in 2-3 cm of the ureter to make a spout and stitch the bowel mucosa to the side wall of the ureter. If you do this, you can then make a second layer by stitching the ureteric mucosa to the bowel mucosa. See chapter 9 for the technique of ureteric re-implantation.

- Fix the ureteric catheters to the pouch mucosa with plain catgut to prevent them being expelled by peristalsis. Also, fix them on the outside of the bowel wall.
- Pass the ureteric catheters into the rectal tube and suture them to the tube so that when the rectal tube is removed, the ureteric catheters will be removed at the same time.

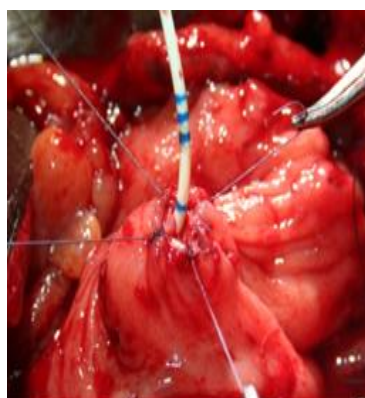


Fig. 10.5: The ureter has been sutured to the colonic mucosa.

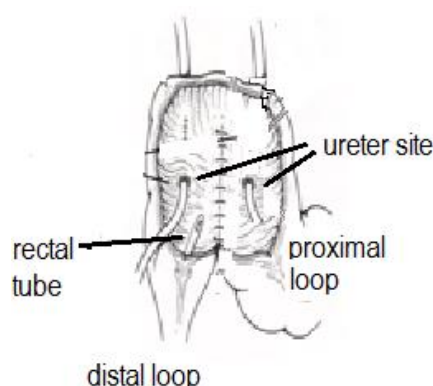
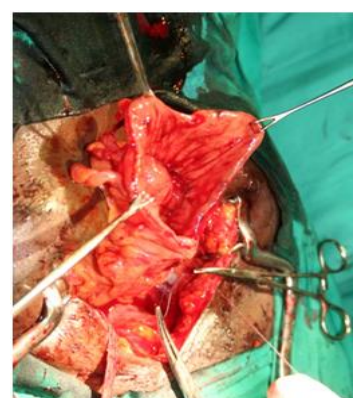

Fig. 10.6 a and b: The ureters are implanted, the anterior layer is about to be closed.



(Step 5) Anterior layer

- *Inner layer:* This is done continuously initially with the suture previously used for the inner layer of the posterior wall. However, it is usually necessary to also use another suture which is best started at the apex/proximal end and joins the initial suture in the middle of the pouch.
- **! Tip!** To get the mucosa to invert and to get good bites of the bowel, as you insert the needle just above the mucosa, push the mucosa down with the needle.
- *Outer layer:* It is better not to do a continuous second layer anteriorly because it can create too much tension and stitch holes, which are then very difficult to deal with. It is better to place interrupted sutures only if you see there are any gaps in the anterior inner layer.

Abdominal drains may be placed on each side near the site of the ureteric mobilization. These are best made with the tubing (drain) and urine bag (to collect any fluid) that attaches to a Foley catheter.

POST-OPERATIVE CARE

- Leave the rectal tube (with the ureteric catheters attached) in for 7-10 days. If you do not secure it well (e.g. with nylon) to the anal region, it will fall out early.
- Start sips on day 1, then fluids or a light/ soft diet for four days.

If the pouch breaks down

The following is how I have managed this difficult situation:

- (1) Do a transverse de-functioning colostomy.
- (2) Through the area of breakdown, re-insert ureteric catheters into the ureters and pass a rectal tube up from the anus if the original one has come out.
- (3) Close the area of breakdown with interrupted sutures.
- (4) Place a drain in the pelvis in case there is any urinary leak.
- (5) The colostomy can usually be reversed after 3-6 months.

If there is a leak from the ureter: this is more likely to occur if the ureteric stent falls out. This will require re-operation and re-implantation of the ureter.

LONG TERM RESULTS AND PROBLEMS OF THE MAINZ POUCH

The Mainz pouch has an important place in all parts of the world but is particularly useful in settings where stoma bags are difficult to obtain.

- (1) *Acidosis:* develops in about 50% of patients by four years due to colonic re-absorption of acid from the urine. It may present with weight loss. Normal renal function can often compensate for the acidosis. To

prevent acidosis, give sodium bicarbonate (baking powder) 600 mg twice daily or 2.5 ml (half teaspoon) each day dissolved in a glass of water and advise regular voiding. Patients should probably not go all night (i.e. seven hours) with a loop of colon full of urine.

- (2) In a patient with compromised renal function, a Mainz pouch will make it worse due to resorption. In patients with normal renal function, the urea only rises slightly.
- (3) *Tumours*: 20% develop tumours in the sigmoid colon by 20 years. The earliest report of a tumour is at 12 years.
- (4) *Uro-sepsis* risk is increased. If they have repeated infections, you need to consider uretero-colic stenosis. Overall the best policy is that the patient needs to go to hospital if they get unwell no matter what the diagnosis is
- (5) *Obstructive nephropathy*: May present with recurrent pain and pyelonephritis. It may occur for two reasons:
 - Uretero-colic stenosis: Tunnelling the ureters under the mucosa for three cm was previously recommended to reduce reflux and fix the ureters more securely. However, this has been found to increase the risk of later stenosis at the site of implantation and about a third of all patients develop hydronephrosis and renal impairment if tunnelling is performed. A simple end to side anastomosis is adequate. The disadvantage of anything more complex in achieving an anti-reflux tunnel is that there is always a risk that the blood supply to the end of the ureter will be compromised by more complicated surgery, leading to a stricture.
 - Functional obstructive nephropathy is due to a gradual rise in pouch pressure towards normal colonic pressure, which is much higher than bladder pressure (upper limit at rest about 15 cm H₂O). Eventually, the upper tract pressure will have to rise above 15 cm to push the urine out i.e. there will be a state of obstruction and, even without a stricture, hydroureter and eventually obstructive nephropathy will develop. (The kidneys can only tolerate pressures up to 20 cm H₂O). This course of events is not prevented by including the anti-reflux procedure with the anastomosis.
- (6) *Wet at night*: the incidence seems to be higher in fistula patients compared to others. One study reported that 30 to 50 % of fistula patients are wet at night following the Mainz Procedure (Mike Bishop unpublished data). To reduce the risk of nocturnal incontinence:
 - Advise the patient to reduce her fluid intake in the evening.
 - Have the patient wake up to void during the night with an alarm.
 - If new onset leakage of urine develops during the night or even during the day, tightening up their sphincter may help at least for a few years.
 - Another option is to use the Double Loop Pouch. In a series in Addis Ababa Fistula Hospital, nine out of ten patients were dry at night.

DOUBLE LOOP MAINZ POUCH

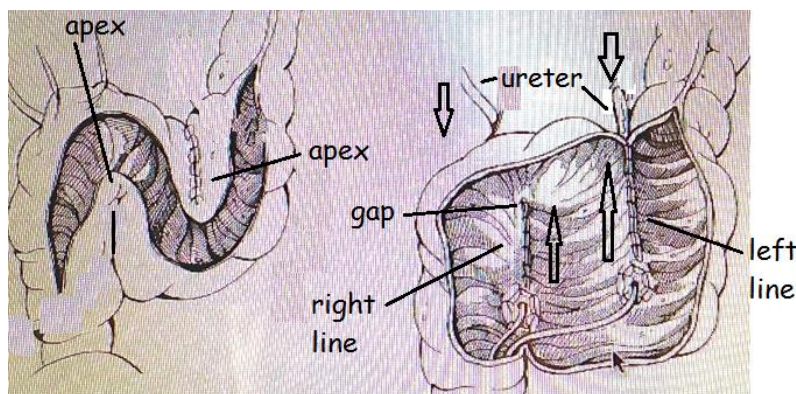


Fig. 10.6c: Shows the incision made for the double pouch. Fig. 10.6d: Shows the two posterior walls closed and the ureters brought into the pouch. The lower arrows indicate the direction of closure of the posterior outer layer on each side. The upper arrows show the direction the two ureters are pulled in.

This incorporates the lower part of the descending colon into the pouch to make a larger pouch. According to the Addis Ababa Fistula hospital where this larger pouch is performed, there are several advantages:

1. As the pouch is larger, the patient is less likely to leak urine, especially during sleep.
2. It is easier to make a tunnel for dilated ureters using an extra-mural tunnel.
3. The risk of stricture and infection is reported to be less.

The disadvantages may be related to the larger volume of urine stored in the pouch which may lead to more resorption of urine and increased risk of acidosis. To avoid this, the patient should void at least once during the night, using an alarm clock to wake her. It is also technically a more difficult procedure to do.

Method:

- It may first be necessary to mobilize the descending colon as far as the splenic flexure.
- The incision is made as shown in Fig. 10.6c.
- Closure is performed as in Fig. 10.6d with the left posterior wall first, then the right posterior wall and finally the anterior wall.
- All the suture lines are done continuously.

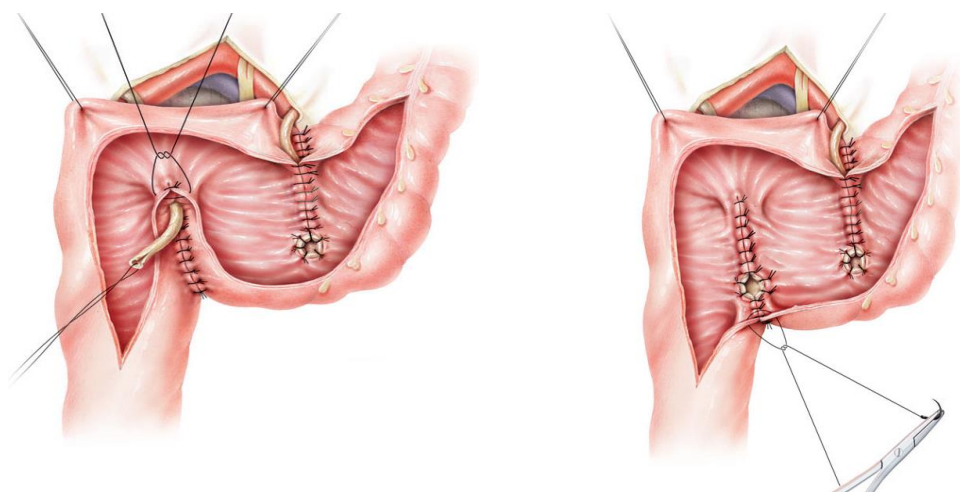


Fig. 10.6e: Shows the left ureter already fixed in the pouch and the right brought in but not yet fixed.

Fig. 10.6f: Shows the same as Fig. 10.6d.

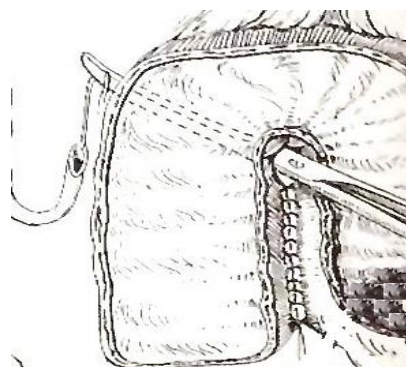


Fig. 10.6g: Shows the right ureter being brought into the pouch.

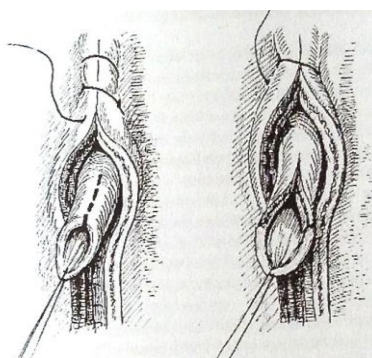


Fig. 10.6h: When cutting ureter, always cut obliquely and spatulate. Once the ureter is brought into the pouch, it is fixed into position by suturing the mucosa over it so that only the meatus is not covered.

- *Posterior wall: left side closure:*

1. Starting at the left apex and working proximally, make a posterior layer which is below the mucosa. Go from distal to proximal. This will create the base of the tunnel for the ureter which is placed on top of this layer. Some prefer to use 3/0 or 4/0 Prolene rather than Vicryl for this layer.
2. The left ureter which has been brought in intra-peritoneally is now pulled in to lie on top of this layer. Pull the ureter distally to make it straight as you fix it.
3. Close the mucosa over the ureter (Fig. 10.6f). As the ureter often ends up about half-way along the suture line (left line) you may have to close the proximal mucosa first and then the distal part.
4. Check that the ureteric catheter runs freely in the tunnel.

- *Posterior wall: right side closure:* The same steps are repeated on the right side but you have to leave a gap (see Fig.10.6d+g) to allow the ureter to be pulled in. Use a slightly curved instrument to pull it in rather than one that is too angled.
- *Anterior wall:* Close the anterior layer in one layer. Start at the right lower corner and finish at the left upper corner. You may end up with two ‘corners’ on the right side so you may have to do these separately.

ILEAL CONDUIT (see Appendix 6 for check-list for counselling the patient about this procedure).

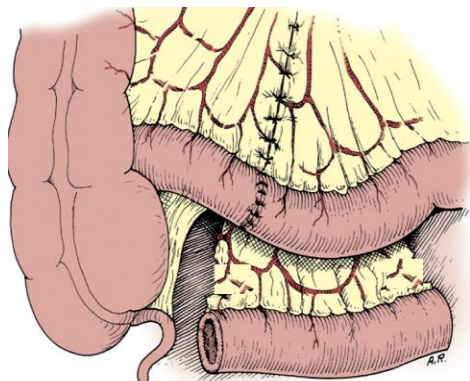


Fig. 10.6i: Shows the ileal conduit formed.

(a) *Prepare the conduit:*

- A 15-20 cm segment of lower ileum is used with the length long enough to reach the abdominal wall. Avoid the terminal 15-20 cm of the ileum (needed for absorption). Mark the distal end with a long stitch and the proximal end with a short stitch.
- The incision in the mesentery needs only to be 5-7 cm to give the segment enough mobility. Transilluminate the mesentery to see the blood supply before cutting.
- The main bowel is re-anastomosed above and medially so that the ileal conduit is below and lateral.
- Flush the segment of ileum with saline.

- (b) *Prepare the ureters:* The left ureter must be brought to the right side over the great vessels and posterior to the sigmoid mesentery as in Fig. 10.4. Spatulate the ureters for 0.5 cm.
- (c) *Insert the ureters into the conduit:* The ureters are inserted separately to the side of the ileum using the method described in Fig. 9.2 c +d. Place the left ureter at the left end and the right ureter somewhere along the loop. Make a small incision in the bowel wall using an artery forceps inserted into either end of the conduit to tent up the bowel as you cut. Suture the full thickness of the ureter to the full thickness of the bowel with interrupted sutures. Take good bites on the bowel as you cannot narrow it.
- (d) The anastomosis is stented with a ureteric catheter. Pass the Yankauer suction tip or a long artery forceps down the loop and feed the ureteric catheter into it to bring it out the end of the ileum.
- (e) *Close the proximal end of the conduit.*
- (f) *Bring the conduit through the abdominal wall.* To make the stoma, pull on the skin with an Allis forceps and cut an oval hole. You can also hold the fascia with an Allis forceps before making a cruciate incision. It is important that two fingers can pass through the tunnel.
- (g) *Make a spout:* You need to make a spout of at least three cm. To get the bowel to evert, pass a Babcock’s forceps into the lumen and grasp the mucosa at least 3 cm down. Then holding this, pull the bowel mucosa up. To keep the bowel everted, stitch from the skin edge to the outer bowel serosa about 6 cm down and then to the edge of bowel mucosa. Insert four of these sutures. Then the rest of the defect is closed by suturing the bowel mucosa directly to the skin. You do not want any gaps between sutures large enough that you can put your finger into.

(10.2) BLADDER AUGMENTATION

INDICATIONS

- *Post VVF repair:* This is occasionally indicated in a wet patient (VVF closed) where the bladder is very small but there is a functioning urethra. In cases where the urethra may be incompetent, a deliberately obstructive sling may be inserted either before the augmentation or at the same time. As the patient will have to do self-catheterization anyway, if retention occurs this will not be a major problem.
- *During VVF repair:* It is very occasionally performed at the same time as a VVF repair when there is a very small bladder ± a ureter which needs to be re-implanted. The only time I have done this was for a high VVF where there was a good urethra. The bladder was only able to hold the Foley balloon with 3-4 ml inflated. The right ureter needed to be re-implanted. By enlarging the bladder, this made it easy to re-implant the ureter into the new (bowel) part of the bladder.

Ideally, the patient should be able to perform intermittent self-catheterization before the operation as she will need to do it after the operation.

OPERATION

(a) *Bladder*: First mobilize the bladder all around. Start by placing dissecting scissors in the midline just behind the pubic bone and spread them. Then work laterally on each side to free the bladder from the pubic bone, using cautery if necessary. The bladder is then opened longitudinally (some prefer transversely) in the midline, dividing both the anterior and posterior walls (Fig. 10.8A).

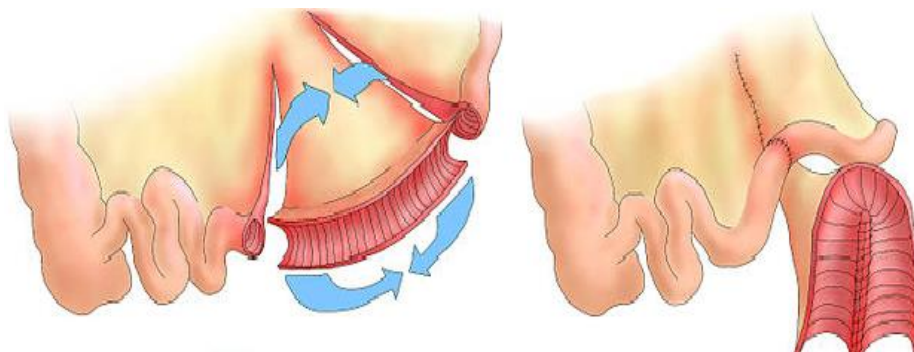


Fig. 10.6j: Shows the segment of bowel taken from ileum and the ileum is re-anastomosed. The segment for the augmentation is brought below the re-anastomosed bowel.

(b) *Bowel*: A 20 cm segment of the lower ileum (Fig. 10.6j) is used to increase the bladder size. The blood supply is kept intact through the mesentery. Avoid the terminal 20 cm of ileum, as this is essential for absorption of Vitamin B12. The bowel is re-anastomosed before proceeding with the next step.



When operating on the intestine, avoid using cautery within 2 cm of where any anastomosis will be made. Therefore it is much safer to cut the intestine with scissors.

(c) *The augment*: After isolating the bowel, open along the anti-mesenteric border with scissors (Fig. 10.7B). First, the opened loop is stitched to itself longitudinally (Fig. 10.6j and 10.7C). This suture should be continued around the corner so that points 1 and 4 end up together as in Fig. 10.7C. It can be further stitched to itself on each side (Fig. 10.7D) to make it a more dome shape (Fig. 10.8B) which reduces the length of the edges. This makes it easier to suture to a small bladder.

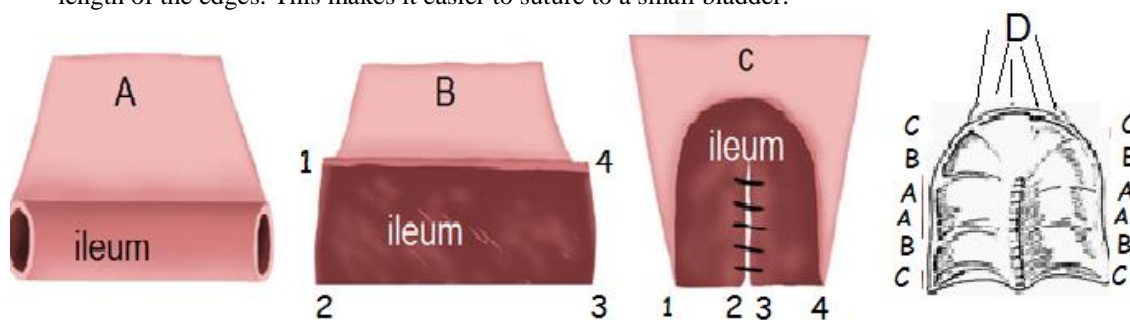


Fig. 10.7: A shows the isolated loop of ileum; B: shows the ileum opened along the anti-mesenteric border and C then folded onto itself by suturing the inner edges. It is then D sutured on each side by taking bites from A to A, B to B and C to C on each side which results in a more dome-shaped piece of bowel.

(d) *Attaching the bowel to the bladder*:

- First, the posterior part of the bowel dome is stitched to the posterior wall of the bladder.
- This is done by using two separate sutures starting in the midline posteriorly. Go from out-to-in on the bladder and in-to-out on the bowel. Place and tie both sutures. Make sure there is no gap between these sutures.
- Continue one continuous (full-thickness) suture around to the left side and the other to the right side (Fig. 10.8B).
- When the posterior and lateral walls are sutured, the anterior part of the bowel dome is then stitched to the anterior bladder wall. This is easier to do than the posterior. You may start again in the midline anteriorly with two separate sutures and work laterally, or you may work from lateral to the midline anteriorly.

! Tip! If you end up with excess bowel to close to the bladder anteriorly, then stitch the bowel to itself longitudinally.

- Place a suprapubic catheter (preferably 24 F) for 21 days and a urethral catheter (18-20 F) for 28 days. The reason for leaving the urethral catheter longer is to prevent leaking from the bowel segment at the suprapubic catheter site once the catheter is removed. It is difficult to place the suprapubic catheter through the native bladder since it is often so low down and lateral after the augment.
- An abdominal drain must be placed near the bladder which is left in for at least 7 days. The drain should only be removed if the drainage is < 100 ml/ day.

! Top Tip! It is a good idea to transfix the abdominal drain so that it does not come out prematurely.

- Some surgeons irrigate the bladder daily via the suprapubic catheter to clear mucus. It then should flow out of the urethral catheter.
- Mucus can give the urine an “infected appearance”. However, only treat for urinary tract infection if the patient has fever and renal angle pain.

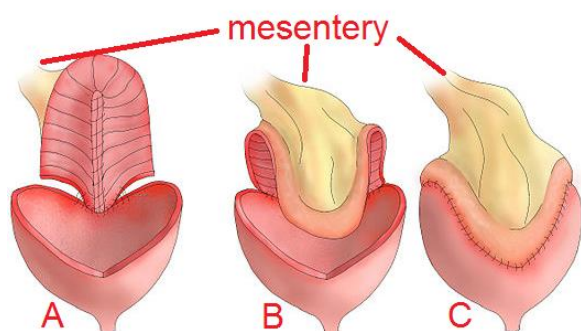


Fig. 10.8: A shows the bladder split open longitudinally and the posterior part of the bowel is being sutured onto the posterior bladder. In B the posterior wall is almost complete and then in C the anterior wall is now sutured.

POST-OPERATIVE PROBLEMS

There are two common and two less common problems with an augmented bladder:

- (a) Mucus can be a problem for many months (especially in the first 3-6 months) and there is the risk of mucus causing urinary retention and rupture of the augmented bladder. To avoid this, the patient needs to catheterize herself once a day. The larger the catheter, the better evacuation of mucus will be.
- (b) It is likely the patient will not empty her bladder well due to the size of the augment. The bowel section will over distend and stretch out. The bladder can quickly develop 1,000 ml capacity and may never void well again. Using less bowel during the augment does not reduce this risk because of the small contracted native bladder. To avoid this, the patient should catheterize herself at least 2 to 3 times a day.

If the patient is voiding well or can empty with straining (Valsalva) or suprapubic pressure, then self-catheterization once a day may be all that is required (to drain excess mucus). However, to empty the bladder of urine completely 2 - 3 times a day will be the norm. How often it is done partly depends on what level of residual you are prepared to accept.

- (c) Bladder stones occur occasionally in augmented bladders secondary to mucus balls or presence of suture material. Haematuria or recurrent infections should alert the clinician to investigate for this. Stones as large as 18 cm have been reported in augmented bladders. If the bladder is kept empty, stones should be rare.
- (d) There is a very small risk in the long-term of cancer at the bowel/ urothelial junction.

CHAPTER 11

POST-OPERATIVE CARE AND COMPLICATIONS OF FISTULA REPAIR

Section 11.1: Routine post-operative care
Section 11.2: Complications and mortality in fistula surgery

(11.1) ROUTINE POST-OPERATIVE CARE

Post-operative care can be summarized by the three D's:

- (1) Drinking: Check that the patient is drinking plenty of fluids.
- (2) Draining: Check that the catheters are draining.
- (3) Dry: Check that the bed is dry.

(1) (DRINKING) FLUID INTAKE

- Give up to 3-4 litres of intravenous fluids in the first 24 hours post-operatively, as the patient is unlikely to be drinking well at this stage. Proper fluid intake will ensure a good flow of clear urine at all times and help prevent clot formation and catheter obstruction.
- Start oral fluids on the first post-operative day, or earlier if tolerated. In some units, oral fluids are tried after 4 hours although vomiting is common.

(2) (DRAINING) URINARY DRAINAGE VIA FOLEY CATHETER




Make sure the Foley catheter is above her leg (and not kinked) and is not running underneath it to avoid the weight of her leg blocking it. The Foley catheter can connect to either:

- *Closed system:* Drain into a collection bag. There is a risk that the tubing may kink or twist so make sure the bag is placed on a chair below the level of the bed. If the bag is left on the floor, it may get kinked and blocked. The bag should be at a lower level than the bladder to drain well. It is better not to tie the bag to anything (including the bed) as this may pull on the catheter when the patient turns in the bed. However, another option is to make a urine bag holder from metal wire and hang it on the bedside.
- *Open system:* The catheter can be connected to an intravenous giving/ tubing set or any plastic tubing and drain directly into a bucket or basin. Alternatively, some units use the usual urine bags but just cut the bag off and use the tubing. The advantages of this method are:
 - The flow (drop by drop) of urine can be observed by the patient, relatives and staff so blockage is easily recognized.
 - There is no danger of urine bags not being emptied and getting over-full.
- *Mixed system:* In this case, the closed system is used, but the drainage valve at the bottom of the bag is opened at night time so that the urine drains into a bucket. In this way, there should be no risk of the bag becoming over-full during the night when everybody is asleep. The patient can then close the drainage valve at bottom of the bag in the morning.

Causes of a blocked Foley catheter

Blockage of the Foley catheter can occur secondary to: (a) Blood: haematuria is more persistent following abdominal surgery than vaginal procedures. (b) Crystals/ debris even if the urine appears clear. This is much more likely if the urine is concentrated. (c) Purulent (infected) urine. (d) Twisting or kinking of catheter. To prevent blockage, instruct the patient to drink 4 litres per day to keep the urine output at 2-3 litres/ day.


- If most of the urine is draining through the ureteric catheters and very little through the Foley catheter, pull the ureteric catheters back 1 cm to encourage more to drain via the Foley so that the Foley stays patent.
- If the Foley catheter falls out on the ward with the balloon deflated, it is better to reinsert a new catheter. If not readily available, at least test the balloon of the (old) catheter before re-inserting as it may have been pricked by a needle during the repair.

	<p>If no urine is flowing, first consider a blocked catheter.</p> <ul style="list-style-type: none"> ➤ The catheter should be irrigated with 10-20 ml of saline or distilled water. ➤ If irrigation fails to unblock a catheter, then change the catheter, preferably in the operating room in lithotomy position. <p></p> <p>The patient and her relatives should be warned to report if either of these occur:</p> <ul style="list-style-type: none"> ➤ The catheter stops draining. This is easier to see if open drainage is used. <li style="text-align: center;">or ➤ If the patient experiences suprapubic pain.
<p></p> <p>When flushing the catheter, fluid must go in and come out. This is because sometimes the catheter is blocked by a blood clot near the tip of the catheter. This can have a valve effect i.e. it lets fluid in but does not let it flow out.</p>	

Management of the ureteric catheters

The ureteric catheters (if present) are left in for various times to allow any ureteric/ meatal oedema to subside. However, tubes are also foreign bodies and increase the risk of pyelonephritis so should be removed as soon as possible. If the ureters are:

- Well away from the fistula repair: take out catheters at end of operation, if used at all.
- 1-2 cm from the fistula edge: leave catheter in for 5 days.
- < 1 cm i.e. close to fistula edge: leave catheter in for 7 days.
- Re-implanted or wrapped in or if this is the only functioning kidney: leave catheter in for 10- 14 days.

	<p>It is important not to remove the ureteric catheters too early. I know of several cases where the surgeon removed the catheters at the end of the operation only to have to take the patient back for re-operation due to anuria.</p>
---	--

- If there is no urine draining from the ureteric catheters, then they should be flushed with 1-2 ml water (injected via a needle). If the fluid will not go in, withdraw the catheter slightly in case it is against renal tissue. If no urine continues to flow through the catheter, remember that the urine often drains around the catheter rather than down it so you do not need to be too concerned.
- Because of the risk of pyelonephritis, some surgeons keep the patient on a prophylactic antibiotic while the ureteric catheters are in place e.g. oral ciprofloxacin.

CAUSES OF ANURIA

If urine is not draining from the Foley or ureteric catheters:

- *Pre-renal:* Not getting enough fluids.
- *Renal:* Renal failure is a possibility. This can be secondary to sepsis originating from the site of surgery.
- *Post-renal:*
 - (a) *Ureter:* If no urine flows post-operatively, suspect that both ureters have been obstructed.
 - (b) *Bladder:* There may be a hole in the bladder that was not repaired and urine may be leaking intra-peritoneally (this is very rare) or into the vagina (failed fistula repair).
 - (c) *Urethra:* The catheter may be blocked.
 - (d) The drainage tube might be the site of a blockage, especially if it is attached to a bag and it is kinked where the tube enters the urine bag.

Case History: A patient failed to pass urine post-operatively. The surgeon undid the repair vaginally and repaired it six months later. A better alternative, if you can catheterize both ureters, would be to re-do the repair immediately. The problem with leaving the fistula open after having done all the dissection is that it may create more scarring and tissue distortion.

Case History: A patient was noted not to be passing urine on day 2 post-operatively. The records were unclear if she had been passing urine on day 1. She was febrile. When taken back to theatre, the repair was opened up and purulent material poured out. She made a good recovery as the anuria was secondary to sepsis. The VVF was repaired about 6 months later.

Diagnosis and management of the causes of anuria

Step 1 (Post-renal):

- Flush the Foley catheter with 10 ml; this may help to dislodge blood clot. If fluid fails to go in or fluid goes in but does not come out, change the catheter.
- Make sure the tubing is not kinked.
- Reduce any pressure in the bladder by removing the vaginal pack and deflating the Foley balloon (partially or fully).
- Do ultrasound of kidneys: hydronephrosis develops within hours if there is complete obstruction.

Step 2 (Pre-renal) = Give a fluid challenge of 500 –1000 ml. Exclude shock.

Step 3 (Renal) = Give frusemide 10-20 mg IV. May also give 200 ml of 20% mannitol.

Step 4 = If anuria persists for more than 24 hours, the options are to:

- Take back to theatre and open the repair. Usually, the urine starts flowing immediately. If it does not, give frusemide or mannitol before you decide that you have done the wrong procedure!
- Re-implant both ureters abdominally if the bladder is large enough.
- Perform bilateral nephrostomies. In cases where there is no permanent obstruction, as the swelling settles she will hopefully start draining from the ureters into the bladder again. After 10-14 days, to test the nephrostomies, inject dye into the tubes and see if it comes out in the Foley catheter. You should wait for the urine to clear between testing the right and left sides. This should confirm that the ureters are open. If the ureter fails to open after several weeks, it will have to be re-implanted abdominally.

The 4 F's: Flush, Fluids, Frusemide and Free the sutures or the ureter.

Case History 1: A patient had a large VVF repair done vaginally. During the operation, both ureters were in the angles of the repair and were catheterized. On day 2, both ureteric catheters were accidentally pulled out as they had not been well secured at the end of the operation. The patient failed to pass any urine and after 24 hours, bilateral nephrostomies were performed (see Appendix 5). One of the ureters re-opened but the other needed re-implantation; this was done at 6 weeks after the initial repair was well healed.

Case History 2: A patient had a VVF repair. The right ureter was not found despite the intra-operative administration of frusemide. The left was catheterized. On day 10 when the left ureteric catheter was removed, the patient became anuric. Ultrasound showed bilateral hydronephrosis. Anuria persisted more than 24 hours despite frusemide and fluid challenge. The left ureter was re-implanted abdominally. At laparotomy, the bladder was very small, with thickened walls. The left ureter was approximately 2 cm in diameter and very oedematous. Comment: It is unusual for ureters to obstruct so late but it seems to happen occasionally. The only mistake you can make is taking the ureteric catheters out too early. The other management option here would have been to do a temporary nephrostomy as in Case History 1.



It is useful to summarize the indications for urgent intervention when the ureter(s) are obstructed. Pain alone is not an indication.

- (1) Obstruction in the presence of renal failure.
- (2) Obstruction in the presence of a unilateral kidney.
- (3) Obstruction in the presence of sepsis.

(3) (DRY) IS URINE IS LEAKING? DOES SHE HAVE AN URGE TO VOID?

Check daily that the patient's bed is dry. Most breakdowns of repair occur around day 8-9 post-operatively. If there is urine leaking, first check that the catheter is not blocked by gently flushing it with normal saline. If urine continues to leak, it is best to do a dye test to locate the problem.

If dye is leaking around the catheter (through the urethra): this may be due to:

- A weak bladder neck: This occurs more often when the ureteric catheters are in place as all the tubes keep the urethra open.
- A very contracted bladder.

There is no specific action to take. There is no point inserting a larger catheter. If you are not certain if the leak is around the catheter or not, press firmly with your finger against the urethra as this will stop any leak around the catheter.


If dye leaks through the vagina:

- (a) If it is a large leak with a hole or the catheter felt anteriorly on vaginal examination: the repair has failed and no specific action is taken.
- (b) If the leak is small with no hole felt: leave the catheter in for an extra 2-3 weeks and repeat the dye test. It is worth elevating the foot of the bed and getting the patient to lie prone as much as possible to reduce the leakage (see Fig.11.1). She should only be allowed up for the toilet. A small leak will often close with prolonged drainage as long as most of the urine is draining through the catheter.
- (c) If the dye test is negative but there is clear urine in the vagina, there is likely to be a ureteric fistula.

If a patient has the urge to void: Bladder spasms: are more common after Day 7. The patient may develop pain, urge to pass urine or sudden leakage of urine from around the catheter. Get the patient to drink plenty, exclude infection and a blocked catheter. Oxybutynin or Buscopan 10 mg tds may be given to reduce bladder spasms. As a routine for all cases, only put 5-8 ml into the balloon of the Foley catheter to reduce the risk of spasms.

! Rule of thumb: early breakdowns of VVF repairs (first 5 days) will not heal with prolonged catheter drainage but late ones (7-14 days) may.

! Tip! Always consider an unrecognized ureteric fistula especially if she starts leaking urine in the first few days post-operatively. Do an ultrasound of the kidneys to look for hydronephrosis and do a dye test which should be negative.




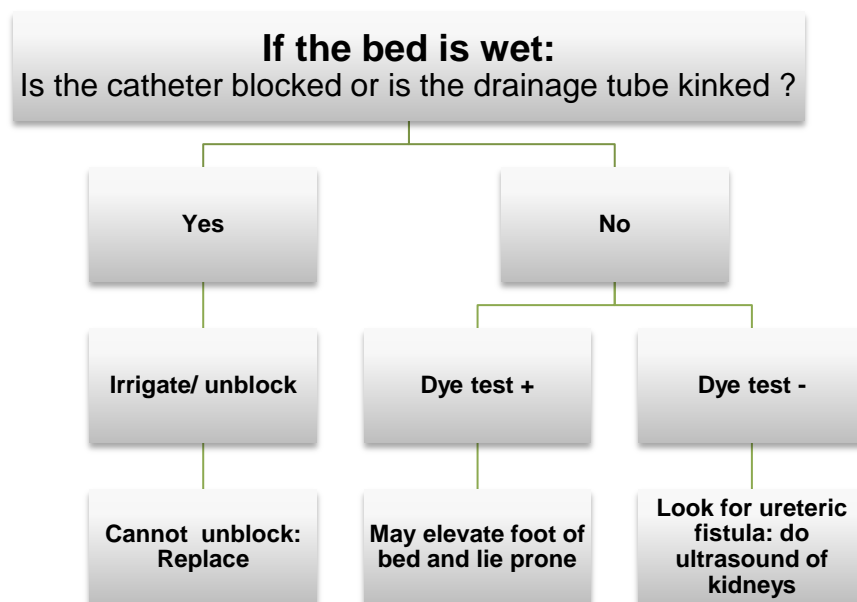
Summary: If the bed is wet, check for:

- Overflow: Is the catheter blocked or tubing kinked? Flush the catheter.
- Stress/ urge: Is she leaking around the catheter? The patient may only be wet on standing.
- Fistula: Is the repair broken down? Is there a ureteric fistula? In the event that a fistula fails to heal, it is usually best to wait at least 6 weeks before attempting repair again. If the fistula is small, mid-vaginal and not very lateral, some would attempt repair after 3 weeks.


! Tip! If the bed is wet, provided you are sure that the catheter is not blocked or kinked, immediate action is not required.

Fig. 11.1: In cases where there is leaking of urine with a positive dye test but no defect is felt, then it is worth elevating the foot of the bed as shown and getting the patient to lie prone as much as possible to reduce the leakage. If the patient is compliant, this is often successful.

 **Tip!** If she is leaking with the catheter in situ, the fistula is not likely to heal. If she only starts leaking after removing the catheter (or she is dry but has a positive dye test before you plan to remove the catheter), an extra 2-3 weeks of drainage may allow the fistula to heal.



Flow chart for managing a patient who starts to leak urine post-operatively.

	Do not be tempted to re-operate on a patient for leaking in the first 48 hours. This has been advocated in the past but the results are not good. You will only make the problem worse.
---	---

(4) GENERAL AND VAGINAL CARE

- **Pack:** The vaginal pack can be removed after 24-48 hours.
- **Care:** The external perineal area should be cleaned twice daily while the Foley catheter is in situ.
- **Vaginal discharge:** If the patient is having a vaginal discharge post-repair with no fever: this can be due to either the sutures dissolving or a small area of necrosis on the suture line. In most cases, the only treatment needed is to do sitz baths. Antibiotics are usually not indicated. With a copious discharge, consider the possibility of:
 - Retained swab in the vagina or a swab left in between the bladder and vagina.
 - If a flap has been placed, it may be flap necrosis. In addition to excising the necrotic area, irrigate the vagina twice daily with saline.
- **Odour alone:** If there is a mild odour from the vagina, in the absence of pyrexia or obvious breakdown of the wound, this usually indicates a hygiene problem. Clean the vulva and instruct the patient to have sitz baths.
- **Bed rest/ mobilization:** There are no fixed rules about this. Whatever the patient's activity, it is important not to have any pull on the catheter. Early mobilization reduces chest infections, venous thrombosis and ileus. Even if the open drainage method is used, the patient can walk around with the tubing draining into a bucket.

(5) REMOVAL OF URETERIC CATHETERS

When removing the ureteric catheters, it is a good idea to remove them one at a time. If after removing one, there is no urine coming through the Foley during the next 24 hours, then do not remove the second one as this would indicate that there is an obstruction on the side the catheter was removed. If you remove both at the same time, there is a possibility that both could obstruct.

Case History: A small, 1.5 by 2 cm juxta- cervical VVF with slight scarring was repaired with two ureteric catheters inserted during the operation and kept in post-operatively. The dye test after the procedure was negative. The patient was dry and both ureteric catheters were producing urine. After a week, the ureteric

catheters were due for removal. One came out easily but the other one was stuck. Over a few days, several attempts to pull it out failed. Then one time it was pulled on so hard that it broke. X-ray confirmed that the ureteric catheter was still partially in-situ. The patient started leaking and on inspection, there was a 1 cm defect in the repair now. Through that gap, the remaining broken ureteric catheter was removed. The patient had another VVF repair after 3 months.

Lessons: 1. Be very careful putting your stitches when closing the bladder not to catch the ureteric catheters. 2. Pulling hard on the ureteric catheter rips open the repair. Just wait till the ureteric catheter eventually comes out easily or falls out by itself.

Case History: A patient had a VVF repair. The left ureteric catheter never drained post-operatively. She presented on Day 10 with pain and a mass on the left side. At laparotomy, it was found that the left ureter had been perforated by the ureteric catheter. After drainage of the fluid, the left ureter was re-implanted into the bladder. Lesson: Never use force when inserting a ureteric catheter.

(6) REMOVAL OF THE FOLEY CATHETER

The purpose of the catheter after a repair is to allow the bladder to heal while empty and decompressed so that there is no tension on the repair site. The catheter is kept in until there is sufficient wound healing at the repair site which depends on a number of factors: (a) The size and complexity of the repair (b) Whether it is a first or repeat repair (c) The repair technique and skill of the surgeon (d) Patient factors which may affect healing such as diabetes or HIV.

Browning (unpublished data) found that most of his repair breakdowns occurred between day 7 and 9 so it would seem sensible to keep a catheter in for at least this duration.

The ideal duration of bladder catheterization in post-fistula repair patients is unknown. Although widely used in practice, the traditional 14 – 21 days duration of catheterization after fistula repair has been challenged more recently.

Nardos showed that the outcome of postoperative catheterization for 10 days was not inferior to that for 14 days. However, this randomized trial excluded repeat repairs and circumferential defects. All cases were performed or supervised by an experienced fistula surgeon.

Reference: Nardos R, Menber B, Browning A. Outcome of obstetric fistula repair after 10-day versus 14-day Foley catheterization. Int J Gynaecol Obstet. 2012;118:21-3.

Barone in another randomized trial showed that seven days of bladder catheterization was not inferior to 14 days. The problem with this trial is that it only included simple fistulas and even then no clear definition of a simple fistula was given but would usually mean mid-vaginal, not much scarring, not involving the urethra and < 3 cm size.

Reference: Barone, MA, Widmer, M, Arrowsmith, S et al. Breakdown of simple female genital fistula repair after 7 day versus 14 day postoperative bladder catheterisation: a randomised, controlled, open-label, non-inferiority trial. Lancet Vol 386 No 9988 pages 56-62 July 2015.

Fistula surgeons need more evidence to be able to reduce the duration of postoperative bladder drainage without the anxiety about increased repair breakdowns. This is partly based on the experience of seeing fistulas which initially have a positive dye test at the time of intended catheter removal that go on to heal with an extra 2-4 weeks of catheterization.

In developed countries, there is a great pressure to minimize the length of stay in hospital and there is usually an excellent back up health system so that readmission can be undertaken quickly and without difficulty. In developing countries the pressures are different. It is extremely difficult for patients to be readmitted or to come back for another operation in the future. The journey home itself is a hazard as it can be many hours without the ability to void. Therefore, a more conservative approach is better to ensure a healed wound will stay healed. My advice would be if there is any concern, it is usually better to maintain catheter drainage a little longer rather than to remove it too early. So 14 days should stay the norm but may be reduced in very simple fistulas or where the surgeon is experienced. The following are some of the less conservative practices in use:

- If bladder fistula and first repair = 10- 12 days.
- If bladder fistula and repeat repair = 12- 14 days.
- Following repair of surgical / iatrogenic fistulas = 12 days.

Before you remove: Do a dye test immediately before removing the catheter. If positive, keep the catheter in for up to 6 weeks. Repeat the dye test every 2 weeks until negative.



Top Tip! An important rule is that if the patient is dry with the catheter in, the fistula will heal.



- You must warn the patient that if she fails to pass urine within two hours of removal of the catheter, she must report to the medical staff. Otherwise, a full bladder can put the repair under tension and this can lead to breakdown of the repaired fistula.
- 1-2 hourly voiding initially should be encouraged. It may also be necessary to wake up patients once or twice during the night for the same reason.
- Check the residual urine volume at the end of the day the catheter is removed (see below).

If the balloon of the Foley catheter will not deflate: This is not an uncommon situation depending on the quality of the catheters used. There are several options:

- (i) You can burst the balloon by inserting a needle through the vagina/ bladder which is easy to do if you apply a little traction on the catheter to steady it. However, there is a risk that the balloon will not only burst but break up, leaving fragments in the bladder and risk of stone formation. So you must check that the balloon is complete on removal.
- (ii) Cut the catheter proximal to where the urine and balloon channels meet. Sometimes this alone allows the fluid in the balloon to drain. If not, inject 1-2 ml of halothane or ether into the balloon channel close to the urethra. You have to draw the halothane up in a syringe and inject it quickly as it can start dissolving the syringe. Wait a few minutes for it to dissolve the balloon before you start pulling on the catheter.

If the Foley catheter has been caught by a suture, it is best to leave it in place and wait for the suture to dissolve. The balloon is deflated and often the catheter falls out. If not, each week gently pull in order to see if the catheter will come out. However, if you pull hard, you may tear the repair open.

Post-operative care after procedures for stress incontinence:

It is simpler to leave in the Foley catheter for seven days as there is a high risk of retention when removed earlier. Retention of urine is the main problem of which to be aware. Often the patient develops overflow which may only present as leaking. Therefore it is important to check residual urine volumes as a routine.

(7) URINARY RETENTION POST CATHETER REMOVAL

Some patients (estimated to be about 10%) develop urinary retention when the catheter is removed after fistula repair. With retention of urine, some will not pass any urine, some will pass small amounts frequently (overflow) and others are completely wet. It is not always obvious so a high index of suspicion is required.

Diagnosis: After any repair or operation for stress incontinence, the patient should have at least one measurement of residual urine volume. This is best done at the end of the day that the catheter is removed and repeated the following day. A residual of < 50% of the voided volume e.g. if patient voids 100 ml and the residual is < 50 ml, is acceptable. If the residual is high:

- Put the catheter back in for another week. If after one week it is still high, teach the patient intermittent self-catheterization after each void (Fig. 11.2).
- Another option is to do what is known as bladder re-training. The Foley catheter is left on free drainage for two days. It is then clamped and released every two hours and left on free drainage over night. Do this for two days and remove the Foley and re-check residual volume. In one unit 70% of patients are voiding normally after this time. However, there is a danger in clamping urethral catheters unless you are 100% confident in nursing staff – otherwise 2 hours becomes 4, 6, 8 hours, and you rapidly end up with an over-distended hypotonic bladder (and long-term voiding problems).
- Another option is to try conservative steps without catheterizing like double voiding and suprapubic pressure. Double voiding means emptying the bladder twice, usually 15 seconds after the first void. Residual volumes with these steps should also be checked.
- Do intermittent self-catheterization (see Fig. 11.2). Once the voided to residual ratio reaches 2:1 or the residual is less than 150 ml, the patient can stop doing intermittent catheterization. If she is going home and may not be able to return for follow-up, tell her to keep doing it until there is little or no urine coming out when she introduces the catheter.

- *With non-atonic bladders* i.e. sensation of fullness and obstructed voiding, she will probably need to do self-catheterization 3- 5 times a day. Some patients get wet with a few hundred mls of urine probably because obstruction makes the bladder unstable.
- *With atonic bladders* i.e. no sensation of fullness and overflow when the bladder gets up to about one litre, she will only need to self-catheterization 1-2 / day. This will empty one litre of urine and the bladder then takes many hours to refill to this volume. Doing self-catheterization once a day is enough to protect the kidneys from bladder pressure. Many atonic bladders never recover. If there is recovery then she will have return of sensation and begin to void but before you stop self- catheterization you need to be sure the residuals are not above 500 ml which still has a risk of damaging the kidneys.




Intermittent self-catheterization

- The patient is best taught while sitting on a bed or the floor. No vulval swabbing is necessary. A combination of using a mirror and self-palpation is used. The right-hand stretches the labia apart while the left-hand inserts the catheter.
- She should wash her hands before the procedure.
- After use, the catheter is cleaned by washing with water.
- The procedure should be performed as frequently as necessary to keep the bladder volumes below 500 mL.

Fig. 11.2: Shows the position for self-catheterization. A mirror (orange frame) is used as shown so the patient can see her urethral opening.

(8) DISCHARGE HOME

- It is a good idea to keep the patient in hospital for a minimum of two days after removal of catheter for two reasons:
 - Infection: The risk of urinary tract infections is high especially after removal of the catheter.
 - If the patient is leaking or in case of retention, the best chance of cure is if the catheter is re-inserted in the first month.
- The patient is advised:
 - Not to have coitus for three months. It is also advised to avoid heavy lifting for three months.
 - She should be advised on family planning.

	<p>Make sure the patient empties her bladder regularly on the trip home. Patients often try to hold on for eight hours or more in a bus, then feel a pop and they start leaking! It is safer to give a supply of diapers for the journey home to avoid this problem.</p>
---	--

(11.2) COMPLICATIONS AND MORTALITY IN FISTULA SURGERY

Before any operation, check: (a) Indication (b) Which operation (c) Fitness of the patient: Avoid booking a patient who is not fully fit just because there is a slot on the list the next day.

(1) HAEMORRHAGE

Exclude bleeding disorders if any of these occur. Check the platelet count and look for splenomegaly (hypersplenism).

- *Primary (in the first 24 hours post- operatively) vaginal:* Never manage this problem on the ward; always take the patient back to the operating room. Either suture the bleeding point or re-pack with a pack soaked

in adrenaline (1 ampoule of 1 in 1000 diluted in 200 ml saline). Suturing the pack in place with 2-3 sutures in the labia majora is a useful tip. Also, elevate the foot of the bed when back on the ward.

- **Secondary (after 24 hours and before 6 weeks) vaginal:** This is less common and may be due to infection or unrecognized slow primary haemorrhage. After resuscitation, take the patient back to the theatre. Look for any arterial bleeders, which are seldom found. So in most cases just insert a pack with adrenaline into the vagina for 24 hours. Elevate the foot of the bed when back on the ward. Rarely haemostatic agents such as Floseal, Surgicel or even balloon tamponade may be required.
- **Primary bladder:** This is uncommon. The initial treatment is to flush the bladder until the urine is clear and this may avoid having to reopen the bladder. If clot retention develops, you may have to take the repair down to find the bleeding point.

Case History A patient developed severe pain a few hours post-repair. The catheter was found to be blocked and when it was changed, 300 ml of blood came out. The patient was taken back to the operating room and the repair reopened. A bleeder was found and the bladder was closed again.

- **Secondary bladder:** This is also uncommon. The first step is to put in a large bore Foley (preferably 20-24 F unless contraindicated by urethral reconstruction). This decreases the risk of clot retention. Then using a bladder syringe, push in 60 ml saline and forcibly pull it back out. Use one syringe-full at a time. This only works when a big Foley is in place. Continuous bladder irrigation has to be used with great caution in the post-operative care of fistula patients because if there is more fluid going in than coming out, it will blow the repair.

Case History: A patient had a VVF repair performed vaginally. On day 2 post-operatively she developed haematuria with clots. The bladder was irrigated with a syringe/ saline 1- 2 times daily. This was continued 1- 2 times daily. As the haematuria persisted, on day 6, the patient was taken for suprapubic cystostomy (extra- peritoneal approach). There was a small bleeder to the right of the ureteral orifice which was ligated. The bladder incision was closed and a suprapubic catheter was inserted. Continuous bladder irrigation was performed for two days with saline solution 1 litre 8 hourly. The patient had no more problems post-operatively and the fistula healed well.

(2) TRAUMA TO SURROUNDING STRUCTURES DURING REPAIR

- Trauma occurs most commonly to the ureters. The ureters are particularly at risk with repeat repairs as it can be difficult to visualise the ureters through a small scarred fistula. Most ureteric injuries go unnoticed and symptoms like pain and vomiting are unreliable indicators although when they occur, you should at least investigate with an ultrasound of the kidneys.
- Rectal injuries occur occasionally when cutting scar in the vagina.
- Haematometra and secondary infertility may occur if the cervix is closed over.

(3) FAILURE OF REPAIR

Failure may occur of the repair with the result that the patient may now be inoperable. If an RVF fails, leakage of stool may lead to sepsis.

(4) HYPONATREMIA

This has been reported with a large intake of water. The patient may present with confusion. Hypertonic saline and frusemide are used in the treatment. To avoid this complication, patients should not be encouraged to take more than 4 litres per day.

(5) SEPSIS

Despite the use of prophylactic antibiotics, in the only large study of post-operative mortality associated with repair of genital fistulas, nearly half of all deaths were related to sepsis. Sepsis is also the commonest cause of morbidity in the post-operative period. The site of sepsis is most often in the genital or urinary tract. *Reference: Mortality risk associated with surgical treatment of female genital fistula. Ruminjo J et al: IJGO 126 (2014) 140-145.*

- In genital tract infection, pyrexia and a bad vaginal odour are the more obvious signs. The diagnosis is confirmed as pus is released when the vaginal incision is opened. Always exclude a retained swab in the bladder or in the vagina as a cause of sepsis.
- Urinary tract infections are seen much more commonly than genital tract infections and are the commonest cause of severe sepsis. High fluid intake reduces the risk of pyelonephritis.

- Infections often go unrecognised until it is too late. In addition to fever, look for tachycardia, tachypnea, hypotension and altered mental state.
- Temperature should be recorded at least daily in all post-operative patients. In febrile patients, after excluding malaria, start antibiotics and consider if intravenous fluids are needed.

SEPTIC SHOCK/ RENAL FAILURE

Shock is treated with a combination of crystalloid fluids ± vasopressors.

Fluids: If the systolic blood pressure is < 90 mmHg give :

- Initial fluid bolus (30 ml/ kg) unless there is convincing evidence of significant pulmonary edema e.g. give 3 liters administered in the first three hours.
- Subsequent fluid therapy should be administered in well-defined (e.g. 500 ml), rapidly infused boluses. The clinical and hemodynamic response and the presence or absence of pulmonary edema must be assessed before and after each bolus.
- Patients with septic shock often require a total of 4-6 litres or more of crystalloid solution.


Vasopressors: For patients who remain hypotensive despite adequate fluid resuscitation (eg, 3L in first three hours), vasopressors should be given. A simple regime is to add one ampoule of adrenaline (1 mg or 1 ml of 1:1000) to 500 ml of crystalloid. This is then run at a rate to keep the systolic blood pressure over 90 mm Hg. If hypertension develops, the rate is reduced. In hypotensive patients, the pulse usually reduces with adrenaline as the blood pressure rises so do not be worried about giving it just because there is already tachycardia.

- If haemoglobin levels fall below 7 g/ dL, red blood cell (RBC) transfusion is recommended to a target haemoglobin range of 7-9 g/ dL.
- Supplemental oxygen should be administered to all patients with suspected sepsis

Oliguria/ Renal failure: (a) Pre-renal: fluid challenges as above. (b) Post-renal: Do ultrasound of bladder and kidneys to exclude this. (c) Renal: If still oliguric after fluid challenge, give 200 ml of 20% mannitol. Also frusemide 40 mg hourly provided the systolic blood pressure is > 90 mmHg.

CONCLUSIONS

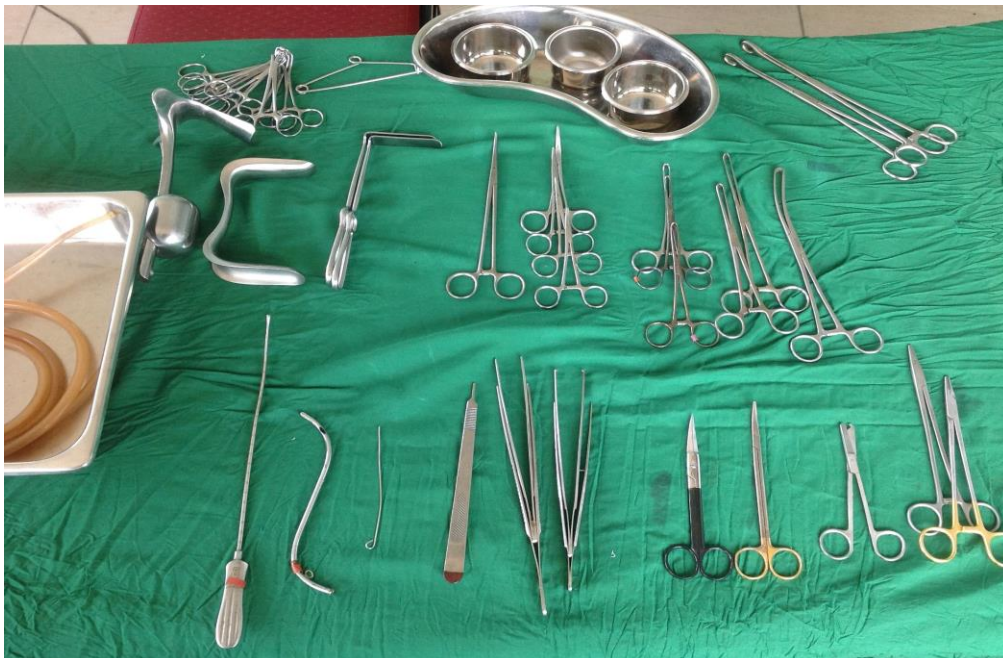- Many of the post- operative problems can be prevented by taking time during the surgery to avoid injury to the ureters, ensuring good haemostasis and giving adequate antibiotic prophylaxis.
- Encouraging a high fluid intake post-operatively also helps to avoid many problems especially blockage of the catheters and urinary infections.
- As problems may still occur post- operatively, routine observations are important to identify problems early. Sepsis remains the biggest killer in the post-operative period.

	<p>Mortality following fistula surgery is generally low. However, it is higher in:</p> <p>(a) Patients who have been sick postpartum and lost a lot of weight. Delay any surgery until she has regained her normal body weight.</p> <p>(b) Patients who need a second operation soon after the first. It is usually the second mistake in response to the first mistake that kills the patient. Therefore consider the following: While haemorrhage or sepsis need urgent surgery, in other conditions alternatives to surgery (e.g. nephrostomy for obstructed ureters) may be better. Also, consider more expert anaesthesia or surgical help.</p> <p>(c) Older patients who often have unrecognised medical problems. While there is no fixed upper age limit for fistula surgery, remember little old ladies can be big trouble!</p> <p>Before any operation, ask yourself: (a) What is the indication? (b) What is the correct operation (c) Is the patient fit for surgery?</p>
<p>KEY STEPS TO AVOID COMPLICATIONS IN FISTULA SURGERY</p> <ul style="list-style-type: none"> • <i>Haemorrhage:</i> have blood available especially for complicated cases. Optimise haemoglobin pre-operatively. Use diluted adrenaline infiltration. Do staged VVF + RVF repairs. • <i>Infection:</i> make sure antibiotic prophylaxis is given. Ensure good fluid intake post-operatively. • <i>Trauma:</i> the ureters are always closer than you think. Know where they are at all times. 	

APPENDIX 1

EQUIPMENT FOR FISTULA REPAIR

ESSENTIAL SPECIALIST EQUIPMENT FOR FISTULA REPAIRS	
<i>Table</i>	Table with steep head down tilt (Trendelenburg) of 45 degrees and where the foot end of the table can be removed as otherwise it will be very difficult for the surgeon to sit for any duration. <ul style="list-style-type: none"> • If the foot end of the table is fixed and cannot be removed, check if you can turn the table around 180 degrees so that the head becomes the foot. • If there is not adequate head-down tilt, you can place bricks or step under the end of the bed. Tables of good quality are made by Fazzini, Nuova.
<i>Shoulder pads</i>	These allow steep head down tilt without the patient slipping down the table (Fig.1.3c).
<i>Light source</i>	<ul style="list-style-type: none"> • A bright light source e.g. Evolution LED lights, Astramax • A headlight is useful, as the table position will be changing during the surgery.
<i>Suction</i>	This is important to avoid using a lot of gauze for swabbing.
<i>Ureteric catheters</i>	Size 4, 5 and 6 F. If not available, infant feeding tubes can be used but are more difficult to keep in place.
<i>Sutures needles</i> The main sutures for repairs:	<p>Strong needle/ suture: for taking the lateral bites of para-urethral tissue including periosteum. A 5/8 circle 26 or 27 mm needle (available as UR6 Vicryl 2/0 J602H or Polysorb UL-878 or Novosyn 2/0 FR26).</p> <p>Fine needle/ suture: when taking the central bites of the urethra: A half circle 26 mm needle Vicryl 2/0 taper (VCP or J 417).</p> <p>Very fine needle/ suture e.g. work on a fragile urethra or ureter:</p> <ul style="list-style-type: none"> • 3/0 22 mm needle (Polysorb GL-182) or Novosyn HR22 or Vicryl 3/0 J305 3/0 or • Vicryl 2/0 VCP306 on a 17 mm 1/2c needle. <p>Special: A J shaped 22 mm needle (Vicryl W9223) is useful when working in confined spaces as it is easier to turn the needle e.g. when the fistula angle is very lateral.</p> <p>Vagina: any large needle e.g. 36 mm Vicryl J375H or Polysorb 40 mm CL-803.</p>
<i>Cautery</i>	Cautery (Bovie) is very useful especially for higher/ cervical fistulae.



Fistula repair set:

Upper row: towel clips, kidney dish with gallipot, sponge forceps.

Middle row: weighted speculum, Sims, Retractors, long and short artery forceps, long and short Allis forceps, vulsellum.

Lower row: Uterine sound, metal catheter, probe, dissecting forceps/ pickups, scissors, needle holders. On left, tray with suction tubing. Thorek scissors which are useful in fistula surgery are not shown in this set.

LIST OF INSTRUMENTS FOR FISTULA REPAIR SET	
Speculum + Retractors	<ul style="list-style-type: none"> • <i>Auward weighted speculum</i> with an acute angle which allows it to sit nicely in the vagina. There are two sizes: (a) The larger one (Aesculap® EL 739R) is suitable for most cases. (b) A smaller one with a shorter and narrower blade (Aesculap® EL 736R) is suitable for small or scarred vaginas and is particularly useful to have. • <i>Sims speculum</i>: is useful for a shorter vagina. • <i>Deaver retractors</i>: <ul style="list-style-type: none"> ○ Small curved 8 ½ inch (Aesculap® BT601R) is very useful to help in retracting the bladder during large fistula repairs. ○ Large retractors are useful in high fistulas especially in obese patients. ○ Langenbeck retractor, 13 x 44 mm blade x 2
Scissors	<ul style="list-style-type: none"> • Dissecting scissors, curved: Sharp ones are ideal e.g. Stille-Matarasso are particularly good for cutting scar tissue. The Stille tonsillar dissecting scissors are finer and sharp. • Suture scissors, straight, 18 cm • Thorek scissors
Needle holder	<ul style="list-style-type: none"> • Mayo-Hegar, 20.5 cm x 1 • Mayo-Hegar, 18 cm x 1
Dissecting forceps	<ul style="list-style-type: none"> • Dissecting forceps, with teeth, 20 cm x 1 • Dissecting forceps, fine serrated jaw, 20 cm x 1
Single items	<ul style="list-style-type: none"> • Blade holder 7, Swann Morton, 159 mm x 1 • Probe with eye, malleable, 20 cm x 1 • Uterine sound, malleable, 30 cm x 1 • Metal catheter, 16 cm x 1 • Kidney dish, large, 34 cm and gallipots x 2
Allis forceps	<ul style="list-style-type: none"> • Allis forceps, 20 cm x 2 • Allis forceps, 15 cm x 2
Artery forceps	<ul style="list-style-type: none"> • Large artery forceps, 23 cm x 1 • Mosquito's, curved, 13 cm x 4
Large forceps	<ul style="list-style-type: none"> • Sponge holding forceps, 241 mm x 2 • Vulsellum forceps, curved, 229 mm x 1
Miscellaneous	<ul style="list-style-type: none"> • Towel clips, Backhaus, 89 mm x 4 • Towel clips, Backhaus, 127 mm x 6 • Safety Pin forceps holder, 114 mm x 2
Special blades	Either size 11 or 15 are useful for incising in the vagina.

CHECK LIST OF ITEMS TO USE FOR FISTULA REPAIRS	
	Ureteric catheters
	Foley catheters sizes 12F 14F 16F
	Syringes: catheter tipped 60-100 ml
	Dye e.g. gentian violet paint or methylene blue
	Surgical blades: size 11 or 15
	Special sutures
	Probes: to help catheterize ureters
	Prophylactic antibiotics
	Spinal anaesthesia e.g. Heavy Bupivacaine
	Post-operative instruction sheet (Appendix 3) and post-operative charts (Appendix 4).
	Strapping of good quality
	The 3 essential instruments: Good scissors, needle holder and toothed dissecting forceps (pickups).

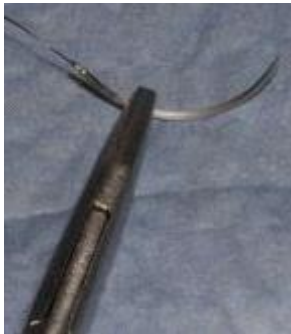APPENDIX 2

GENERAL SURGICAL TIPS FOR FISTULA SURGERY

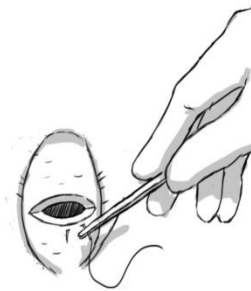- (1) **SPECIAL GRIPS OF NEEDLE:** There are two grips commonly used in fistula surgery which are not often used in general surgery. In both of these:
- The surgeon's hand and elbow are held up so that the handle of the needle holder is on top. To do this, you have to hold your right elbow (and hand) **up and out** (laterally) in the air as seen in Figure E.
 - Do not put your fingers or thumb through the needle holder but grasp it with the palm of your hand (pen-like grip). This allows for more mobility and rotation which you will need.

Backhand grip: This grip is used especially when stitching on the left side of the patient i.e. when going from patient's left to right (see Figure A and B).

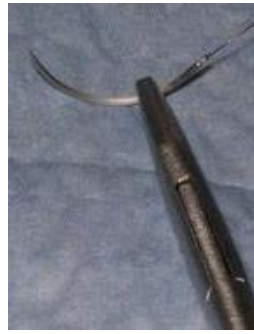Reverse forehand grip: If you want to stitch going from the patient's right to left. This is mainly used on the right side (see Figure C and D)



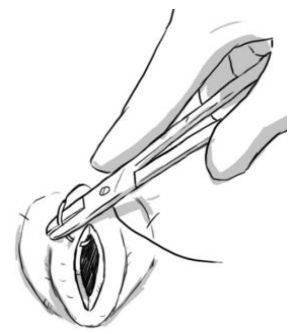
A: Mount the needle so the point is facing to your right (when holding mid-prone)



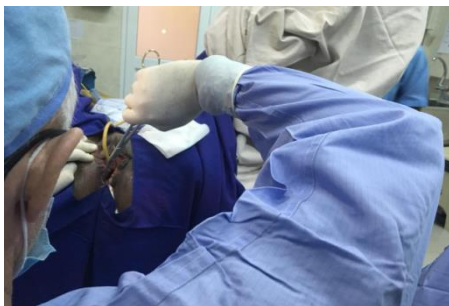B: Shows the backhand grip being used. The needle-holder is held like a pen.



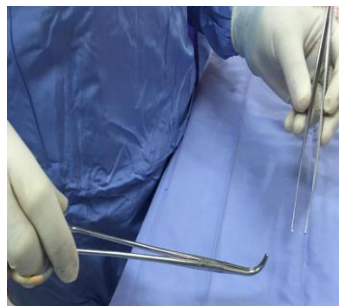C: Mount the needle in the usual way so the point is facing to your left.



D: Shows the reverse forehand grip with needle-holder held on top.



E: For both the backhand and reverse forehand grip, keep your right elbow up and out as you hold the needle-holder like a pen.



F: Shows the right-angled forceps held in the right hand and dissecting forceps held in the left hand.

(2) DISSECTION

Dissection during abdominal VVFs or ureteric fistula repair is often best achieved by using:

- (a) A right-angled forceps in your right hand to dissect out the tissues to be cut.
- (b) Dissecting forceps/pickups in your left. By displaying the tissues between the tips of the right-angled forceps, your assistant can then cut them for you with either scissors or cautery.

(3) IF YOU WANT TO KEEP A KNOT TIGHT and you are tying by instrument, use a combination of:

- Put a double throw on the first loop and tighten by moving right hand under left towards the left so that it is square.
- Once the first loop is tied, rotate the two ends 180 degrees to lock them by moving the right hand back under the left hand towards the right.
- Then to further keep the first throw tight as you tie the second, your assistant holds one end tightly (the short end without the needle) by pulling it with artery forceps. At the same time, you hold the long end (with the needle) tight with your hand. Now tie the second throw.

If hand tying knots: Do not hold instruments especially in critical situations as it is difficult to judge tension and control the knot if you do. Always push the knot down with your index finger, and only use an instrument as an extension of the suture.

If the knot has become loose (air-knot): Instead of re-doing all the suturing, take another bite (usually proximally) and tie again. Inspect the knot carefully to make sure it is now tight.

APPENDIX 3

PRE AND POST OPERATIVE PROTOCOLS FOR VVF CARE

Pre-operative investigations before fistula repair (Important ones in bold.)

Haemoglobin level and blood group.	HIV test
<i>Routine pregnancy test:</i> History of menses and sexual activity can be misleading.	<i>Malaria:</i> Blood film or Rapid Diagnostic Test.
<i>Blood sugar:</i> Diabetic patients have an increased risk of breakdown of the repair. This is not a routine test but should be considered in repeat repairs.	<i>Renal function:</i> If available, serum creatinine and urea levels are useful especially if there is hydronephrosis but not available in most centres.
<p>Ultrasound of both kidneys to look for hydronephrosis or renal atrophy.</p> <ul style="list-style-type: none"> • <i>VVF:</i> This can be very useful if you cannot find one of the ureters during the surgery. • <i>Ureteric fistula:</i> Hydronephrosis often accompanies ureteric fistula which occasionally may be present along with a vesico-vaginal fistula (VVF). The urine leaking from the VVF makes the ureteric fistula difficult to diagnose until after the VVF is closed. A significant number of postsurgical VVFs have an associated ureteric injury. 	
<p><i>Urine:</i> Routine urine culture or microscopy is not necessary as results are misleading due to contamination. Because urine drains continuously, VVF patients rarely get urinary tract infections pre-operatively unless there is a stone present. However, in endemic areas, it is worth screening for schistosomiasis and if positive, the urine should be rechecked after treatment before any surgery.</p>	

Pre-operation Day routine

- Full blood count
- Nil by mouth after midnight.

Operation Day: Routine before operation

- Start intravenous fluids at least 1 hour before surgery: Ringer's Lactate or Normal saline.
- Prophylactic antibiotics according to hospital protocol.

Operation Day Post-operative routine (After return from Operating room):

- *In Recovery room:* Check blood pressure and pulse every 15 minutes for 1 hour. If stable then, transfer to ward.
- *On the ward:* Check blood pressure and pulse ½ hourly x 2 hours, then hourly x 4 hours, then every 4 hours.
- *Intravenous fluids:* Either Normal Saline or Ringer's Lactate 100 ml/ h. Continue until the morning of Day 1. May take oral fluids after 6 hours if tolerated.
- *Catheter care:* The catheter or tubing must not be twisted and the patient must not be lying on it. Make sure the catheter is above and not under her leg. Empty the urine bags every 2 hours and monitor urine output 2 hourly. See box below if urine not draining.
- Check for vaginal bleeding. If bleeding, check vitals: blood pressure, pulse, respiratory rate, oxygen saturation and inform the surgeon.

Post-operative Day 1 Routine and later

- Oral fluids of 3 litres/ day and normal diet. If drinking well, remove intravenous fluids.
- Remove the vaginal pack and clean the external perineal area 1- 2 times/ day while the Foley catheter is in place.
- Check the 3 D's as in box. Empty urine bags 4 hourly on day 1 and 2. From day 3 the patient can empty the bag herself when it is half-full but show to the nurse first.
- Observations: 4 hourly on Day 1 then 8 hourly from day 2 if stable.



Tip! If you suspect a blocked catheter, raise the drainage tube above the level of the patient's abdomen and check for free flow. If there is free return of urine to the bladder, catheter blockage is unlikely.

All Post-Operative Days: Check the 3 D's:

Drainage: If no urine draining through the catheters at any time or the patient has suprapubic pain:

- Check the Foley catheter and tubing for twists or kinks, which can block urine flow.
- Flush Foley catheter with 10 ml saline three times and withdraw the fluid after each flush. The fluid must go in and come back out. If you cannot flush the catheter or you cannot withdraw the fluid, the doctor should change the catheter preferably in lithotomy position in theatre.
- After flushing, connect the urine bag and observe the flow. Inform the doctor if still no urine or just blood.
- If there are visible clots with flushing then keep flushing until no clots are visible. Call doctor if clots persist.
- If ureteric catheters are draining well but little or no urine in the Foley, just flush the Foley with 10 ml.
- If no output in ureterics but good output in Foley, just flush the ureterics with 2 ml and observe.
- If no output in ureteric catheters and little or no output in Foley, inform the doctor.

Dry: If urine is leaking at any time, check that the Foley catheter is not blocked by flushing it. If it is not blocked, then just observe the patient.

Drinking well to prevent blockage of the catheter: The colour of the urine should be clear like water.

If bleeding vaginally anytime: If doctor is not available immediately: Place a tight pack in vagina. Put up intravenous fluids (Normal Saline). Elevate foot of bed. Monitor vital signs and inform the doctor.

If fever after day 1: > 38 degrees C or > 100 degrees F: Exclude malaria. Check for urinary infection.

The day the catheter is due out (according to post-operative instructions): Do a dye test.

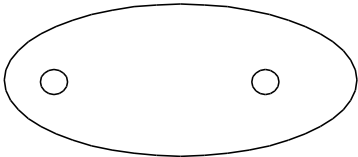
- If healed and dye test negative, remove catheter.
- If dye test positive, leave catheter in for 2- 4 more weeks and repeat the dye test before removal.

PAD TEST PROTOCOL

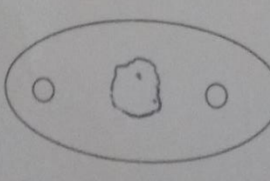
This is a way of objectively measuring how wet or dry the patient is after VVF repair or any operation for stress incontinence. It is best done 2-3 days after catheter removal as some leakage is common soon after the catheter is removed. You need a nurse, a pad and a kitchen weighing scale. It is often easier to do several patients at the same time.

- Provide the patient with a pad that is weighed before she puts it on. Also weigh the container (e.g. examination glove) to be used to put the pad into.
- Ask the patient to drink 500 ml water within a short period (no longer than 15 minutes), then sit or rest for a few minutes.
- She should walk around and void when she feels the urge (whilst taking caution not to wet the pad when voiding).
- After an hour ask her to come back to the nurse who weighs the pad again and records the change of weight. Weight gain in grams = urine loss in ml. An increase of:
 - 1 to 10g represents mild incontinence
 - 11 to 50 g represents moderate incontinence
 - > 50 g represents severe incontinence.
- NOTE: If the patient feels that her pad is soaked, she should come back to the nurse who will replace it with a new pad and place the old pad in an air-tight container.
- NOTE: If the patient needs to void, she should come back to the nurse. If she cannot make it back before voiding, tell her to remove the pad before she voids and bring the pad back to the nurse after her void.

APPENDIX 4
POSTOP CHARTS

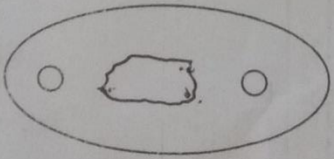
NAME: OPERATION		DATE OF						
Day 0	DAY 1	DAY 2	DAY 3	DAY 4	DAY 5	DAY 6	DAY 7	
 Operation summary:	Temp = Pack out: Signed -----	Temp =	Temp =	Temp =	Temp =	Temp =	Temp =	
Temp =	DAY 8	DAY 9	DAY 10	DAY 11	DAY 12	DAY 13	DAY 14	
Temp =	Temp =	Temp =	Temp =	Temp =	Temp =	Temp =	Temp =	
Temp =	DAY 15	DAY 16	DAY 17	DAY 18	DAY 19	DAY 20	DAY 21	
Temp =	Temp =	Temp =	Temp =	Temp =	Temp =	Temp =	Temp =	

The days the ureteric catheters are to be removed and the dye test is due (before removal of Foley catheter) are written in at the end of the operation. The 3 Ds are written in each day.

NAME		DATE OF OPERATION																					
Day 0 2nd attempt  Operation summary: Midvaginal + P.C.S. Pery		DAY 1 7/3	DAY 2 8/3	DAY 3 9/3	DAY 4 10/3	DAY 5 11/3	DAY 6 12/3	DAY 7 13/3	DAY 8 14/3	DAY 9 15/3	DAY 10 16/3	DAY 11 17/3	DAY 12 18/3	DAY 13 19/3	DAY 14 20/3	DAY 15 21/3	DAY 16 22/3	DAY 17 23/3	DAY 18 24/3	DAY 19 25/3	DAY 20 26/3	DAY 21 27/3	
Temp = 36.06 Pack out: bloody and wet. Signed <i>Heilla</i>		Temp = 36.09 DDD	Temp = 36.20 DDD Rook -	Temp = 36.50 DDD	Temp = 36.50 DDD	Temp = 36.50 DDD	Temp = 36.50 DDD	Temp = 36.50 DDD	Temp = 36.50 DDD	Temp = 36.50 DDD	Temp = 36.50 DDD	Temp = 36.50 DDD	Temp = 36.50 DDD	Temp = 36.50 DDD	Temp = 36.50 DDD	Temp = 36.50 DDD	Temp = 36.50 DDD	Temp = 36.50 DDD	Temp = 36.50 DDD	Temp = 36.50 DDD	Temp = 36.50 DDD	Temp = 36.50 DDD	Temp = 36.50 DDD
(1) The days the ureterics are to be removed and the dye test is due before removal of Foley catheter are written in when the patient comes from the operating theatre. The 319g are written in the 319g.		Temp = 35.30 DDD	Temp = 36.08 DDD DYE (+) Keep prone	Temp = 36.00 Wet DD	Temp = 35.07 DDD wet DD	Temp = 35.05 DDD wet DD	Temp = 35.05 DDD wet DD	Temp = 35.05 DDD wet DD	Temp = 35.05 DDD wet DD	Temp = 35.05 DDD wet DD	Temp = 35.05 DDD wet DD	Temp = 35.05 DDD wet DD	Temp = 35.05 DDD wet DD	Temp = 35.05 DDD wet DD	Temp = 35.05 DDD wet DD	Temp = 35.05 DDD wet DD	Temp = 35.05 DDD wet DD	Temp = 35.05 DDD wet DD	Temp = 35.05 DDD wet DD	Temp = 35.05 DDD wet DD	Temp = 35.05 DDD wet DD	Temp = 35.05 DDD wet DD	
260g 360g DDD		Temp = 35.09 DDD	Temp = 36.02 DDD	Temp = 36.18 DDD	Temp = 35.05 DDD	Temp = 35.05 DDD	Temp = 35.05 DDD	Temp = 35.05 DDD	Temp = 35.05 DDD	Temp = 35.05 DDD	Temp = 35.05 DDD	Temp = 35.05 DDD	Temp = 35.05 DDD	Temp = 35.05 DDD	Temp = 35.05 DDD	Temp = 35.05 DDD	Temp = 35.05 DDD	Temp = 35.05 DDD	Temp = 35.05 DDD	Temp = 35.05 DDD	Temp = 35.05 DDD	Temp = 35.05 DDD	

In this case, the patient was dry with catheter in. She had a positive dye test on day 16. She was encouraged to lie prone and the catheter was kept until day 29 and her dye test was now negative.

NAME: [redacted] DATE OF OPERATION: [redacted]

DAY	DATE	Temp	Notes
DAY 0			 <p>Operation summary: 1st repair Soft + Bleed</p>
DAY 1	14/12	36°C	Pack out: today Signed when no bleeding Bullantia
DAY 2	15/12	35.3	DDD
DAY 3	16/12	36.1	DDD
DAY 4	17/12	36.3	DDD
DAY 5	18/12	36.1	DDD
DAY 6	19/12	35.0	DDD
DAY 7	20/12	36.3	DDD
DAY 8	21/12	36.0	DDD
DAY 9	22/12	36.0	DDD
DAY 10	23/12	36.5	Uterine Stent @ out today by N
DAY 11	24/12	35.7	DDD Stent @ out
DAY 12	25/12	36.6	DDD
DAY 13	26/12	36.8	DDD DYE = neg V-1x2 L-200ml V=0 L-200ml V=0 R. 100ml
DAY 14	27/12	35.3	DDD
DAY 15	28/12	36.1	Dry
DAY 16	29/12	35.8	Dry V=200x4 SC=200ml V=0 SC=300ml V=0 SC=250ml
DAY 17	30/12	36.3	Dry V=300x3 R=200 V=0 SC=300 V=175 R=200
DAY 18	31/12	36.1	Dry catheter Residuals V=100 SC=200 V=200 R=200 V=200 R=200
DAY 19	01/01	36.6	Dry V=200 R=150 V=100 R=150 V=100 R=150
DAY 20	02/01	36.6	Dry
DAY 21	03/01		Temp =

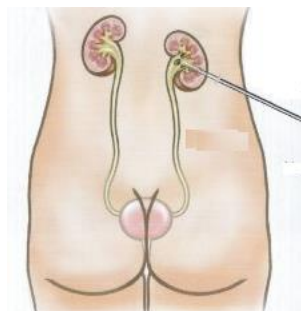
In this case of a mid-vaginal fistula, the Foley catheter was removed on day 14 after a negative dye test. The voided volumes (V) and the residual volumes (R or SC) are recorded on the sheet. When the residual volume was checked the first evening, it was found to be high and the patient was taught to do intermittent catheterization.

APPENDIX 5

NEPHROSTOMY

(A) NEPHROSTOMY

If obstruction to the ureter(s) develops post-operatively (and was not present pre-operatively), nephrostomy can be a useful procedure to know. Ideally, a nephrostomy set is used e.g. Amecath size 8 or 10 F. If not available, a central venous line can be used instead. Smaller-bore catheters (7-8F) are sufficient for drainage of non-infected urine, while a larger-bore (14F) catheter may be considered for drainage of infected urine or pus.



Position: The patient is placed in the prone position. The posterior approach avoids the surrounding organs.

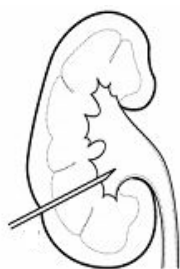Site: about 2 cm below the 12th rib and two finger breadths lateral to the lateral margin of the paraspinous muscles which is approximately the posterior axillary line. Using ultrasound, you can pick the exact site you want to go in i.e. towards a posterior lower-pole calyx.

Anaesthesia: Infiltrate with local anaesthesia at the puncture site.

(1) **Incision:** With a scalpel (no. 11 blade), make a small stab incision through the skin. An artery forceps is then used to dilate the opening in the skin, fascia and muscle superficially.

(2) **Pass needle:** The needle is angled towards the intended calyx usually 45-90 degrees to the horizontal.

Either:



(a) (Using no ultrasound) Pass the needle (21-22 F) with a syringe attached. Aspirate as you insert and stop once urine is obtained.

(b) (Under ultrasound guidance) The needle is inserted below and parallel to the ultrasound probe. Often you can see the movement of the tissues produced by the needle rather than the needle itself. You should see the needle enter the calyces. Once the needle is inserted into the collecting system, the stylet is removed, and urine comes back. If no urine comes, a 10-ml syringe should be attached to the needle hub, and the needle and syringe should be retracted slightly. If urine is aspirated, the tip is probably within the collecting system.

(3) **Insert the guide-wire** through the needle until it is well inside the renal pelvis or down the ureter.

(4) **Remove the needle:** While holding the guide-wire, pull the needle out by grasping the needle at the skin so the depth of the collecting system can then be gauged i.e. measure the depth of the needle e.g. 7 cm. In the remaining steps, this 7 cm depth will be used as the depth recorded.

(5) **Dilators:** Over this guide wire, pass a series of dilators to a depth of where the needle entered i.e. 7 cm. The track is best dilated with a motion that is 80% twist and 20% push.

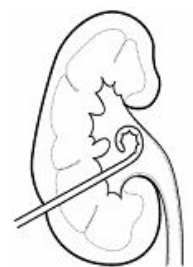(6) **Prepare the catheter:** Prior to introduction, the nephrostomy catheter should be uncoiled. If it is a pig-tail variety this is done by inserting a stylet in the catheter.

(7) **The nephrostomy catheter** is introduced over the guide wire. The catheter with the stylet is introduced to a depth of 7 cm. The stylet is then withdrawn 1-2 cm while the catheter is pushed in 1-2 cm. The catheter can be safely pushed in without injuring the ureter as it will coil up.

(8) Check the flow of urine. You may have to pull back the catheter a bit.

(9) Once the catheter is properly positioned, the wire guide should be removed.

(10) The catheter is tied to the skin with suture and attached to a drainage bag. One of the problems with nephrostomy is preventing it falling out. In addition to sutures, tape the tube to the skin over a roll of gauze at the exit site. The tube is bent over the roll which prevents kinking. The sutures will fall out eventually so you may want to re-stitch it under local anaesthesia every 14 days.



Complications

- Heavy bleeding down the nephrostomy means you have traumatized a parenchymal artery or vein. To stop it, cap the nephrostomy for an hour and then uncap. It usually drains blood stained urine which clears. You may need to flush with 20 ml saline.
- Infection. Give a prophylactic dose of gentamycin or coamoxyclav at the time of insertion.
- Damage to bowel. This is very rare and will only declare some days later with pain, sepsis and spreading tenderness, and may need open exploration.

Nephrostomy care

- Never pull on the tube as it will come out and make sure the tube is not kinked
- Get her to drink plenty to maintain a high dilute urine output
- Drainage bag: Do not let it get heavy as this will displace the tube so empty every 2-3 hours
- If drainage stops it may be blocked with debris or have pulled out of the kidney. Flush with 20 ml saline. Try and withdraw fluid but even if it was blocked and is now unblocked, fluid may not withdraw. In this case, wait and see. If it drains, it was blocked. If it does not drain, it is probably displaced. If you have facilities you can go to X-ray department and inject dye down to confirm. If it is out of the kidney then remove the tube. There is a tiny risk of internal urine leakage. If the nephrostomy needs replacement, wait until the next day for the kidney to dilate and become a good target.

How do you know the nephrostomy is no longer needed and the obstruction has resolved?

- Ideally, do a nephrostogram i.e. inject dye down the tube in X-ray and check the dye enters the bladder. Do not remove straight away – clamp the nephrostomy overnight to ensure it really is draining and remove the next day.
- If you do not have X-ray: Either: (a) Inject blue dye down the nephrostomy. If there is no obstruction then the dye will be seen in the Foley catheter bag (b) Do a trial clamping.

Removing the nephrostomy: Simply cut the stitch and pull. Apply a dressing. Usually there is no leakage.

(B) IS THE KIDNEY STILL FUNCTIONING?

This is a question that arises occasionally in fistula surgery.

- Irreparable damage to the kidney occurs after six weeks of obstruction.
- A pre-operative ultrasound, showing cortical tissue present, suggests that there is still some function present.
- During an abdominal operation if you find one of the ureters is very dilated, try to pass a ureteric catheter. If it does not pass, then the ureter is probably completely occluded or very stenosed and will have no/ very little function. Give a dose of frusemide to see whether there is any urine produced.
- The general advice would be to reimplant an obstructed ureter in cases where there is still some function. If there is no function, it is probably safer to leave it alone although some advise reimplantation in cases of doubt.
- If there is recurrent pyelonephritis and a poorly functioning kidney, it is better to remove the kidney.

Case History: During a VVF repair, the left ureter was explored abdominally and only a small amount of pus drained from it. It was decided to ligate it at the lower end. Post-operatively, the patient developed a pyonephrosis and required an emergency nephrectomy.

Lesson: Re-implantation is done mainly for drainage and in case there is still function. It is not advised to tie off the ureter as this can result in severe sepsis. The only other safe option would be to do a nephrectomy.

(C) NEPHRECTOMY

This is sometimes required as an emergency procedure in fistula surgery. Nephrectomy should preferably be reserved for a non-functioning or poorly functioning kidney.

- *Position:* Patient is supine. Place a roll (e.g. size of a full two litre bag) under the flank to push the kidney into the field.
- *Incision:* Make a midline incision from the xiphoid to the umbilicus. The alternative is to make a subcostal incision starting in the midline. On the right side, use a Deaver retractor to keep the liver up out of way. Cut the peritoneum lateral to the colon with scissors or cautery. Pull the colon medially. On the right side identify the duodenum which overlies the hilum and mobilize it medially.
- *Ureter:* Find the ureter at a convenient level and place a tape around it. It is safer not to cut the ureter until you know you are going to be able to remove the kidney. Slide your hand up the ureter while pulling on the tape. This will lead you towards the hilum i.e. by following the ureter with your finger and thumb, you will approach the hilum from below.

- *Kidney*: Dissect out the anterior, posterior and apical kidney. The key is to stay on the renal cortex as you dissect with your hands and use cautery if necessary. By staying on the cortex, this leaves the adrenal gland (golden fat like appearance) behind, so there is less risk of bleeding.
- *Hilum*: Now lift the kidney up, which gives you more control over the hilum. Come down from above (medial upper kidney) as you come up the ureter from below, and the hilum is what is left. Squeeze the hilum between your finger and thumb. This will tend to get rid of fatty tissue so that you are only left with the vessels.
- *Vessels*: Separate the vessels out using a scissor to tease the tissues apart. Ligate the vessels as you come across them i.e. do whichever one is easier first. The artery is behind the vein on both sides.
- *Ligating*: Place two ties on the medial side and one on the lateral side. Then pass the right-angled clamp under the vessel and cut with a knife onto the clamp. It is a good idea to now transfix the medial side with another suture as ties alone may slip off.

Note: On the left side the kidney has a longer vein into which both adrenal and gonadal vessels enter. Thus venous control is therefore easier and safer on the left. The renal vein on the right is shorter and can tear more easily.

(D) SUPRAPUBIC CATHETER

If you want to insert a suprapubic catheter anytime in a female where it is difficult to fill the bladder, insert a uterine sound or artery forceps into the urethra. Then go just above the pubic bone and make a stab incision over the sound/ artery and pull in a Foley catheter.

(E) NELATON CATHETERS



These are an alternative to using a Foley catheter. The main advantage is that they are less likely to get blocked as the urine channel occupies the full diameter with no balloon channel.

Also, plastic catheters are less likely to kink. They are particularly useful if:

- The urethra is being reconstructed and it is only possible to insert a smaller size catheter e.g. 12 or 14F.
- In cases where the bladder is very small and it is difficult to inflate the balloon of the Foley.
- Some surgeons use them routinely because of the low risk of blockage.

The catheter has to be secured with a suture inserted just above the urethral meatus. To further secure the catheter, after tying the suture around the catheter, the suture ends are left long and wrapped in tape around the catheter. There is a risk of the catheter falling out as the stitch pulls through which is more likely after 7-14 days so this is a potential problem if you want them in for longer.

APPENDIX 6

BLADDER AUGMENTATION

POST- OPERATIVE ADVICE SHEET GIVEN TO PATIENTS WHO HAVE HAD BLADDER AUGMENTATION

Name: _____ is a patient of Fistula Centre. The operation that we performed on her was a Bladder Augmentation in order to enlarge the bladder volume.

For this procedure, a part of the small bowel is opened and attached to the bladder.

The operation was performed on _____ (date)

What to expect:

- Because the bowel is now part of the bladder, mucus is still produced in a varying amount. Therefore, the urine can have a slimy or infected appearance, which should not worry the patient.
- In order to empty the bladder properly, most patients have to perform intermittent self-catheterisation.

Possible problems:

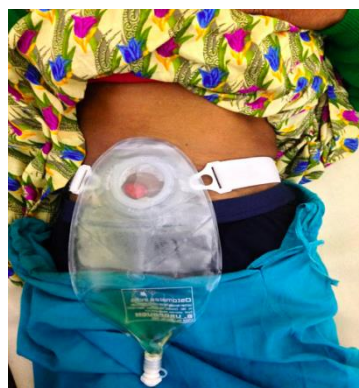- The sensation for bladder filling is reduced, therefore patients are advised to empty the bladder at least three to four times a day, even if they have no desire to void. If patients do not follow this instruction, there is a high risk of over distension, which sometimes makes it very difficult to self-catheterise.
- The same can happen if mucus leads to obstruction or stone-formation in the bladder.

What to do:

These situations can be an emergency case because this bladder is in danger of rupture!!!!
So whenever a patient with abdominal symptoms after bladder augmentation comes to your office, please insert an 18 or 20 F Foley catheter (or whatever size is available), empty the bladder and if possible irrigate the bladder with saline by using a big syringe and aspirating the mucus. Then send the patient back to us.

Adapted from instruction sheet Fistula Hospital Addis Ababa.

COUNSELLING CHECK-LIST FOR A PATIENT BEFORE CONSIDERING ILEAL CONDUIT



- A diversionary procedure is the only way to get her dry.
- The urine stoma will be for life, it cannot be reversed again.
- It is a big operation, but patients usually recover within 2 weeks.
- The operation risks include bleeding, infection, urine leak - which will need extra treatment.
- The risks for living with an ileal conduit are kidney infection, ureteric stenosis which might need re-operation, problems with the stoma.
- Need to come and get stoma bags for the rest of her life.
- Need to come for annual check of creatinine and kidney scan.
- Need to contact hospital if any problem related to ileal Conduit.

Adapted from LAMB Hospital, Bangladesh.

APPENDIX 7 OPERATION REPORT SHEET

Patient + Number

Date:

Surgeon: _____

Assistant: _____

Scrub Nurse _____

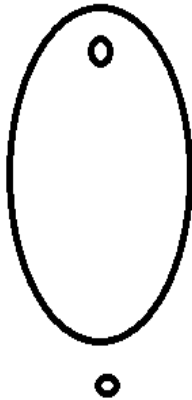
Anaesthetist: _____

Operative diagnosis: VVF RVF ureteric fistula Stress 4th degree tear

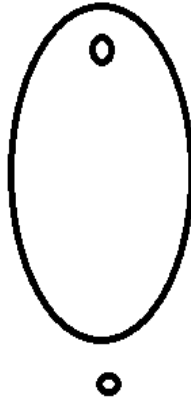
Procedure performed:

Repair Attempt: First Second Third Fourth Fifth Sixth Seventh

Before repair



Repair



Distance from urethral meatus

- > 3 cm
- 2.5-3.0 cm
- 1.5-<2.5cm
- <1.5 cm

Length of urethra _____ cm

Fibrosis:

- None
- Mild with normal vaginal capacity
- Moderate or severe with reduced capacity

Relaxing incision (Episiotomy): No Yes

Ureteric catheters

Intra-op: R _____ L _____

Post-op: R _____ L _____

Bladder: Number of layers ____

Suture type and gauge _____

Fistula Width _____ **Length** _____

Dye Test + bladder capacity: _____ (ml)

? **Circumferential** ¾ 4/4 not dissected 4/4 dissected

Intermediate layer: No Yes

Type: Pubo-cervical Pubococcygeus

Other _____

Classification: _____

Complexity of repair:

Low Medium Low Medium high High

Vagina: Suture type and gauge _____

Complications:

Flap? No Singapore Labial Other

Estimated Blood loss: _____ (ml)

Surgeon's Signature: _____

Vaginal Pack: Yes No

APPENDIX 8

URETHRAL PLUGS

Urethral plugs have been available although production is now stopped so their future use is uncertain.


There are three sizes available: (a) No 1 is equivalent to 12 F (b) No 2 is equivalent to 14 F (c) No 3 is equivalent to 16 F and should be second line if she leaks around the smaller plugs.

Plugs often work best in the first six months of use although many patients use them happily long term. The problem is that the urethra tends to dilate when anything is inserted, so a patient using a small plug will soon need a bigger one. *Reference: Use of urethral plugs for urinary incontinence following fistula repair: Goh JT, Browning A. Aust N Z J Obstet Gynaecol. 2005 Jun; 45(3):237-8.*

- The firm introducer is used for inserting and removing the plug.
- The plug is removed when the patient wants to void and then reinserted.
- Plugs should only be used for a maximum of 12 hours per day so only use them during the day or at night, but not both. They should be rinsed after use.
- The plug may also help her bladder expand if she has a small bladder capacity.
- Usually, one plug will last at least one month before it becomes too weak and needs to be replaced.
- There is an increased risk of infection if proper hand hygiene and plug care is not done.

Plugs are helpful in a majority of women with urethral incontinence. In one of the few studies on the use of plugs from a total of 181 patients studied: 18 women (75.7 %) reported being dry, 18 women (9.9 %) half dry (improved), 26 women (14.4 %) remained wet, 17 of whom had a new or wide urethra. In addition, 101 women (55.8 %) had a bladder size < 7.5 cm and these were more likely to be wet.

Reference: The use of urethral plugs for the management of persistent urinary incontinence following successful repair; Brook, G., Tessema, A.B. International Urogynecology Journal and Pelvic Floor Dysfunction (2013) 24 (3), pp. 479-484.



Shows a urethral plug.

If she is leaking around the plug:

- She could have a small bladder that fills up very quickly and she leaks; or she can be dry for about an hour and then she starts to get wet, with or without bladder sensation.
- The urethra could be gaping so the plug does not fit well. Increase the size from 2 to 3. If this fails, then there is no point using the plug.

If the handle of the plug breaks or the whole plug migrates into the bladder: you can either try to grab it blindly with a forceps or remove it during cystoscopy or cystotomy.

! Tip! The most important factor in the acceptance and successful use of the plug is an education and training program. This requires a dedicated member of your staff who has the ability to assist the patient with the placement of the plug. The staff should place the plug and have the patient stand and cough or bounce to demonstrate its efficacy. Next, have your staff coach the patient in placing and removing the plug on her own enough times so she feels confident in utilizing the plug. A hand mirror may be helpful in allowing the patient to identify her urethra (see Fig. 11.2).

INDEX

- Abdominal repair**
- VVF 75-84
 - RVF 110-14
- Adrenaline 12
- Anal sphincter injuries 115-121
- Bladder**
- Augmentation 148-150
 - Prolapse 4
 - Stones 57
- Boari flap 138
- Case selection 9
- Catheter treatment 7
- Circumferential fistulas
- VVF 40-3
 - RVF 108,111-3
- Classification of obstetric fistulas 6-7
- Colostomy for RVF 101
- Colpocleisis 64
- Complications of fistula surgery 158-9
- Diagnosis of VVF 1-4
- Double VVF 58
- Dye test 3, 28-29
- Early cases + repair 7-8
- Ectopic ureter 3, 140
- Failed repair and re-operation 154,159
- Goh classification 6
- Gracilis muscle graft 130-3, 107
- Iatrogenic fistulas 5
- Incontinence post-repair 85-97
- Inoperable cases 141
- Intra-cervical fistulas 49-52
- Juxta-cervical fistulas 14,16
- Juxta-urethral fistulas 35-43
- Labial flap 127
- Large fistulas 43-47
- Lateral fistulas 61-63
- Legs closure 46-47
- Mainz II pouch 142-8
- Martius flap 129-30
- Mid-vaginal fistulas 6,14
- Nephrectomy 168-9
- Nephrostomy 167-8
- Overflow incontinence 1,2, 85,98, 157-8
- Pad test 165
- Pelvic floor exercises 1, 85,89
- Pinhole fistulas 48, 59
- Post-operative care 151-60
- Pregnancy and VVF 9
- Psoas hitch 137
- Pubo-cervical fascia repair 30, 90-92
- Pubo-coccygeal
- patch 61
 - sling 30-31
- Radiotherapy, fistulas following 63-64
- Rectus fascia sling 92-95
- Rectus muscle flap 80-81
- Recto-vaginal fistula 100-120
- Recurrent pinhole VVF 59-61
- Re-implanting ureter
- vaginally 55-57, 140
 - Abdominally 134-9
- Singapore flap 122-6
- Singapore sling 95, 126
- Stress incontinence
- Reducing the incidence intra-op 32-33
 - Management of 85-97
- Suprapubic catheter 79, 169
- Ureter
- Ectopic 3, 140
 - outside the bladder 55-57
- Ureteric catheters 16-18, 152, 155-6
- Ureteric fistulas 1-2, 134-40
- Urethral fistula 38
- Urethral plug 172
- Urethral reconstruction 65-73
- Urethral stricture 97-99
- Urgency incontinence 1-2, 85, 88-89
- Urinary diversion 141-8
- Urinary retention 1, 2, 85, 157-8
- Vaginal closure 31-32, 122
- Vaginal skin defects 122
- Vaginal stenosis 127-8
- Vault fistulas 52-55
- Vesico-uterine fistulas 49-52
- Waldijk classification 7